




## Case Report

# Ocular ischemic syndrome due to severe internal carotid artery stenosis improved by intracranial stent placement: A case report

Wataru Uchida, Tomoya Kamide, Takehiro Uno, Akifumi Yoshikawa, Kouichi Misaki, Mitsutoshi Nakada

Department of Neurosurgery, Kanazawa University, Kanazawa, Ishikawa, Japan.

E-mail: Wataru Uchida - wuchida.1tym@gmail.com; \*Tomoya Kamide - kamide@med.kanazawa-u.ac.jp; Takehiro Uno - t.uno@med.kanazawa-u.ac.jp; Akifumi Yoshikawa - yoshikawa@med.kanazawa-u.ac.jp; Kouichi Misaki - misaki@med.kanazawa-u.ac.jp; Mitsutoshi Nakada - mnakada@med.kanazawa-u.ac.jp



### \*Corresponding author:

Tomoya Kamide,  
Department of Neurosurgery,  
Kanazawa University,  
Kanazawa, Ishikawa, Japan.

[kamide@med.kanazawa-u.ac.jp](mailto:kamide@med.kanazawa-u.ac.jp)

Received : 12 April 2021

Accepted : 28 May 2021

Published : 21 June 2021

### DOI

10.25259/SNI\_361\_2021

### Quick Response Code:



## ABSTRACT

**Background:** Treatment of cervical internal carotid artery (ICA) stenosis has contributed to the improvement of ocular ischemic syndrome. However, there have been few cases of visual impairment caused by ocular ischemic syndrome due to intracranial ICA stenosis, which improved through intracranial stent placement.

**Case Description:** A 76-year-old man presented with right-sided paralysis. Radiographic examination revealed severe stenosis of the left intracranial ICA (distal cavernous-intraclinoid portion) and a watershed infarction of the left cerebral hemisphere. Conservative therapy including antiplatelet drugs was initiated, but severe visual acuity disturbance in his left eye occurred 1 month after onset. The antegrade ocular artery flow recovered after urgent intracranial stent placement, and his vision improved immediately after the procedure.

**Conclusion:** Visual impairment presenting as ocular ischemic syndrome can occur due to severe stenosis of the intracranial ICA, and treatment of these lesions could improve the symptoms.

**Keywords:** Internal carotid artery stenosis, Intracranial, Ocular ischemic syndrome, Stent placement

## INTRODUCTION

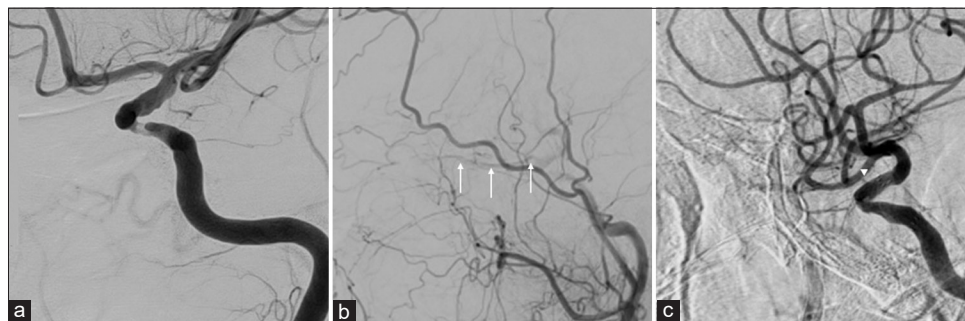
Ocular ischemic syndrome, including visual impairment, amaurosis fugax, and pain, occurs secondary to severe atherosclerotic carotid artery stenosis, resulting in 50% reduction in ipsilateral perfusion pressure.<sup>[8]</sup> Treatment of cervical internal carotid artery (ICA) stenosis, such as carotid artery stenting (CAS) and carotid endarterectomy (CEA), has contributed to the improvement of ocular ischemic syndrome. Here, we describe a case of an ocular ischemic syndrome due to intracranial ICA stenosis which improved with intracranial stent placement.

## CASE REPORT

A 76-year-old man presented with right-sided paralysis. Cerebral magnetic resonance imaging revealed a watershed infarction in the left hemisphere, and cerebral angiography revealed severe stenosis of the left intracranial ICA (distal cavernous-intraclinoid portion), without stenosis of the cervical ICA [Figures 1 and 2a]. Collateral flow through anterior communicating artery was absent,

This is an open-access article distributed under the terms of the Creative Commons Attribution-Non Commercial-Share Alike 4.0 License, which allows others to remix, tweak, and build upon the work non-commercially, as long as the author is credited and the new creations are licensed under the identical terms.

©2021 Published by Scientific Scholar on behalf of Surgical Neurology International



**Figure 1:** Cerebral angiography of the left internal carotid artery (ICA) demonstrating severe stenosis of the left ICA at the distal cavernous-infraclinoid portion. The ocular artery was not confirmed (a). Cerebral angiography of the left common carotid artery before stent placement demonstrating the ocular artery (arrows) was depicted by a collateral blood flow from the external carotid system (b). Cerebral angiography of the left ICA after stent placement demonstrating the ocular artery (arrowhead) was depicted by a directed blood flow from the ICA (c).

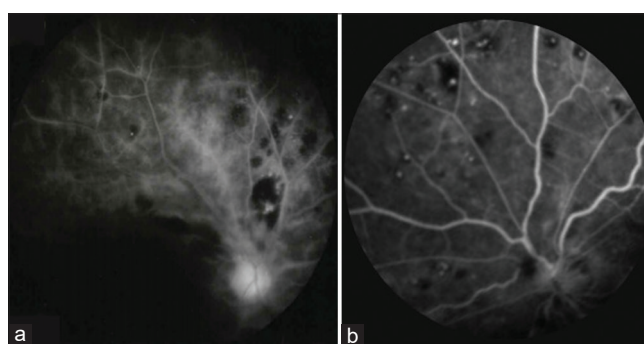
but through posterior communicating artery was confirmed insufficiently. Single-photon emission computed tomography (SPECT) demonstrated that his left cerebral hemisphere reserve was reduced. He immediately started conservative treatment with antiplatelet drugs and rehabilitation, and extracranial-intracranial bypass was planned within 3 months after the ictus. However, he presented with severe visual acuity disturbance in the left eye 1 month after onset, and ophthalmic evaluation revealed a central retinal artery obstruction in the left eye, and the ocular circulation time evaluated by arm retinal circulation time (A-R time) was prolonged.

Decreased blood flow to the ocular artery due to stenosis progression of the left ICA was suspected. Urgent cerebral angiography performed 2 days after the occurrence of visual impairment demonstrated that the left ICA was almost completely occluded, and the ocular artery was confirmed through anastomosis from the external carotid artery [Figure 1b]. Percutaneous angioplasty (PTA) was performed to improve visual acuity. The ICA flow improved immediately after PTA but decreased thereafter. After several attempts at PTA, an intracranial stent (Wingspan, Stryker Neurovascular, Salt Lake City, Utah, USA) was placed to maintain the improved flow of the ICA [Figure 1c]. After stent placement, the antegrade ocular artery flow recovered, and his vision improved immediately.

The A-R time was reduced from 54 s to 11 s, and retinal angiography also showed improvement in the visualization of blood vessels [Figure 2a and b]. In addition, SPECT showed improvement in the left cerebral blood flow reserve [Figure 3a-f], and he was discharged 2 weeks later without deficits. During the 1-year follow-up, his visual acuity and ICA flow remained stable.

## DISCUSSION

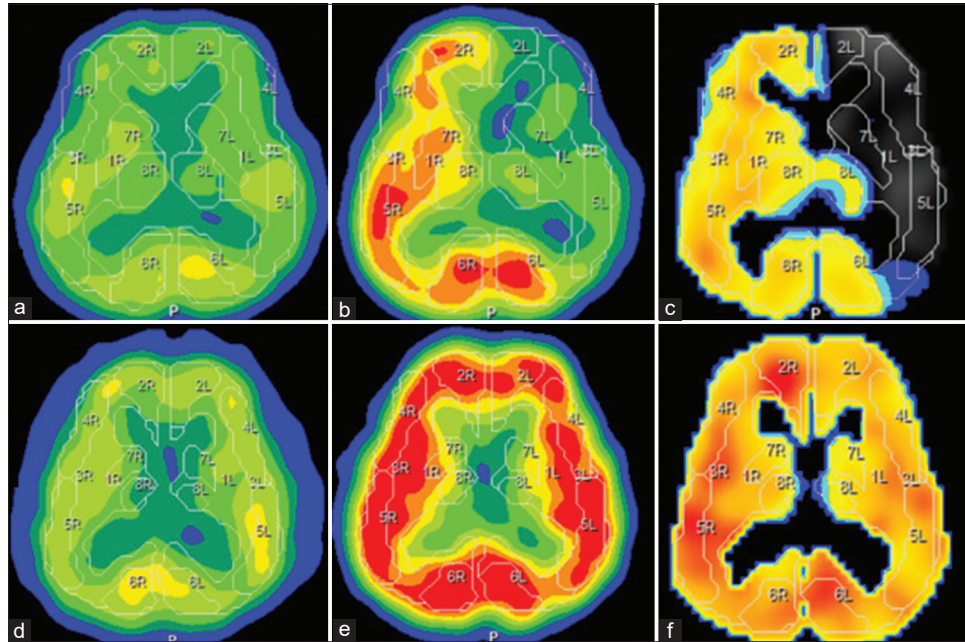
Ocular ischemic syndrome is caused by ocular hypoperfusion due to stenosis or occlusion of the cervical ICA.<sup>[1]</sup> There have



**Figure 2:** Preoperative (a) and postoperative (b) fluorescent fundus angiography demonstrating the visualization of the retinal artery which improved markedly after the treatment.

been cases of improvement in the blood flow to the retina and ocular ischemic syndrome, such as CAS and CEA, after the treatment of the cervical ICA stenosis. The positive effect of CAS and CEA on the compromised ophthalmic artery flow in patients with ocular ischemic syndrome is well established.<sup>[6]</sup> Regarding intracranial ICA stenosis, Marx *et al.* reported three cases of percutaneous transluminal angioplasty and stenting (PTAS) for ocular ischemic syndrome due to the intracranial ICA stenosis, but those were precavernous and proximal cavernous portions of the ICA.<sup>[8]</sup> Therefore, there have been no cases of ocular ischemic syndrome due to stenosis of the distal cavernous-infraclinoid portion of the ICA. In the present case, the antegrade ocular artery flow recovered and his vision improved immediately after treatment. It is reasonable to speculate that improvement in blood flow in the ICA contributes to the increased blood flow in the ocular artery, irrespective of whether it is cervical or intracranial ICA.

To evaluate ocular blood flow and retinal circulation, the A-R time measured by fluorescein fluorescence fundus examination was used in this case. In patients with severe cervical ICA stenosis, the A-R time was prolonged and was improved after CAS at a high rate.<sup>[2,4]</sup> In the present case,



**Figure 3:** Preoperative single-photon emission computed tomography (SPECT) demonstrated that his left cerebral hemisphere reserve was reduced (a-c). Postoperative SPECT showed improvement in the left cerebral blood flow reserve (e-g). (a and d) Cerebral blood flow (CBF) at rest; (b and e) CBF after acetazolamide challenge (Diamox CBF); (c and f) cerebral vascular reserve defined as (Diamox CBF-resting CBF)/resting CBF×100%).

the A-R time significantly improved after intracranial stent placement. We speculate that A-R time might be strongly associated with intracranial carotid artery stenosis and is predictive of ocular ischemic syndrome.

Complications related to PTA have been reported: cerebral embolism, vessel dissection, hemodynamic compromise, and cerebral hyperperfusion syndrome. Regarding visual acuity, angioplasty of the ICA could increase ocular blood flow, but intraocular pressure elevation due to increased aqueous humor might result in decreased visual acuity.<sup>[10]</sup> Several reports of glaucoma deterioration after CAS and CEA have been published.<sup>[5,9]</sup> Although the visual acuity of the patient improved after the treatment in this case, ocular complications might occur with a similar condition in the intracranial carotid artery stenosis.

The Stenting and Aggressive Medical Management for Preventing Recurrent Stroke in Intracranial Stenosis trial supports the use of aggressive medical management rather than PTAS with the Wingspan system in patients with intracranial arterial stenosis.<sup>[3]</sup> Although there have been cases of intracranial ICA stenosis that improved transient memory impairment and hemiparesis, there is no case in literature elucidating improvement in visual impairment due to ocular ischemic syndrome after PTAS treatment for the distal cavernous-intraclinoid portion of the ICA.<sup>[7,8,11]</sup> In this case, we provided the best medical treatment; however, severe visual acuity disturbance developed, and PTAS was successfully performed with improvement in the ocular

symptoms. PTAS could be an option for salvage therapy for ocular ischemic syndrome due to intracranial ICA stenosis.

## CONCLUSION

The improvement in blood flow in the ICA contributes to an increased blood flow in the ocular artery irrespective of whether it is cervical or intracranial ICA in patients with ocular ischemic syndrome. PTAS might be considered as a treatment option for ocular ischemic syndrome due to intracranial ICA stenosis when the best medical treatment fails.

## Declaration of patient consent

The authors certify that they have obtained all appropriate patient consent.

## Financial support and sponsorship

Nil.

## Conflicts of interest

There are no conflicts of interest.

## REFERENCES

1. Biousse V, Newman NJ. Eye syndromes and the neuro-ophthalmology of stroke. *Handb Clin Neurol* 2009;93:595-611.
2. Brown GC, Magargal LE. The ocular ischemic syndrome.

- Clinical, fluorescein angiographic and carotid angiographic features. *Int Ophthalmol* 1988;11:239-51.
3. Derdeyn CP, Chimowitz MI, Lynn MJ, Fiorella D, Turan TN, Janis LS, *et al.* Aggressive medical treatment with or without stenting in high-risk patients with intracranial artery stenosis (SAMMPRIS): The final results of a randomized trial. *Lancet* 2014;383:333-41.
  4. Hayashi M, Sato K, Yokouchi T, Harashina JI, Nakayama H, Akahata M, *et al.* Retinal circulation before and after carotid artery stenting. *Surg Cereb Stroke* 2011;39:96-102.
  5. Katsuta T, Fujimoto A, Oba K. Deterioration of glaucoma after carotid endarterectomy. *Neurol Med Chir (Tokyo)* 2013;53:418-21.
  6. Kawaguchi S, Iida J, Uchiyama Y. Ocular circulation and chronic ocular ischemic syndrome before and after carotid artery revascularization surgery. *J Ophthalmol* 2012;2012:350475.
  7. Lee JH, Yun JK, Kim DW, Kang SD. Clinical and angiographic outcomes of wingspan stent placement for treatment of symptomatic intracranial stenosis: Single center experience with 19 cases. *J Cerebrovasc Endovasc Neurosurg* 2012;14:157-63.
  8. Marx JL, Hreib K, Choi IS, Tivnan T, Wertz FD. Percutaneous carotid artery angioplasty and stenting for ocular ischemic syndrome. *Ophthalmology* 2004;111:2284-91.
  9. Mi Lee K, Kim EJ, Heo SH, Kyung HJ. Paradoxical development of neovascular glaucoma following carotid angioplasty and stenting. *Interv Neuroradiol* 2016;22:540-3.
  10. Ng E, Choong AM, Walker, PJ. Neovascular glaucoma post carotid endarterectomy: A case report and review of the literature. *Ann Vasc Dis* 2015;8:103-5.
  11. Ranasinghe T, Boo S, Adcock A. Rare phenomenon of limb-shaking TIA, resolved with intracranial wingspan stenting. *Neurologist* 2019;24:37-9.

**How to cite this article:** Uchida W, Kamide T, Uno T, Yoshikawa A, Misaki K, Nakada M. Ocular ischemic syndrome due to severe internal carotid artery stenosis improved by intracranial stent placement: A case report. *Surg Neurol Int* 2021;12:294.