



Case Report

Hypertrophy of the tensor fascia lata: A pseudotumor due to lumbar radiculopathy

Lisa B.E. Shields¹, Vasudeva Iyer², Rukmaiah C. Bhupalam³, Yi Ping Zhang¹, Christopher B. Shields¹

¹Norton Neuroscience Institute, Norton Healthcare, ²Neurodiagnostic Center of Louisville, ³Norton Neurology Services, Norton Healthcare, Louisville, Kentucky, United States.

E-mail: Lisa B.E. Shields - lbes@earthlink.net; Vasudeva Iyer - pavaiyer@gmail.com; Rukmaiah C. Bhupalam - rukmaiah.bhupalam@nortonhealthcare.org; Yi Ping Zhang - yipingzhang50@gmail.com; *Christopher B. Shields - cbshields1@gmail.com



***Corresponding author:**

Christopher B. Shields,
210 East Gray Street, Suite 1102,
Louisville, Kentucky 40202,
United States.

cbshields1@gmail.com

Received : 25 August 2021

Accepted : 01 September 2021

Published : 19 October 2021

DOI

10.25259/SNI_857_2021

Quick Response Code:



ABSTRACT

Background: Pseudotumor of the tensor fascia lata (TFL) consists of a rare, benign soft tissue mass/hypertrophy of the TFL that appears on the anterolateral aspect of the proximal thigh. Notably, this condition often mimics a malignant tumor and may be misdiagnosed as a sarcoma.

Case Description: A 45-year-old male presented with left hip/groin pain, swelling, and a painful mass on the anterolateral aspect of the left hip/thigh. The symptoms had started 3 months ago following an L1-S1 lumbar laminectomy/fusion. The initial diagnosis was hip disease, and the patient underwent a left MR arthrogram. When this study demonstrated a tear of the left anterosuperior acetabular labrum plus an increased alpha angle causing femoroacetabular impingement, the patient then underwent a left hip arthroscopy. However, as he continued to complain of the hip mass, he was referred to an orthopedic oncologist whose presumptive diagnosis favored a sarcoma. Nevertheless, the pelvic MRI scan and ultrasound (US) confirmed the diagnosis of hypertrophy of the left TFL (US left 33.4 mm vs. right 14.4 mm). The patient was first treated with 50 units of locally injected botulinum. As there was no symptomatic relief, the plan was to repeat the injection within the next few months.

Conclusion: Hypertrophy of TFL may mimic a neoplasm such as a sarcoma and contributes to what appears to be a lumbar radiculopathy. However, MR and US imaging should readily identify TFL and rule out malignant lesions such as sarcomas.

Keywords: Electromyography/nerve conduction studies, Neurogenic hypertrophy, Pseudotumor, Tensor fascia lata, Ultrasound

INTRODUCTION

Hypertrophy of the tensor fascia lata (TFL) muscle is a benign condition that is often mistaken for a tumor. Patients may present with palpable masses, pain, or both in the anterolateral thigh region and/or hip, and symptoms that mimic lumbar radiculopathy.^[7] MR, ultrasound (US), and EMG/NCV studies are the preferred modalities to confirm the diagnosis of TFL hypertrophy.

Here, we present a 45-year-old male with a TFL pseudotumor/hypertrophy that contributed to an L5 radiculopathy.

This is an open-access article distributed under the terms of the Creative Commons Attribution-Non Commercial-Share Alike 4.0 License, which allows others to remix, tweak, and build upon the work non-commercially, as long as the author is credited and the new creations are licensed under the identical terms.

©2021 Published by Scientific Scholar on behalf of Surgical Neurology International

CASE PRESENTATION

Clinical presentation and physical exam

A 45-year-old male presented with left hip/groin pain, swelling, and a painful mass of the anterolateral left hip (i.e. tendency for the left hip to “lock”)/thigh. These symptoms began 3 months following a lumbar laminectomy with an L1-S1 fusion. On examination, prominence of the left TFL was noted along with weakness of left hip abduction and decreased sensation of the left leg/thigh.

MR findings

An MR arthrogram demonstrated a tear of the left anterosuperior acetabular labrum with an increased alpha angle supporting femoroacetabular impingement. Nine months later the patient underwent a left hip arthroscopy with labral repair/base fixation, femoroplasty, and capsular closure. Although the left hip/groin pain improved, he continued to complain of the painful hip mass and was referred to an orthopedic oncologist with the presumed diagnosis of a sarcoma. The pelvic MRI scans demonstrated asymmetry due to hypertrophy of the left TFL [Figure 1a and b]. There was no soft tissue fluid collection or mass.

Ultrasound results for TFL

A substantially greater width of the TFL muscle was observed by high-resolution US on the left (33.4 mm) compared to the right (14.4 mm) side [Figure 2].

EMG/NCV studies

The needle EMG showed chronic denervation/reinnervation changes of the left TFL with large amplitude polyphasic units and complex repetitive discharges. Increased polyphasic units were also observed in the gluteus medius, vastus medialis, and tibialis anterior. The EMG/NCV study suggested chronic lumbosacral radiculopathy involving L4 and L5 on the left.

Treatment with botulinum toxin

The patient underwent an injection of 50 units of botulinum toxin (diluted to 5 units per 0.1 ml) under electromyographic guidance. He attained no improvement of his left leg spasms. Nevertheless, the patient will undergo an injection of 100 units of botulinum toxin within the next 3 months.

DISCUSSION

There are only a few case reports and series in the literature concerning hypertrophy of the TFL [Table 1].^[1-5,7,9] They typically describe a mass in the anterolateral thigh that must be differentiated from sarcomas. MRI is the gold standard for

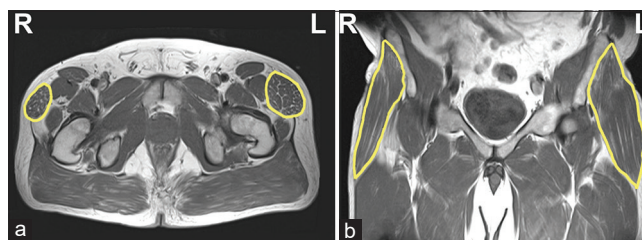


Figure 1: (a) Axial and (b) coronal pelvic MRI scans demonstrating the hypertrophic tensor fascia lata (yellow) on the left as compared to the right side.

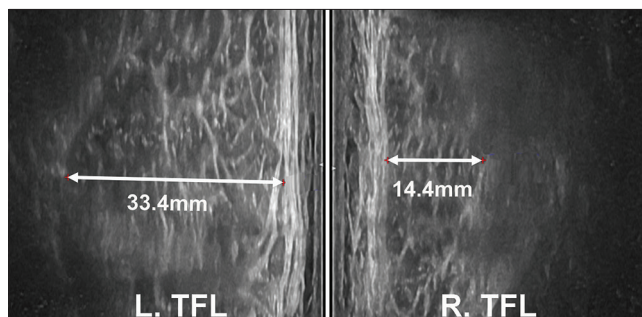


Figure 2: High-resolution ultrasound images revealed a greater width of the tensor fascia lata muscle on the left (33.4 mm) compared to the right (14.4 mm) side.

confirming TFL hypertrophy.^[3,6] US also plays a valuable role in corroborating the diagnosis, along with electromyography [Table 1].^[2]

Treatment of TFL

The treatment of TFL usually involves regular strength training of the hip abductors. Botulinum toxin injections may also be beneficial by mitigating symptoms and decreasing the size of the TFL.^[5]

Etiology of TFL

Two theories exist as to the etiology of pseudotumor of the TFL. These include mechanical vs denervation hypertrophy. For patients who have undergone hip surgery, altered biomechanics may lead to TFL. Compensatory hypertrophy may also occur following abductor tendon (gluteus minimus/medius) tears.^[2,4,10]

In this case, TFL was due to neurogenic hypertrophy related to L5 radiculopathy. While the pelvic MR and US studies revealed true hypertrophy of the TFL on the left side, the EMG showed somewhat non-specific complex repetitive discharges.^[8]

Spine surgeons should be aware that postoperative patients may rarely develop TFL that is best confirmed on MR and US studies. Conservative treatment, including repeated

Table 1: Hypertrophy of the tensor fascia lata.

Study	Number of patients	Gender/ Age (years)	Presenting symptoms	Cause (number of patients)	Imaging findings	Treatment
Haslan <i>et al.</i> 2003	8	6 F/2 M 27–86	Palpable proximal anterior thigh mass (7/8 patients); thigh pain in three of these patients; one patient asymptomatic	3: prior surgery with altered weight-bearing mechanics 2: contralateral total hip arthroplasty 1: ipsilateral osteotomy for hip dysplasia 1: Charcot-Marie-Tooth 1: diabetic neuropathy	MRI: Unilateral enlargement of TFL muscle (8/8 patients)	Not reported
Soltanzadeh <i>et al.</i> 2005	1	F/55	Painful mass upper thigh	Lumbosacral radiculopathy	MRI: unilateral TFL hypertrophy, atrophy of vastus lateralis and rectus femoris; Electrodiagnostic tests: acute and chronic denervation L5 myotome, mainly in TFL	Not reported
Chang <i>et al.</i> 2007	1	F/57	Low back and left thigh pain; growth within thigh	Spinal radiculopathy	MRI: Hypertrophy of TFL muscle	Epidural steroid injection, spine strengthening rehabilitation
Pardal-Fernandez <i>et al.</i> 2011	1	M/47	Sciatic pain, thigh “lump”	L5 radiculopathy	MRI: myotome L5 hypertrophy; EMG: complex repetitive discharges at rest, chronic reinnervation under voluntary activity	Botulinum toxin injections
Meijer <i>et al.</i> 2017	1	M/68	Swelling anterolateral thigh	Abductor tendon tear	MRI: unilateral TFL hypertrophy	Abductor training
Rodriguez-Roiz <i>et al.</i> 2017	5	3 M/2 F Average age: 68.8	Lateral hip pain (3 patients); lateral hip pain and palpable mass (2 patients)	4: Following THA 1: Following THAR	MRI/CT: gluteus minimus and medius atrophy on side of arthroplasty (5/5 patients)	Physiotherapy of pelvic and trochanteric area, NSAIDs
Jimenez Hidalgo <i>et al.</i> 2020	2	F/51 F/69	Hip pain, soft tissue tumor proximal thigh (1 patient); swelling and pain of the anterior thigh (1 patient)	1: Weakness of abductor muscles of hip (1 patient) 1: Not specified	MRI: TFL hypertrophy, gluteal muscle atrophy, degenerative changes coxo-femoral joint (1 patient) MRI: TFL muscle hypertrophy; US: same echogenicity of muscle fibers, no increased blood flow, TFL hypertrophy suggests pseudotumor (1 patient)	Unspecified conservative treatment
Current Case 2021	1	M/45	Left hip and groin pain, swelling, painful mass anterolateral hip	L5 radiculopathy	MRI: asymmetric hypertrophy, edema TLF muscle on anterior hip; EMG: denervation changes in TFL with large amplitude polyphasic units and complex repetitive discharges; US: TFL width left vs right (33.4 vs 14.4 mm)	Botulinum toxin injection

TFL: Tendon fascia lata, MRI: Magnetic resonance imaging, US: Ultrasound, THA: Total hip arthroplasty, THAR: Total hip arthroplasty revision, NSAIDs: Nonsteroidal anti-inflammatory drugs

injections of botulinum toxin, may be helpful in remediating persistent TFL symptoms/radiculopathy.

Declaration of patient consent

Institutional Review Board (IRB) permission obtained for the study.

Financial support and sponsorship

Nil.

Conflicts of interest

There are no conflicts of interest.

REFERENCES

1. Chang DG, Magee E, Hughes T. Denervation hypertrophy in lumbosacral radiculopathy. *J Neurol Neurosurg Psychiatry* 2008;79:1170.
2. Hidalgo PJ, Haro JA, Santos LM, Mananes RP, Dehesa MC, Barroso CL. Hypertrophy of the faciae latae: A pseudotumor of the thigh. *Arch Clin Exp Surg* 2020;9:22-4.
3. Ilaslan H, Wenger DE, Shives TC, Unni KK. Unilateral hypertrophy of tensor fascia lata: A soft tissue tumor simulator. *Skeletal Radiol* 2003;32:628-32.
4. Meijer RP, Jasper J, Snoeker B, Jansen J. A pseudotumour of the thigh: Tensor fasciae latae muscle hypertrophy due to an underlying abductor tendon tear. *BMJ Case Rep* 2017;2017:bcr2017219542.
5. Pardal-Fernandez JM, Beato-Perez JL, Lozano-Setien E, Iniesta-Lopez I. Denervation hypertrophy in L5 radiculopathy. *Rev Neurol (Paris)* 2011;167:545-6.
6. Petersilge CA, Pathria MN, Gentili A, Recht MP, Resnick D. Denervation hypertrophy of muscle: MR features. *J Comput Assist Tomogr* 1995;19:596-600.
7. Rodriguez-Roiz JM, Bori G, Tomas X, Fernandez-Valencia JA, Garcia-Diez AI, Pomes J, *et al.* Hypertrophy of the tensor fascia lata muscle as a complication of total hip arthroplasty. *Eur J Orthop Surg Traumatol* 2017;27:255-9.
8. Rousseff RT, Tzvetanov P. Muscle hypertrophy with complex repetitive discharges in C-6 radiculopathy. *Clin Neurol Neurosurg* 2005;107:425-7.
9. Soltanzadeh P, Pierce B, Lietman S, Iislan H. Unilateral tensor fascia lata muscle mass as a presentation of lumbosacral radiculopathy. *Neuromuscul Dis* 2015;25:S242-3.
10. Sutter R, Kalberer F, Binkert CA, Graf N, Pfirrmann CW, Gutzeit A. Abductor tendon tears are associated with hypertrophy of the tensor fasciae latae muscle. *Skeletal Radiol* 2013;42:627-33.

How to cite this article: Shields LBE, Iyer V, Bhupalam RC, Zhang YP, Shields CB. Hypertrophy of the tensor fascia lata: A pseudotumor due to lumbar radiculopathy. *Surg Neurol Int* 2021;12:522.