




Original Article

Surgical safety criteria for burr hole surgery with urokinase in patients with acute subdural hematoma: Retrospective comparison between burr hole surgery and craniotomy

Airi Miyazaki, Takashi Nakagawa, Jin Matsuura, Yoshihiro Takesue, Tadahiro Otsuka

Department of Neurosurgery, National Hospital Organization Kumamoto Medical Center, Kumamoto, Japan.

E-mail: *Airi Miyazaki - airienoki@gmail.com; Takashi Nakagawa - tnakagawa430@gmail.com; Jin Matsuura - mj_1593_mj@yahoo.co.jp; Yoshihiro Takesue - yoshihiro_takesue@yahoo.co.jp; Tadahiro Otsuka - otk@kumamed.jp



***Corresponding author:**

Airi Miyazaki,
Department of Neurosurgery,
National Hospital Organization
Kumamoto Medical Center,
Kumamoto, Japan.

airienoki@gmail.com

Received : 20 April 2021

Accepted : 04 November 2021

Published : 23 November 2021

DOI

10.25259/SNI_388_2021

Quick Response Code:



ABSTRACT

Background: Acute subdural hematoma (ASDH) is a common disease and craniotomy is the first choice for removing hematoma. However, patients for whom craniotomy or general anesthesia is contraindicated are increasing due to population aging. In our department, we perform burr hole surgery under local anesthesia with urokinase administration for such patients. We compared the patient background and outcomes between burr hole surgery and craniotomy to investigate the surgical safety criteria for burr hole surgery.

Methods: We reviewed 24 patients who underwent burr hole surgery and 33 patients who underwent craniotomy between January 2010 and April 2020 retrospectively.

Results: The median age of the burr hole surgery group was older ($P = 0.01$) and they had multiple pre-existing conditions. Compared with the craniotomy group, neurological deficits and CT findings were minor in the burr hole surgery group, whereas the maximum hematoma thickness was not significantly different. The hematoma was excreted after a total of 54,000 IU of urokinase was administered for a median of 3 days. The Glasgow Coma Scale score improved in all patients in the burr hole surgery group and there were no deaths. Age, especially over 65 y.o., (OR 1.16, 95% CI 1.04–1.30) and the absence of basal cistern disappearance (OR 0.04, 95% CI 0.004–0.39) were significant factors.

Conclusion: Burr hole surgery was performed safely in all patients based on the age, especially older than 65 y.o., and the absence of basal cistern disappearance. ASDH in the elderly is increasing and less invasive burr hole surgery with urokinase is suitable for the super-aging society.

Keywords: Acute subdural hematoma, Burr hole surgery, Urokinase

INTRODUCTION

Acute subdural hematoma (ASDH) is a common disease caused by traumatic brain injury (TBI). ASDH compresses the brain and causes secondary pathologies such as cerebral ischemia and swelling. As a result, patients have a poor prognosis. Craniotomy for the removal of hematoma is recommended as the treatment method in the following cases: (1) The width of hematoma

is 1 cm or greater, or the midline shift is 5 mm or greater. (2) Patients exhibit neurological symptoms due to hematoma. (3) The Glasgow Coma Scale (GCS) score decreased by more than two points.^[5,8] However, in the super-aging society of Japan, the incidence curve of TBI by age group is transitioning from two peaks, 15–29 and 65–79 y.o., to a single peak representing the elderly.^[9] Therefore, patients with ASDH who are unable to undergo craniotomy and general anesthesia due to age, general condition, or anti-thrombotic drug use are common. In our department, craniotomy is the first choice, but we perform burr hole evacuation under local anesthesia with urokinase injection on ASDH patients meeting one of the following criteria: (1) over 80 years old, (2) bleeding tendency or anti-thrombotic drug use, (3) on dialysis, (4) taking antipsychotic medicine, or (5) surgeon's decision that craniotomy or general anesthesia is inappropriate. In addition, patients with extensive brain contusion should be assessed for bleeding points and undergo decompression; therefore, we set the following exclusion criteria: (1) extensive brain contusion or (2) decompression required. Several studies reported burr hole surgery or twist drill craniostomy on ASDH patients without subsequent craniotomy.^[1,6,11] In this report, we retrospectively compared the patient background and outcomes of burr hole surgery and craniotomy for ASDH in our department to determine the safety criteria for burr hole surgery.

MATERIALS AND METHODS

Patients

We reviewed patients with ASDH as the main disease between January 2010 and April 2020 retrospectively. The following parameters were collected: age, gender, history of trauma, medical history, such as bleeding tendency or anti-thrombotic drug use, preoperative GCS score, pupil abnormality, maximum hematoma thickness, midline shift, patency of basal cistern, and skull fracture on preoperative computed tomography (CT). Outcomes were the length of hospitalization and days until operation from onset, the number of patients with urokinase administration, administration days and total dose, reduction of subdural hemorrhage (SDH) volume, GCS score at discharge, improved GCS score, mortality, and hospitalization. SDH volume was calculated as $\text{length} \times \text{width} \times \text{depth} / 2$ and reduction of SDH volume (%) was calculated as $([\text{volume at preoperative SDH} - \text{SDH volume at drain removal}] / \text{volume at preoperative SDH} \times 100)$. Reduction of SDH volume was rated as excellent ($\geq 75\%$), good ($\geq 50\%$), fair ($\geq 25\%$), or poor ($< 25\%$).

Operative technique for burr hole surgery

The incision was performed with local anesthesia under sedation. The hematoma was aspirated as much as possible

and a drainage tube was inserted into the subdural space. If the hematoma did not decrease on CT the following day, urokinase (diluted to 60,000 units in 10 ml of saline, using 18,000–36,000 units/day) was injected. After clamping for 2 h, the hematoma drain was opened. These steps were repeated until the effects of hematoma were reduced [Figure 1].

Statistical analysis

We used the χ^2 test and Mann-Whitney U test in univariate analysis, and logistic regression analysis in multivariate analysis. In our analyses, differences were considered significant at a value of $P < 0.05$. The statistical analyses were performed using IBM SPSS Statistics 27 (SPSS Inc., Chicago, IL, USA).

Ethical statement

Informed consent was received from all patients and this study protocol was approved by the ethics review committee of our institution (July 2020, IRB No. 844).

RESULTS

Twenty-four patients who underwent burr hole surgery and 33 who underwent craniotomy were available for analysis

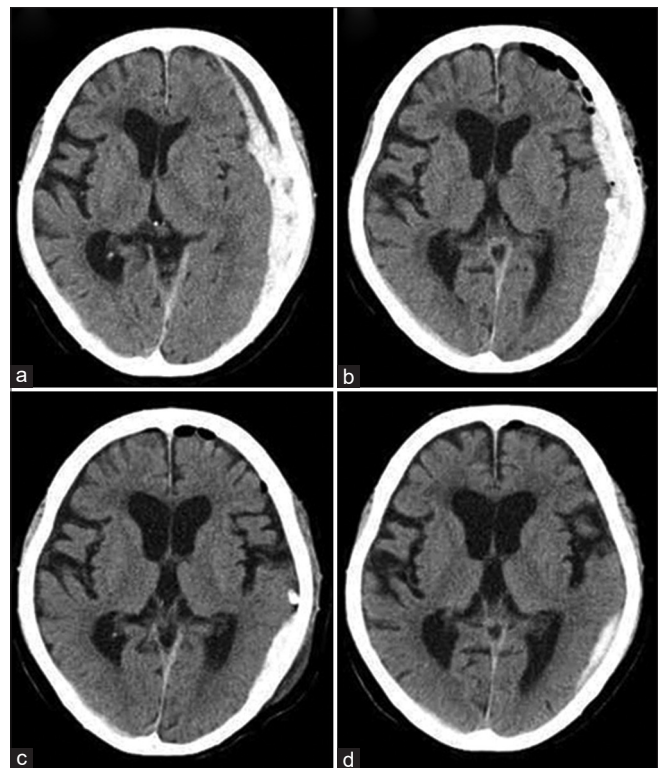


Figure 1: Computed tomography (CT) in a typical case of burr hole surgery (a) on arrival (day 0), (b) after the operation (day 1), (c) after drainage using urokinase (day 3), and (d) follow-up (day 8).

among a total of 604 ASDH patients. Those who underwent mini-craniotomy had chronic subdural hematoma, or underwent surgery more than 5 days after onset were excluded.

Patient characteristics are compared in Table 1. The median age was higher in the burr hole surgery group (81.0 ± 8.3 vs. 63.3 ± 20.5 ; $P = 0.01$). Sixteen patients had a history of trauma in the burr hole surgery group, with all sustaining minor head trauma due to a fall from standing except for one who was in a motorcycle accident. Accordingly, there were no fractures except in one patient in the burr hole surgery group. Twenty-three patients had a history of trauma in the craniotomy group, which included 13 cases of fall from standing, seven of falling, and three motorcycle accidents. A higher percentage of patients in the burr hole surgery group had a medical history, with higher rates of bleeding tendency (50% vs. 21%; $P = 0.023$), heart disease (25% vs. 3%; $P = 0.013$), and stroke (42% vs. 6%; $P = 0.001$). The median maximum hematoma thickness was slightly larger in the craniotomy group, although the difference was

not significant (17 ± 5 vs. 19 ± 5 mm; $P = 0.3$). However, preoperative GCS score (9.5 ± 3.5 vs. 7.0 ± 3.2 ; $P = 0.006$), pupil abnormality ($P = 0.001$), midline shift (7 ± 4 vs. 14 ± 4 mm; $P = 0.00$), and the findings of patency of basal cistern ($P = 0.00$) were minor in the burr hole surgery group. Simple hematoma accounted for 75% in the burr hole surgery group (vs. 42%; $P = 0.01$).

Craniotomy was performed on the day of admission, whereas burr hole surgery was often performed the day after confirming hemostasis on CT or when neurological findings worsened [Table 2]. According to surgical records, the hematoma was a solid component and all but one patient required urokinase injection in the burr hole surgery group. A median of 3 days with a total of 54,000 IU of urokinase resulted in good hematoma excretion in many patients and there were no complications from urokinase such as rebleeding. The GCS score improved in all patients in the burr hole surgery group and there were no deaths. Hemorrhage from cerebral contusion resulted in residual SDH in a few patients in the craniotomy group.

Table 1: Patient characteristics.

	Burr hole surgery (n=24)	Craniotomy (n=33)	P-value
Demographic data			
Age	81.0±8.3	63.3±20.5	0.01
Gender male/female	14/10	21/12	0.7
History of trauma			0.7
Present	16 (67%)	23 (70%)	
Absent	1 (4%)	3 (9%)	
Unknown	7 (29%)	7 (21%)	
Bleeding tendency	12 (50%)	7 (21%)	0.02
Heart disease	6 (25%)	1 (3%)	0.01
Mental illness	8 (33%)	7 (21%)	0.3
Diabetes mellitus	6 (25%)	3 (9%)	0.1
Renal failure	2 (8%)	1 (3%)	0.4
Stroke	10 (42%)	2 (6%)	0.001
Preoperative neurological status			
GCS	9.5±3.5	7.0±3.2	0.006
Pupil abnormality			0.001
Normal	19 (79%)	9 (27%)	
Anisocoria	4 (17%)	21 (64%)	
Bilateral dilatation	1 (4%)	3 (9%)	
Preoperative CT findings			
Maximum hematoma thickness (mm)	17±5	19±5	0.3
Midline shift (mm)	7±4	14±4	0.00
Simple hematoma type	18 (75%)	14 (42%)	0.01
Patency of basal cistern			0.00
Normal	9 (37%)	0	
Compression	11 (46%)	11 (33%)	
Disappearance	4 (17%)	22 (67%)	
Skull fracture	1 (4%)	11 (33%)	0.01

The patients in the burr hole surgery group were older and had a more extensive medical history. The median maximum hematoma thickness was not significantly different, whereas neurological deficits and other CT findings were mild in the burr hole surgery group. GCS: Glasgow coma scale

Table 2: Patient outcomes.

	Burr hole surgery (n=24)	Craniotomy (n=33)	P-value
Hospitalization from onset (day)	0	0	0.1
Operation from onset (day)	1.5	0	0.00
Urokinase			
Case	23 (96%)	0	
Administration period (day)	3		
Total dose (IU)	54,000±29,000		
Reduction of SDH volume			0.1
Excellent (≥75%)	17 (71%)	26 (79%)	
Good (≥50%)	5 (21%)	2 (6%)	
Fair (≥25%)	2 (8%)	1 (3%)	
Poor (<25%)	0	4 (12%)	
GCS at discharge	14.0±2.5	10.0±4.0	0.001
Improved GCS score	2.0±2.7	1.0±3.3	0.1
Dead	0	4 (12%)	0.08
Hospitalization (day)	11.0±9.0	18.0±42.5	1.0

A median of 3 days with a total of 54,000 IU of urokinase resulted in good hematoma excretion. The GCS score improved in all patients in the burr hole surgery group and there were no deaths. SDH: Subdural hemorrhage, GCS: Glasgow coma scale

We selected 6 variables (age, bleeding tendency, GCS, simple hematoma type, pupil abnormality, and patency of the basal cistern) that were significantly related to the selection of burr hole surgery. Their predictive values were analyzed through multivariate logistic regression [Table 3]. Age and disappearance of the basal cistern were significant in model 1. Furthermore, the odds ratio was higher when age was divided at 65 y.o. in model 2.

DISCUSSION

Burr hole surgery was selected to avoid the risks of general anesthesia and craniotomy such as bleeding or postoperative pneumonia.^[17] The craniotomy group, including patients requiring immediate surgery or decompression, exhibited severe neurological deficits before and after surgery. On the other hand, the patients in the burr hole surgery group were older and had a more extensive medical history than those in the craniotomy group. In general, geriatric TBI has a higher morbidity and mortality.^[9] However, burr hole surgery was performed safely without death or deterioration of the GCS score. Previous studies also reported positive results of burr hole surgery in patients for whom general anesthesia or craniotomy have a high risk.^[6,11]

The safety criteria for burr hole surgery in this study were age, especially over 65 y.o., and the absence of basal cistern disappearance. These two points may lead to safe burr hole surgery. As the brain volume decreases in the elderly, the volume of subdural space increases and buffers compression of the brain by the hematoma.^[9] In this study, the burr hole surgery group, which was predominantly elderly, exhibited mild neurological deficits and CT findings, whereas the hematoma thickness was not significantly different between

the two groups. Similarly, the absence of basal cistern disappearance was considered to reflect mild hematoma compression and mild increase in the intracranial pressure (ICP). This may have been because 75% of the burr hole surgery group had a simple hematoma. The remaining 25% lacked major contusion and diffuse subarachnoid hemorrhage. Indeed, ASDH patients with contusion were reported to have a higher rate of increased ICP postoperatively than those without contusion.^[16] However, ICP was not measured in this study, but mild compression of the brain or increased ICP due to enlargement of the subdural space with age and simple hematoma may be important for safe burr hole surgery.

The disadvantages of burr hole surgery are the inability of hemostasis and excretion of solid hematoma. Regarding hemostasis, burr hole surgery was performed on a wait-and-see basis from the day after admission or at the time of worsening of neurological findings, during which natural hemostasis may have been achieved. In this study, as mentioned earlier, patients in the burr hole surgery group had mild neurological deficits and CT findings, which may have made it possible to perform a standby operation. In addition, the hematoma that was removed intraoperatively was in a solid state, with only a small amount just below the burr hole, and no intraoperative rebleeding occurred unless the hematoma was touched at the bleeding point. As for the remaining solid hematoma, excretion was good after the use of urokinase and there were no complications such as rebleeding. There is no prospective randomized study on subdural irrigation using alteplase. According to CLEAR III, alteplase irrigation via an extraventricular drain did not improve functional outcomes compared with saline irrigation. However, protocol-based use of alteplase was

Table 3: Multiple logistic regression analysis of factors that affect the selection of burr hole surgery.

Model 1	P-value	Odds ratio	95% Confidence interval
Age	0.009	1.160	1.038–1.295
Disappearance of the basal cistern	0.006	0.037	0.004–0.388
Simple hematoma type	0.146	4.267	0.603–30.192
Pupil abnormality	0.256	7.447	0.233–237.660
Bleeding tendency	0.307	2.461	0.437–13.873
GCS	0.603	1.078	0.812–1.431
Model 2	P-value	Odds ratio	95% Confidence interval
Over 65 years old	0.049	9.507	1.007–89.732
Disappearance of the basal cistern	0.006	0.059	0.008–0.441
Simple hematoma type	0.112	4.017	0.724–22.296
Pupil abnormality	0.360	6.004	0.129–278.836
Bleeding tendency	0.139	3.304	0.678–16.098
GCS	0.482	1.103	0.839–1.451

Age and disappearance of the basal cistern were significant. The odds ratio was higher when age was divided at 65 y.o. GCS: Glasgow coma scale

suggested to be safe.^[4] Although the evidence is lacking, urokinase is commonly used for hematoma dissolution in intracerebral hematoma or intraventricular hematoma.^[2,14,15] It was also used in previous reports of burr hole surgery for ASDH, and no complications were reported.^[1,6] We also used urokinase, expecting for hemolytic effect. A median of 3 days was required for hematoma excretion after burr hole surgery.

In this study, half of the patients in the burr hole surgery group had a history of bleeding tendency. However, this was not related to the choice of operation. The number of patients with pre-existing medical conditions is increasing as the population ages and 30% of patients with severe TBI aged over 65 y.o. are taking antithrombotic drugs in Japan.^[12] In addition, the incidence of minor head injuries, such as by fall from standing, is increasing in the elderly.^[3,7,9] The frequencies of intracranial hemorrhage in patients with minor head injuries were reported to be 6.3% with no antithrombotic drug, 8.1% with an anticoagulation drug, 12.9% with an antiplatelet drug, and 25.8% with dual antiplatelet drugs.^[13] In a report comparing 36 ASDH patients >65 y.o. and 44 ASDH patients <65 y.o., the elderly group had a high rate of antithrombotic drug use (73%) and 80% of the injuries were minor head injuries caused by fall from standing. Although there was no significant difference in the amount of hematoma, the elderly group had a smaller amount, and the GCS score at admission was 14.24 in the elderly group compared with 11.56 in the young group.^[10] The results reflect the patient background of the burr hole surgery group being older, whereas the craniotomy group was younger. Thus, elderly patients may be more prone to ASDH due to a higher rate of fall from standing and antithrombotic medications. Therefore, many elderly patients with ASDH who meet the surgical criteria for craniotomy are likely mildly symptomatic, making

craniotomy and general anesthesia unfavorable. Due to population aging, such ASDH patients are expected to increase and less-invasive burr hole surgery with urokinase may be a timely option.

LIMITATIONS

This was a single-center, retrospective study with a small sample size. The patients exhibited severe neurological deficits, and immediate craniotomy and decompression were required based on CT. Therefore, there may have been a selection bias. As there is no consensus on burr hole surgery with urokinase in patients with ASDH, further studies with a larger sample size and prospective randomized trials are required.

CONCLUSION

Burr hole surgery was performed safely in all patients for whom craniotomy and general anesthesia were unfavorable. Burr hole surgery was selected based on age, especially in those over 65 y.o., and the absence of basal cistern disappearance. ASDH in the elderly due to minor head injury is increasing due to the aging population and increased use of antithrombotic drugs. Accordingly, burr hole surgery with urokinase avoids the risks of craniotomy and general anesthesia and is suitable for the super-aging society.

Declaration of patient consent

Institutional Review Board (IRB) permission obtained for the study.

Financial support and sponsorship

Nil.

Conflicts of interest

There are no conflicts of interest.

REFERENCES

1. Cho SW, Choi SW, Lim J, Kwon HJ, Kim SH, Koh HS, *et al.* Burr hole drainage with urokinase irrigation for the treatment of acute subdural hematoma: A case report. *Korean J Neurotrauma* 2018;14:142-5.
2. Gaberel T, Magheru C, Parienti JJ, Huttner HB, Vivien D, Emery E. Intraventricular fibrinolysis versus external ventricular drainage alone in intraventricular hemorrhage: A meta-analysis. *Stroke* 2011;42:2776-81.
3. Gardner RC, Dams-O'Connor K, Morrissey MR, Manley GT. Geriatric traumatic brain injury: Epidemiology, outcomes, knowledge gaps, and future directions. *J Neurotrauma* 2018;35:889-906.
4. Hanley DF, Lane K, McBee N, Ziai W, Tuhim S, Lees KR, *et al.* Thrombolytic removal of intraventricular haemorrhage in treatment of severe stroke: Results of the randomised, multicentre, multiregion, placebo-controlled CLEAR III trial. *Lancet* 2017;389:603-11.
5. Huang AP, Tu YK, Tsai YH, Chen YS, Hong WC, Yang CC, *et al.* Decompressive craniectomy as the primary surgical intervention for hemorrhagic contusion. *J Neurotrauma* 2008;25:1347-54.
6. Huang PK, Sun YZ, Xie XL, Kang DZ, Zheng SF, Yao PS. Twist drill craniostomy for traumatic acute subdural hematoma in the elderly: Case series and literature review. *Chin Neurosurg J* 2019;5:10.
7. Kannus P, Palvanen M, Niemi S, Parkkari J, Natri A, Vuori I, *et al.* Increasing number and incidence of fall-induced severe head injuries in older adults: Nationwide statistics in Finland in 1970-1995 and prediction for the future. *Am J Epidemiol* 1999;149:143-50.
8. Karibe H, Hayashi T, Hirano T, Kameyama M, Nakagawa A, Tominaga T. Surgical management of traumatic acute subdural hematoma in adults: A review. *Neurol Med Chir (Tokyo)* 2014;54:887-94.
9. Karibe H, Hayashi T, Narisawa A, Kameyama M, Nakagawa A, Tominaga T. Clinical characteristics and outcome in elderly patients with traumatic brain injury: For establishment of management strategy. *Neurol Med Chir (Tokyo)* 2017;57:418-25.
10. Lucke-Wold BP, Turner RC, Josiah D, Knotts C, Bhatia S. Do age and anticoagulants affect the natural history of acute subdural hematomas? *Arch Emerg Med Crit Care* 2016;1:1010.
11. Sato J, Karibe H, Nimura T, Hirano T, Takada S. The effect of trepanation surgery to the cases with difficulties in craniotomy for acute subdural hematoma. *J Jpn Congr Neurol Emerg* 2009;21:39-43.
12. Suehiro E, Fujiyama Y, Kiyohira M, Haji K, Ishihara H, Nomura S, *et al.* Japan neurotrauma data bank committee. Risk of deterioration of geriatric traumatic brain injury in patients treated with antithrombotic drugs. *World Neurosurg* 2019;127:e1221-7.
13. Uccella L, Zoia C, Bongetta D, Gaetani P, Martig F, Candrian C, *et al.* Are antiplatelet and anticoagulants drugs a risk factor for bleeding in mild traumatic brain injury? *World Neurosurg* 2018;110:e339-45.
14. Volbers B, Niesen WD, Amiri-Soltani S, Staykov D, Shah MJ, Lang S, *et al.* Bedside catheter hematoma evacuation in vitamin k antagonist-related intracerebral hemorrhage: A safe and feasible approach. *Front Neurol* 2020;11:807.
15. Wang GQ, Li SQ, Huang YH, Zhang WW, Ruan WW, Qin JZ, *et al.* Can minimally invasive puncture and drainage for hypertensive spontaneous basal ganglia intracerebral hemorrhage improve patient outcome: A prospective non-randomized comparative study. *Mil Med Res* 2014;1:10.
16. Wilberger JE Jr, Harris M, Diamond DL. Acute subdural hematoma: Morbidity, mortality, and operative timing. *J Neurosurg* 1991;74:212-8.
17. Zhang D, Zhuo H, Yang G, Huang H, Li C, Wang X, *et al.* Postoperative pneumonia after craniotomy: Incidence, risk factors and prediction with a nomogram. *J Hosp Infect* 2020;105:167-75.

How to cite this article: Miyazaki A, Nakagawa T, Matsuura J, Takesue Y, Otsuka T. Surgical safety criteria for burr hole surgery with urokinase in patients with acute subdural hematoma: Retrospective comparison between burr hole surgery and craniotomy. *Surg Neurol Int* 2021;12:574.