



Case Report

Postoperative vasovagal cardiac arrest after spinal anesthesia for lumbar spine surgery

Caitlin Keenan¹, Andy Y. Wang¹, Konstantin Balonov², James Kryzanski¹

Departments of ¹Neurosurgery, ²Anesthesiology, Tufts Medical Center, Washington, Boston, United States.

E-mail: Caitlin Keenan - caitlin.keenan@tufts.edu; Andy Y. Wang - andy.wang@tufts.edu; Konstantin Balonov - kbalonov@tuftsmedicalcenter.org;

*James Kryzanski - jkryzanski@tuftsmedicalcenter.org



*Corresponding author:

James Kryzanski,
Department of Neurosurgery,
Tufts Medical Center,
Washington, Boston, United
States.

jkryzanski@tuftsmedicalcenter.org

Received : 06 January 2022

Accepted : 13 January 2022

Published : 11 February 2022

DOI

10.25259/SNI_25_2022

Quick Response Code:



ABSTRACT

Background: Spinal anesthesia is being increasingly recognized as a favorable alternative to general anesthesia. However, there are still several considerations for its safe and effective use.

Case Description: A 62-year-old male received spinal anesthesia during an uneventful L3-L5 decompressive laminectomy. However, he subsequently experienced a brief episode of pulseless electrical activity in the post-anesthesia care unit, and was successfully resuscitated without further sequelae. This was attributed to a vasovagal episode, with his notable prior history of experiencing vasovagal syncope with lightheadedness and fainting at the sight of blood.

Conclusion: Patients with a history of vasovagal syncope may be predisposed to experiencing brief potentiated episodes of severe bradycardia and even cardiac arrest following spinal anesthesia.

Keywords: Cardiac arrest, Lumbar spine, Pulseless electrical activity, Spinal anesthesia, Vasovagal

INTRODUCTION

Spinal anesthesia during lumbar surgery is a safe and effective alternative to general anesthesia for patients across a wide range of ages and health statuses.^[1] Most candidates for lumbar surgery are appropriate for spinal anesthesia, but there are certain considerations that may preclude/limit its use. Here, we present a 62-year-old male who underwent an L3-L5 decompressive laminectomy under spinal anesthesia and experienced a brief postoperative episode of pulseless electrical activity (PEA), deemed to be a vasovagal event.

CASE DESCRIPTION

A 62-year-old male presented with progressive/severe neurogenic claudication. He had a previous L1 burst fracture with fusion surgery 10 years prior, and now has severe L3/L4 and L4/L5 spinal stenosis on imaging [Figure 1]. He also had a notable history of several vasovagal syncopal episodes attributed to needles and blood, a trait shared by several relatives. Following a routine L3-L5 laminectomy with onlay arthrodesis under spinal anesthesia, the patient was brought to the post-anesthesia care unit (PACU). He initially reported being lightheaded, and a nurse subsequently noted precipitous bradycardia that progressed to PEA arrest. Chest compressions

This is an open-access article distributed under the terms of the Creative Commons Attribution-Non Commercial-Share Alike 4.0 License, which allows others to remix, transform, and build upon the work non-commercially, as long as the author is credited and the new creations are licensed under the identical terms.

©2022 Published by Scientific Scholar on behalf of Surgical Neurology International

and the routine arrest protocol were initiated; after 30 s, the patient had return of spontaneous circulation and had an uneventful recovery. Cardiology and electrophysiology

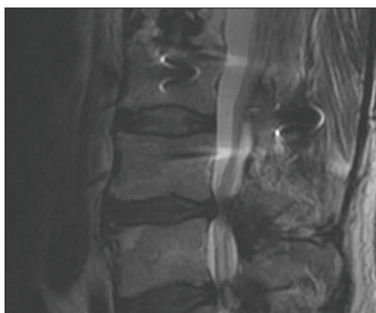


Figure 1: Preoperative sagittal T2-weighted magnetic resonance imaging showing prior L1 surgery and severe spinal stenosis at L3-L4 and L4-L5.

concluded that this event was most likely a vagal response to anesthesia.

DISCUSSION

Here, we present the case of a 62-year-old male who experienced brief PEA arrest in the PACU after an uneventful lumbar surgery under spinal anesthesia. This episode was attributed to a vasovagal reflex (also known as the Bezold-Jarisch reflex or neurocardiogenic syncope).^[4] This reflex can result in bradycardia, vasodilation, and hypotension. This may occur in surgery under spinal anesthesia for several reasons: blood loss/hypovolemia, sympathetic blockade/peripheral vasodilation/reduced venous return, and positioning (i.e., reverse-Trendelenburg and sitting upright) with venous pooling in the lower extremities.^[4] However, in the setting of spinal anesthesia, it can cause

Table 1: Overview of reported cases of bradycardia/asystole occurring with neuraxial anesthesia where either (1) the event occurred post-operatively or (2) the patient had a history of vasovagal episodes.

Authors	Age	History of vasovagal episodes	Operation	Anesthesia	Event	Setting	Resuscitation outcome
Present case	62	Fainted at the sight of a needle and felt light-headed during gory movies	L3-L5 decompressive laminectomy	Spinal	Asystole	PACU	Full recovery
Geffin <i>et al.</i> ^[2]	54	None reported	Cystoceleatomy	Spinal	Severe bradycardia (HR=35)	PACU	Full recovery
Geffin <i>et al.</i> ^[2]	27	Two syncope episodes while giving blood	Cysto, fulguration	Spinal	Severe bradycardia (HR=30)	PACU	Full recovery
Løvstad <i>et al.</i> ^[6]	50	None reported	Knee arthroscopy	Spinal	Asystole	OR (right after operation end)	Full recovery
Thrush <i>et al.</i> ^[9]	37	Passing out at sight of needles and fainting (with stable HR and BP) after receiving spinal anesthetic	Cervical cerclage	Spinal	Asystole	OR	Full recovery
Jang <i>et al.</i> ^[3]	39	10-year history of daily self-limited palpitations	Cesarean section	Spinal	Asystole	OR	Full recovery
Liguori <i>et al.</i> ^[5]	34	History of fainting	Anterior cruciate ligament reconstruction	Epidural	Asystole	OR	Full recovery
Liguori <i>et al.</i> ^[5]	42	None reported	Anterior cruciate ligament reconstruction	Epidural	Asystole	PACU	Full recovery
Liguori <i>et al.</i> ^[5]	65	None reported	Total knee replacement	Epidural	Severe bradycardia (HR=28)	PACU	Full recovery

PACU: Post anesthesia care unit, OR: Operating room, HR: Heart rate

serious complications by precipitating bradycardia and asystole.^[7]

There is precedent in the literature for patients with a history of vasovagal episodes experiencing similar events under regional anesthesia [Table 1].^[2,3,5,6,9] There are certain factors that appear to increase this risk: young age, ASA status, beta blocker therapy, and a sensory level above T6.^[8]

Kinsella *et al.* offer several suggestions for avoiding vasovagal arrest under spinal anesthesia.^[4] To treat bradycardia during spinal anesthesia, Pollard *et al.* recommends the stepwise use of atropine, ephedrine, and epinephrine.^[8] We add that vasovagal arrest can also occur in the PACU setting in spinal anesthesia patients, and recommend screening for a history of vasovagal episodes.

CONCLUSION

This case report describes an episode of vasovagal cardiac arrest occurring in the PACU following spinal anesthesia for lumbar stenosis surgery, and we recommend asking patients about their history of vasovagal events to gain some insight into their risk for vasovagal complications such as PEA following spinal anesthesia.

Declaration of patient consent

The authors certify that they have obtained all appropriate patient consent.

Financial support and sponsorship

Nil.

Conflicts of interest

There are no conflicts of interest.

REFERENCES

1. Breton JM, Ludwig CG, Yang MJ, Nail TJ, Riesenburger RI, Liu P, *et al.* Spinal anesthesia in contemporary and complex lumbar spine surgery: Experience with 343 cases. *J Neurosurg Spine* 2021;1-8.
2. Geffin B, Shapiro L. Sinus bradycardia and asystole during spinal and epidural anesthesia: A report of 13 cases. *J Clin Anesth* 1998;10:278-85.
3. Jang YE, Do SH, Song IA. Vasovagal cardiac arrest during spinal anesthesia for Cesarean section-a case report. *Korean J Anesthesiol* 2013;64:77-81.
4. Kinsella SM, Tuckey JP. Perioperative bradycardia and asystole: Relationship to vasovagal syncope and the Bezold-Jarisch reflex. *Br J Anaesth* 2001;86:859-68.
5. Liguori GA, Sharrock NE. Asystole and severe bradycardia during epidural anesthesia in orthopedic patients. *Anesthesiology* 1997;86:250-7.
6. Løvstad RZ, Granhus G, Hetland S. Bradycardia and asystolic cardiac arrest during spinal anaesthesia: A report of five cases. *Acta Anaesthesiol Scand* 2000;44:48-52.
7. Mackey DC, Carpenter RL, Thompson GE, Brown DL, Bodily MN. Bradycardia and asystole during spinal anesthesia: A report of three cases without morbidity. *Anesthesiology* 1989;70:866-8.
8. Pollard JB. Cardiac arrest during spinal anesthesia: Common mechanisms and strategies for prevention. *Anesth Analg* 2001;92:252-6.
9. Thrush DN, Downs JB. Vagotonia and cardiac arrest during spinal anesthesia. *Anesthesiology* 1999;91:1171-3.

How to cite this article: Keenan C, Wang AY, Balonov K, Kryzanski J. Postoperative vasovagal cardiac arrest after spinal anesthesia for lumbar spine surgery. *Surg Neurol Int* 2022;13:42.