



Case Report

Potential hemorrhagic risk of endovascular revascularization therapy due to recanalization of the dissected perforator in intracranial internal carotid artery dissection: A case report

Tomohisa Ishida¹, Hiroyuki Sakata¹, Masayuki Ezura¹, Takashi Inoue¹, Atsushi Saito¹, Hiroyoshi Suzuki², Teiji Tominaga³

Departments of ¹Neurosurgery, ²Pathology, National Hospital Organization Sendai Medical Center, Sendai, Miyagi, Japan, ³Department of Neurosurgery, Tohoku University Graduate School of Medicine, Sendai, Miyagi, Japan.

E-mail: Tomohisa Ishida - toishida@med.tohoku.ac.jp; *Hiroyuki Sakata - sakata@nsg.med.tohoku.ac.jp; Masayuki Ezura - ezuram@yahoo.co.jp; Takashi Inoue - tainoue-nsu@umin.ac.jp; Atsushi Saito - atsushi2002@yahoo.co.jp; Hiroyoshi Suzuki - hirozuzsnh@gmail.com; Teiji Tominaga - tomi@nsg.med.tohoku.ac.jp



***Corresponding author:**

Hiroyuki Sakata,
Department of Neurosurgery,
National Hospital Organization
Sendai Medical Center, Sendai,
Miyagi, Japan.

sakata@nsg.med.tohoku.ac.jp

Received : 17 September 2021

Accepted : 05 February 2022

Published : 25 February 2022

DOI

10.25259/SNI_938_2021

Quick Response Code:



ABSTRACT

Background: Intracranial internal carotid artery (ICA) dissection manifesting as ischemic stroke is rare. Although endovascular revascularization therapy is effective in preventing the progression of stroke, little is known about the potential risk of this therapeutic approach.

Case Description: We report a case of a 38-year-old woman who presented with acute ischemic infarcts in the territory of the left anterior choroidal artery (AChA) due to intracranial ICA dissection. She underwent balloon angioplasty, resulting in the complete resolution of the stenosis. The AChA, which was nearly occluded preoperatively, was unexpectedly recanalized after the procedure. Four hours later, she developed a parenchymal hemorrhage in the left basal ganglia without subarachnoid hemorrhage. The AChA, suspected as the hemorrhagic source during surgical hematoma removal, was revealed to have a disrupted internal elastic lamina on pathological examination, suggesting that the dissection of the ICA extended to the AChA.

Conclusion: To the best of our knowledge, this is the first case report demonstrating that the intracranial ICA dissection extends to the associated perforator. Considering the potential risk of subsequent hemorrhagic complications by recanalization of the dissected perforator, prudent postoperative management, including strict blood pressure control, is advisable following endovascular revascularization therapy against intracranial artery dissection involving perforators.

Keywords: Dissected perforator, Endovascular therapy, Hemorrhagic complication, Intracranial internal carotid artery dissection

INTRODUCTION

Intracranial artery dissection is a rare entity, occurring in 3.6–4.4 per 100,000 people per year.^[4] Dissection in the anterior circulation is less common than in the posterior circulation in adults, and mainly occur in the supraclinoid internal carotid artery (ICA).^[4] Intracranial ICA dissection typically presents as severe headache, immediately followed by neurological symptoms of cerebral

ischemia or subarachnoid hemorrhage.^[3] Intracranial ICA dissection is a possible cause of ischemic stroke especially in young patients; however, guidelines for medical or surgical management have not yet been established.^[3,13,15]

Endovascular revascularization therapy has been reported to effectively counteract intracranial ICA dissection manifesting as ischemic stroke.^[8-10,15] Angioplasty using a balloon catheter as well as stent placement enables alleviation of hemodynamic ischemic symptoms by recanalizing the antegrade blood flow of the ICA.^[1] Endovascular therapy has been described to be efficient even in patients with progressive symptoms.^[1] However, as there have been no reports of complications, little is known about the potential risk of this therapeutic approach.

Here, we report a case of intracranial ICA dissection with ischemic onset, with a complication of remote parenchymal hemorrhage due to a recanalized dissected perforator following endovascular therapy. We also sought to elucidate the mechanism underlying postoperative hemorrhagic complications and suggest a treatment strategy from both angiographic and pathological points of view.

CASE DESCRIPTION

A 38-year-old woman with no medical history presented with progressive hemiparesis on the right side and total aphasia following a sudden headache. Magnetic resonance imaging revealed acute ischemic infarcts in the territory of the left anterior choroidal artery (AChA) [Figure 1]. Digital subtraction angiography showed severe stenosis of the left supraclinoid ICA, restricting blood flow beyond the lesion [Figure 2a]. Cone-beam computed tomography revealed an intimal flap at the lesion site [Figure 2b]. The lesion extended to the proximal middle cerebral artery, including the ostium of the AChA, which was angiographically opacified [Figure 2c]. Based on her clinical course and angiographic findings, the patient was diagnosed with idiopathic intracranial ICA dissection. As cerebral hypoperfusion due to severe stenosis was prominent and the infarcted lesion

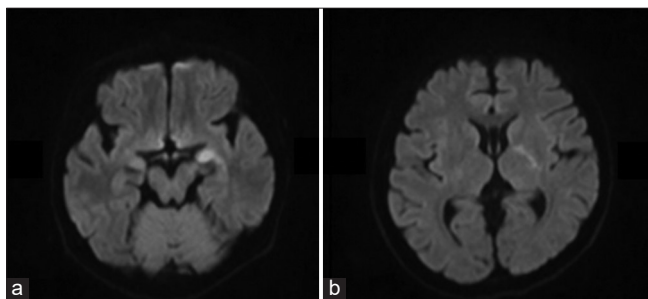


Figure 1: Initial diffusion-weighted magnetic resonance imaging showing acute ischemic infarcts in the territory of the left anterior choroidal artery.

was small relative to the clinical symptoms, we decided to perform endovascular revascularization therapy under local anesthesia.

We planned to perform percutaneous transluminal angioplasty (PTA) using a balloon dilatation catheter, with or without stent placement, depending on the PTA results. The patient received oral antiplatelet drugs with loading doses (aspirin 200 mg and clopidogrel 300 mg), together with intravenous heparin during the procedure to maintain the activated coagulation time in the range of 250–300 s. An 8-Fr occlusion balloon-guiding catheter (Cello; Medtronic, Minneapolis, MN, USA) was navigated to the left cervical ICA using a transfemoral approach. After a Gateway Monorail 2.5 × 12 mm (Stryker, Kalamazoo, MI, USA) was introduced into the lesion, the balloon was inflated by increasing the pressure to 6 atm for approximately 60 s [Figure 2d], which resulted in a complete resolution of the stenosis. The AChA, which was nearly occluded preoperatively, was unexpectedly recanalized after the procedure. Since the dissected lesion was not recoiled for more than 15 min [Figure 2e], the procedure was ended without stent placement.

The patient's ischemic symptoms improved dramatically soon after the procedure; however, her consciousness level suddenly declined 4 h later. An emergency computed

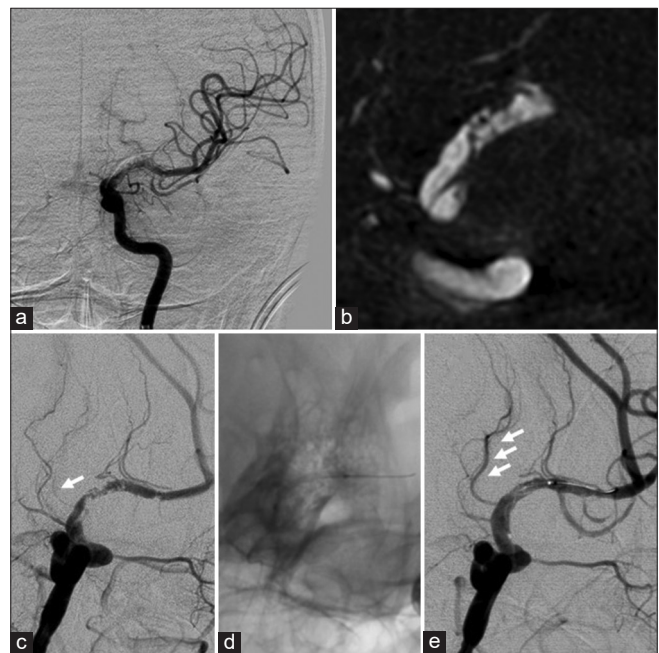


Figure 2: (a) Preoperative angiography revealing irregular stenosis of the left supraclinoid internal carotid artery (ICA). (b) Cone-beam computed tomography demonstrating the intimal flap at the lesion site. (c) Preoperative working angle. Note that the anterior choroidal artery (AChA) is nearly occluded (arrow). (d) Balloon angioplasty performed. (e) Postoperative working angle showing the resolution of the ICA stenosis and the complete recanalization of AChA (arrow).

tomography revealed a parenchymal hemorrhage in the left basal ganglia without any evidence of subarachnoid hemorrhage [Figures 3a and b], indicating that the hemorrhagic complication was not due to a perforation or rupture of the dissected ICA. We decided to perform surgical evacuation of the hematomas by craniotomy. Intraoperative findings revealed that the AChA, which was running deep in the hematoma cavity, was surrounded by a fibrin cap, indicating that the AChA was a hemorrhagic source. Pathological examination of the resected AChA revealed a disrupted internal elastic lamina, suggesting that the dissection of the ICA extended to the AChA [Figures 3c and d]. The patient had persistent hemiparesis and motor aphasia postoperatively and was transferred to a rehabilitation hospital (modified Rankin Scale 4).

DISCUSSION

Although the natural history of ischemic stroke due to intracranial ICA dissection has not been studied in greater detail than that of other types of steno-occlusive lesions, ICA dissection is reportedly associated with a high rate of recurrent ischemic events.^[2] Clinical outcomes differ among cases because of their diverse pathology.^[9,12] There are three main pathologies of ischemic stroke caused by intracranial

ICA dissection. First is cerebral hypoperfusion, which occurs when the dissected artery is stenosed or occluded by an intramural hematoma. Second is distal embolization, which occurs when a clot builds is formed in the false lumen as the false lumen usually has a slower flow than the true lumen. Third is perforator infarction, which occurs when a perforating artery arises from the parent vessel and its ostium is obstructed by an intramural hematoma.^[2] Among them, cerebral hypoperfusion is associated with poor outcomes.^[9] In such cases, endovascular revascularization therapy, such as balloon angioplasty or stent placement, is reported to be effective and can secure antegrade blood flow. In the present case, the patient exhibited progressive neurological signs due to both cerebral hypoperfusion and perforator infarct. Emergent balloon angioplasty was performed to counteract cerebral hypoperfusion, which dramatically improved both cerebral perfusion and neurological symptoms.

The most interesting finding in the present case is that the resected AChA, which is probably responsible for the hemorrhagic complication, showed evidence of dissection, which was confirmed by pathological examination. Dissection in a perforator has been reported previously as the cause of parenchymal hemorrhage.^[16] A dissecting aneurysm in a lenticulostriate artery has been demonstrated histologically.^[11] Since in the present case, radiography and pathology examinations revealed intracranial ICA dissection and AChA dissection, respectively, it is reasonable that the intracranial ICA dissection extended to the AChA. To the best of our knowledge, this is the first case report of a dissection involving a large vessel intruding the associated perforator. Therefore, we should consider a potential dissection extending to the perforators in cases of intracranial ICA dissection.

Another possible underlying mechanism is reperfusion injury. Endovascular recanalization therapy for steno-occlusive lesions has a potential risk of hemorrhagic complications (3.1%).^[10] Although most cases are caused by manipulations such as vascular perforation (0.9%) and vessel rupture (0.8%), hemorrhage induced by hyperperfusion syndrome has been reported to be as low as 0.2%.^[6] In the present case, the nearly occluded AChA was incidentally recanalized after the procedure, suggesting the involvement of hyperperfusion syndrome in the process of hemorrhagic transformation. In accordance with our findings, hyperperfusion of the basal ganglia is associated with subsequent hemorrhage after endovascular recanalization in patients with ischemic stroke.^[14] While the pathophysiology of reperfusion hemorrhage is not completely understood, a key feature is believed to be related to brain-blood barrier (BBB) breakdown.^[5] Ischemia and subsequent reperfusion generate hyperemia, oxidative stress, and inflammation, leading to BBB disruption, which results

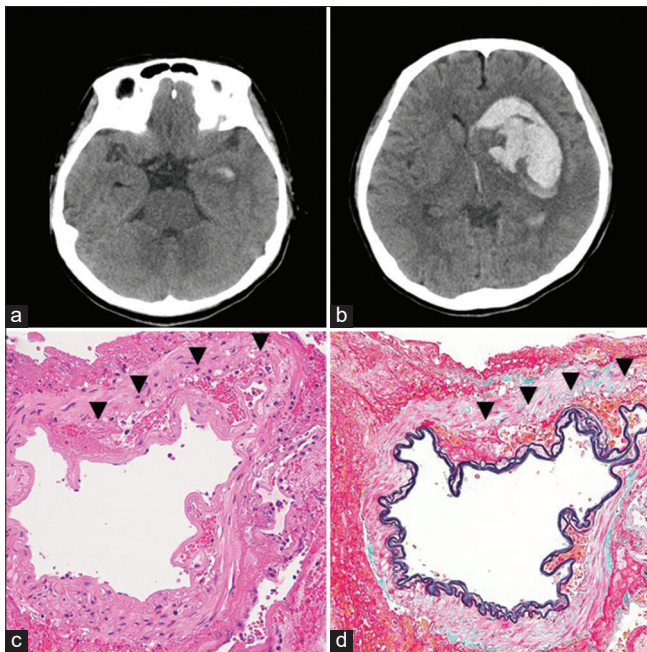


Figure 3: (a and b) Computed tomography obtained after patient deterioration, showing the intraparenchymal hemorrhage in the left basal ganglia without any evidence of subarachnoid hemorrhage. (c and d) Pathological examination of the resected anterior choroidal artery by hematoxylin and eosin staining (c) and elastic Masson staining (d). Note that the internal elastic lamina is disrupted and the red blood cells are present in the subintimal planes (arrowhead).

in hemorrhagic transformation.^[7] Since the basal ganglia, which is generally perfused with perforators, receives less collateral blood flow than cortical regions, it may be more susceptible to reperfusion injury.^[14] Based on these findings, both reperfusion injury and dissection-induced vessel wall fragility of the AChA can trigger in concert, resulting in hemorrhagic transformation. Therefore, if angiographical recanalization of perforators is observed after endovascular recanalization therapy, intensive postoperative management, including measures to lower the blood pressure, should be considered to prevent hemorrhagic complications.

CONCLUSION

This is the first case report demonstrating that the intracranial ICA dissection extends to the associated perforator. In cases of intracranial ICA dissection involving the perforator, occasional recanalization of the perforator may increase the risk of subsequent hemorrhagic complications following endovascular recanalization therapy. Prudent postoperative management, including blood pressure control, should be advised considering the potential hemorrhagic risk due to recanalized perforators.

Declaration of patient consent

The authors certify that they have obtained all appropriate patient consent.

Financial support and sponsorship

We are supported from JSPS KAKENHI (Grant Number P19K18414). No other financial support is received.

Conflicts of interest

There are no conflicts of interest.

REFERENCES

- Ahn JY, Chung SS, Lee BH, Kim SH, Yoon PH, Joo JY, *et al.* Treatment of spontaneous arterial dissections with stent placement for preservation of the parent artery. *Acta Neurochirurg* 2005;147:265-73.
- Bond KM, Krings T, Lanzino G, Brinjikji W. Intracranial dissections: A pictorial review of pathophysiology, imaging features, and natural history. *J Neuroradiol* 2021;48:176-88.
- Chaves C, Estol C, Esnaola MM, Gorson K, O'Donoghue M, De Witt LD, *et al.* Spontaneous intracranial internal carotid artery dissection: report of 10 patients. *Arch Neurol* 2002;59:977-81.
- Debette S, Compter A, Labeyrie MA, Uyttenboogaart M, Metso TM, Majersik JJ, *et al.* Epidemiology, pathophysiology, diagnosis, and management of intracranial artery dissection. *Lancet Neurol* 2015;14:640-54.
- Hayakawa M. Reperfusion-related intracerebral hemorrhage. *Front Neurol Neurosci* 2015;37:62-77.
- Izumi T, Nishibori M, Imamura H, Iihara K, Sakai N, investigators JN. Endovascular therapy for intracranial artery stenosis: Results from the Japanese registry of neuroendovascular therapy (JR-NET)3. *Neurol Med Chirurg* 2020;60:256-63.
- Khatir R, McKinney AM, Swenson B, Janardhan V. Blood-brain barrier, reperfusion injury, and hemorrhagic transformation in acute ischemic stroke. *Neurology* 2012;79:S52-7.
- Kim DJ, Kim BM, Suh SH, Kim DI. Self-expanding stent placement for anterior circulation intracranial artery dissection presenting with ischemic symptoms. *Neurosurgery* 2015;76:158-64.
- Kondo R, Matsumoto Y, Suzuki I, Kikuschi T, Shimizu H, Fujiwara S, *et al.* Stent placement for intracranial internal carotid artery dissection presenting with ischemic stroke. *JNET* 2012;6:164-74.
- Lylyk P, Cohen JE, Ceratto R, Ferrario A, Miranda C. Angioplasty and stent placement in intracranial atherosclerotic stenoses and dissections. *AJNR Am J Neuroradiol* 2002;23:430-6.
- Mizutani T, Kojima H, Miki Y. Arterial dissections of penetrating cerebral arteries causing hypertension-induced cerebral hemorrhage. *J Neurosurg* 2000;93:859-62.
- Oka F, Shimizu H, Matsumoto Y, Watanabe M, Tominaga T. Ischemic stroke due to dissection of intracranial internal carotid artery: Implications for early surgical treatment. *Surg Neurol* 2008;69:578-84.
- Rao AS, Makaroun MS, Marone LK, Cho JS, Rhee R, Chaer RA. Long-term outcomes of internal carotid artery dissection. *J Vasc Surg* 2011;54:370-4.
- Shahi V, Fugate JE, Kallmes DF, Rabinstein AA. Early basal ganglia hyperperfusion on CT perfusion in acute ischemic stroke: A marker of irreversible damage? *AJNR Am J Neuroradiol* 2014;35:1688-92.
- Shindo A, Matsumoto A, Shishido H, Okauchi M, Hayashi N, Kawakita K, *et al.* Two cases of intracranial internal carotid artery dissection presenting with ischemic stroke. *J Neuroendovasc Ther* 2017;11:253-9.
- Yap L, Patankar T, Pysden K, Tyagi A, Goddard T. Spontaneous dissecting lenticulostriate artery aneurysm in children: Radiologic findings and clinical management. *J Child Neurol* 2015;30:1060-4.

How to cite this article: Ishida T, Sakata H, Ezura M, Inoue T, Saito A, Suzuki H, *et al.* Potential hemorrhagic risk of endovascular revascularization therapy due to recanalization of the dissected perforator in intracranial internal carotid artery dissection: A case report. *Surg Neurol Int* 2022;13:71.