



## Case Report

# Cerebral sinus thrombosis as an initial symptom of acute promyelocytic leukemia: Case report and literature review

Laura Salgado-Lopez<sup>1</sup>, Amanda Custozzo<sup>2</sup>, Nataly Raviv<sup>2</sup>, Tamer Abdelhak<sup>3</sup>, Maria Peris-Celda<sup>4</sup>

<sup>1</sup>Department of Neurosurgery, Mount Sinai Hospital, New York City, Departments of <sup>2</sup>Neurosurgery and <sup>3</sup>Neurology, Albany Medical Center, Albany, New York, <sup>4</sup>Department of Neurologic Surgery, Mayo Clinic, Rochester, Minnesota, United States.

E-mail: \*Laura Salgado-Lopez - laura.salgadolopez@mountsinai.org; Amanda Custozzo - custoza@amc.edu; Nataly Raviv - nataly.raviv@gmail.com; Tamer Abdelhak - abdelht@amc.edu; Maria Peris-Celda - periscelda.maria@mayo.edu



### \*Corresponding author:

Laura Salgado-Lopez,  
Department of Neurosurgery,  
Mount Sinai Hospital,  
New York City, New York,  
United States.

[laura.salgadolopez@mountsinai.org](mailto:laura.salgadolopez@mountsinai.org)

Received : 22 September 2021

Accepted : 17 February 2022

Published : 11 March 2022

### DOI

10.25259/SNI\_958\_2021

### Quick Response Code:



## ABSTRACT

**Background:** Cerebral sinus thrombosis as presentation of acute promyelocytic leukemia (AMPL) is exceptional, with only three cases registered in the literature.

**Case Description:** A 24-year-old female patient was transferred to our center after a car accident. The patient had a witnessed generalized seizure while driving. Computerized tomography (CT) demonstrated a temporal intraparenchymal hemorrhage and CT venogram diagnosed a cerebral sinus thrombosis on the left transverse and sigmoid sinus. The patient underwent surgical evacuation of the hematoma and was treated with anticoagulation 48 h after surgery. Pancytopenia alerted of a possible hematological disorder. The patient was subsequently diagnosed with AMPL and treated with arsenic trioxide. The patient had a complete neurological recovery with no postoperative complications.

**Conclusion:** The management of cerebral sinus thrombosis in patients with AMPL remains controversial. The previous reported cases of cerebral sinus thrombosis preceding the diagnosis of AMPL are reviewed and treatment of cerebral sinus thrombosis with anticoagulation in the setting of intraparenchymal hemorrhage and bleeding disorders is also discussed.

**Keywords:** Acute promyelocytic leukemia, Cerebral sinus thrombosis, Intraparenchymal hemorrhage, Seizure

## INTRODUCTION

Cerebral sinus venous thrombosis (CVT) is a rare but potentially devastating type of stroke, accounting for approximately 0.5% of them.<sup>[2]</sup> CVT affects predominantly young people and it can be challenging to diagnose as headache, rather than focal neurologic symptoms, is the prominent feature.<sup>[16]</sup> In addition to its high variability of clinical manifestations, CVT still lacks a clear therapeutic consensus.<sup>[3]</sup> When CVT is associated with an intraparenchymal hemorrhage, especially if the hemorrhage requires surgical evacuation, or a coagulation disorder that leads to bleeding, such as acute promyelocytic leukemia (APML), the use of therapeutic anticoagulation is subject to further controversy.

This is an open-access article distributed under the terms of the Creative Commons Attribution-Non Commercial-Share Alike 4.0 License, which allows others to remix, transform, and build upon the work non-commercially, as long as the author is credited and the new creations are licensed under the identical terms.

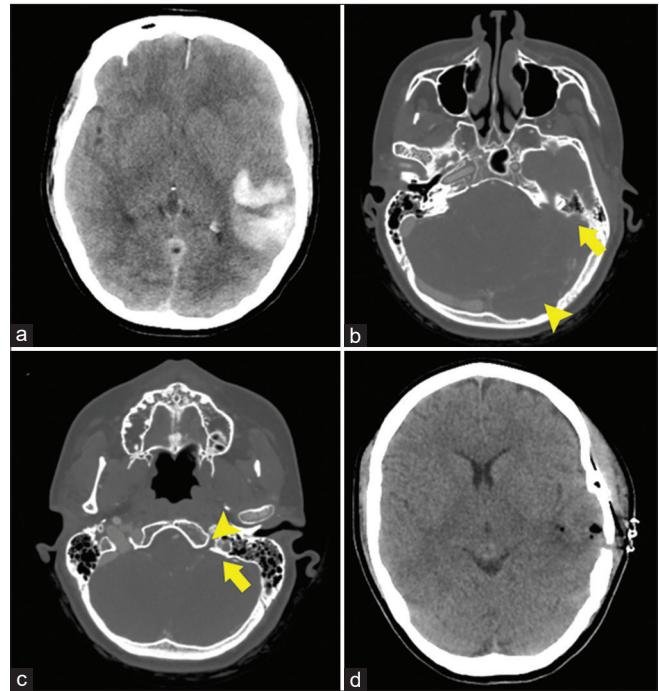
©2022 Published by Scientific Scholar on behalf of Surgical Neurology International

While bleeding is a characteristic feature of APML, reports of CVT in the setting of APML remain exceptional. Within them, CVT usually occurs during the induction treatment with all-trans retinoic acid, or later in the course of the disease.<sup>[11]</sup> The occurrence of CVT before the diagnosis of APML is extremely rare, with just three cases registered in the literature.<sup>[1,10,13]</sup>

## CASE REPORT

A 24-year-old female was admitted to the emergency room after a motor vehicle accident caused by a witnessed generalized seizure while driving. An initial computerized tomography (CT) scan of the head showed a left temporal intraparenchymal hemorrhage [Figure 1a], thus the patient was started on levetiracetam and transferred to our hospital. Her Glasgow coma scale was ten on arrival to our center (E3 V2 M5). A second CT scan of the head was performed revealing an increase in the size of the intraparenchymal hemorrhage and adjacent mass effect, with 6 mm of midline shift. A cranial CT angiography showed thrombosis of the left transverse and sigmoid sinuses extending into the internal jugular vein [Figure 1b and c]. Her only additional injury was a left ankle fracture requiring conservative treatment. The patient was taking oral contraceptives and did not have a personal or family history of known bleeding or clotting disorders. Her social and medical history was unremarkable. The patient underwent emergent left craniotomy with evacuation of the temporal intraparenchymal hemorrhage and placement of a subdural intracranial pressure monitor. Postoperatively, she was admitted to the ICU, presenting a 4+/5 paresis in the right upper limb and mild motor dysphasia after anesthetic wean that recovered completely the following days. A postoperative CT scan showed resolution of the midline shift and an appropriate evacuation of the temporal hemorrhage [Figure 1d]. A low-dose heparin drip was initiated to treat the cerebral venous thrombosis 48 h after the surgery and transitioned to full dose the following day.

The patient's initial blood test revealed pancytopenia that worsened over the 1<sup>st</sup> days: the initial white blood cell count was  $2 \times 10^9/l$ , with a red blood cell count of  $3.43 \times 10^9/l$ , platelets of  $13 \times 10^9/l$ , and a hemoglobin count at 10.6 g/dl; blood test results 2 days after admission showed a white blood cell count of  $1.7 \times 10^9/l$ , a red blood cell count of  $2.14 \times 10^9/l$ , platelets of  $10 \times 10^9/l$ , and a hemoglobin count at 6.7 g/dl, therefore, the patient received one unit of red blood cells. A peripheral smear displayed features suggestive of APML. Initial testing for Factor V Liden, prothrombin gene mutation, hepatitis C panel, HIV, antinuclear Ab, anticardiolipin IgG/IgM/IgA, beta-2glycoprotein G/M/IgA, MTHFR, and JAK2 V617F was all negative. A bone marrow biopsy was performed on the 4<sup>th</sup> postoperative day.



**Figure 1:** Case illustration. (a) Preoperative CT scan of the head performed on arrival to our center demonstrating a left intraparenchymal hemorrhage of  $47 \times 31 \times 60$  mm, with mass effect on adjacent brain structures and a midline shift of 6 mm. (b) Preoperative cranial CT angiography, venous phase, showing right transverse and sigmoid sinuses patency and occlusion of the left transverse (arrowhead) and sigmoid (arrow) sinuses. (c) Preoperative cranial CT angiography, venous phase, showing right sigmoid sinus and jugular vein patency and occlusion of the sigmoid sinus (arrow) and jugular vein (arrowhead) on the left side. (d) Postoperative CT scan performed 24 h after the surgical procedure showing resolution of the midline shift and evacuation of the temporal hemorrhage through a left craniotomy with minimal amount of pneumocephalus.

The fluorescence *in situ* hybridization analysis of the bone marrow sample revealed dual fusion signals in the 15;17 probe set, indicating PML/RARA fusion and confirming the diagnosis of APML. The treatment with arsenic trioxide was consequently started, and the heparin drip was switched to subcutaneous low-molecular-weight heparin (LMWH) at a therapeutic dose 2 weeks after the surgery. She experienced a progressive neurological recovery with complete resolution of the motor dysphasia and right upper limb paresis, and is currently completing the antineoplastic treatment with good response.

## DISCUSSION

CVT is an uncommon and frequently unrecognized type of stroke. Clinical findings are usually either related to increased intracranial pressure due to impaired venous drainage or to focal brain injury from venous ischemia or

hemorrhage.<sup>[16]</sup> Headache is the most common symptom and it can be present in nearly 90% of patients.<sup>[9]</sup> Focal neurological symptoms may occur in up to 50% of cases and depend on the location of the thrombosis, being hemiparesis and aphasia the most common ones. Focal or generalized seizures are also experienced by approximately 40% of patients. Altogether, symptoms of CVT are often slowly progressive and in consequence delays in diagnosis are frequent and significant.<sup>[9]</sup>

Predisposing factors of CVT are multiple and can be identified in up to 80% of patients.<sup>[16]</sup> Evaluation of underlying causes is, therefore, a crucial aspect of the CVT management that will often also influence the anticoagulation length and the overall treatment. The use of oral contraceptives has been associated with an increased risk of CVT.<sup>[8]</sup> The combination of oral contraceptives with a prothrombotic condition also increases the risk.<sup>[16]</sup> In our case, the CVT was initially attributed to the use of oral contraceptives, reflecting the importance of performing a thorough diagnostic workout to rule out other coexisting infrequent conditions, especially consumption coagulopathies and fibrinolytic states that can also lead to bleeding, as demonstrated in this case with APML.

APML is a distinct subtype of acute myeloid leukemia, with symptoms usually related to the characteristic underlying pancytopenia, such as fatigue, infections, and bleeding. Hence, intracranial events are usually hemorrhagic rather than thrombotic.<sup>[14]</sup> CVT as a complication of APML is extremely rare, and it has been usually described later in the course of the disease and during the induction therapy with all-trans retinoic acid, the gold-standard treatment before the introduction of arsenic trioxide.<sup>[4,5,11]</sup> Patients who experience the constellation of symptoms known as differentiation syndrome, normally occurring between the 2<sup>nd</sup> day and 3<sup>rd</sup> week of induction therapy, seem particularly prone to develop thrombotic events.<sup>[7,18]</sup> Several hypotheses regarding the procoagulant mechanism of all-trans retinoic acid have been postulated, as thromboembolic phenomena were not characteristic of APML before the all-trans retinoic acid era.<sup>[11,18]</sup> To the best of our knowledge, this is the fourth case of CVT as initial manifestation of APML reported in the literature<sup>[1,10,13]</sup> [Table 1].

MR imaging in combination with MR venography has largely replaced invasive cerebral angiography in the diagnosis of CVT and is usually considered the technique of choice for diagnostic evaluation and follow-up. However, CT scan imaging is preferred over MR to assess patients with suspected intracranial hemorrhage and cerebral CT venography has proven to be equivalent to MR venography in the diagnosis of CVT.<sup>[12]</sup>

The treatment of CVT still lacks an uniform approach.<sup>[16]</sup> The antithrombotic treatment modalities include heparin,

oral anticoagulants, and thrombolysis. The use of mechanical thrombolytic techniques is only supported by small case series and reserved for patients with clinical deterioration despite use of anticoagulation.<sup>[16]</sup> The mainstay of acute management is anticoagulation with either unfractionated heparin in adjusted doses or LMWH, with no data supporting differences in outcome in CVT cases.<sup>[9]</sup> Approximately 30% of patients with CVT present with an intracranial hemorrhage, usually secondary to venous hypertension caused by the thrombosis. These intracranial hemorrhages can range from small juxtacortical hemorrhages to large space-occupying lesions, in which case anticoagulation can be controversial, especially if the hemorrhages require surgical evacuation, with the timing to start anticoagulation after the surgical procedure adding a further level of complexity.<sup>[16]</sup> However, the results of small placebo controlled studies suggest that anticoagulation is safe in CVT with intracerebral hemorrhage, and it can even decrease the mortality rate of these patients.<sup>[6,17]</sup> When dealing with these cases, risk and benefits of anticoagulation must be balanced.

The management of a stroke or major thrombosis in APML remains challenging, given that intracerebral and pulmonary hemorrhages are the most frequent causes of death due to the complex coagulopathy associated with APML.<sup>[15]</sup> The use of unfractionated heparin or LMWH can be considered in severe thrombosis, although the risk of hemorrhagic complications warrants substantial caution.<sup>[15]</sup> In our case, a low-dose heparin drip with transition to full dose heparin drip was started in the acute setting postoperatively and switched to subcutaneous LMWH at therapeutic doses 2 weeks after surgery. Conversely, one of the previous reported cases of CVT in patients with undiagnosed APML underwent initial anticoagulation with subcutaneous LMWH, having a good neurological and oncological outcome.<sup>[13]</sup> The other two previous reported cases underwent initial anticoagulation with intravenous unfractionated heparin.<sup>[1,10]</sup> One case developed a cerebellar hemorrhage 24 h after heparin was started, although the authors attributed at least a component of the hematoma to hemorrhagic venous infarction based on dilated veins depicted in the MR imaging.<sup>[1]</sup> The anticoagulation was discontinued for 5 days in addition to administration of fresh frozen plasma, and the patient was discharged home on LMWH. After 9 days, the patient was readmitted due to increased intracranial pressure and cerebellar hemorrhage size. The anticoagulation was discontinued again and a ventriculoperitoneal shunt was placed. LMWH was reintroduced 48 h later, when the patient developed new-onset ischemic strokes in the occipital lobe due to intracardiac thrombus.<sup>[1]</sup> The other case reported in the literature became comatose and died shortly after diagnosis.<sup>[10]</sup> These previous cases highlight the complexity of treating CVT in the setting of coagulation disorders as APML. While our patient's condition improved following surgery and anticoagulation treatment, the management of CVT in

**Table 1:** Cerebral sinus thrombosis as an initial symptom of acute promyelocytic leukemia reported in the literature.

Author	Age (years)	Sex	Location	Intraparenchymal hemorrhage	Symptoms	CVT Treatment	Follow up
Hazani <i>et al.</i> (1988) <sup>[10]</sup>	11	Male	Superior sagittals.	None	IH (headache, papilledema, sudden blindness)	IV UFH	Rapid progression to coma, death.
Beslow <i>et al.</i> (2009) <sup>[11]</sup>	12	Male	Superior sagittal s., straight s., bilateral transverse s.	Left cerebellum (after starting heparin)	IH (headache, papilledema, emesis, diplopia)	IV UFH SC LMWH at discharge	Readmission 9 days after discharge with worsening IH and cerebellum hemorrhage: Unsuccessful interventional thrombectomy attempt + Ventriculoperitoneal shunt + APML diagnosis + induction chemotherapy. Good neurological evolution.
Paxton <i>et al.</i> (2021) <sup>[13]</sup>	33	Female	Bilateral transverse s., bilateral sigmoid s.	None	IH (papilledema, lumbar puncture opening pressure of 42 cm of water)	SC LMWH	Induction chemotherapy well tolerated with morphological remission showed in the bone marrow biopsy after 1 month (followed by 2 rounds of consolidation treatment). Good neurological evolution.

IH: Intracranial hypertension, IV: Intravenous, S: Sinus, SC: Subcutaneous, UFH: Unfractionated heparin, CVT: Cerebral sinus venous thrombosis

patients with APML remains controversial and would benefit from a multidisciplinary discussion and the development of an evidence-based approach.

## CONCLUSION

Management of cerebral sinus thrombosis in patients with acute promyelocytic leukemia remains controversial. Previous reported cases of cerebral sinus thrombosis preceding the diagnosis of acute promyelocytic leukemia are reviewed, and treatment of cerebral sinus thrombosis with anticoagulation in the setting of intraparenchymal hemorrhage and bleeding disorders are also discussed.

## Ethical approval

All aspects of this study were approved by the Institutional Review Board of the Albany Medical Center, Albany, NY.

## Declaration of patient consent

Patient's consent not required as patients identity is not disclosed or compromised.

## Financial support and sponsorship

Nil.

## Conflicts of interest

There are no conflicts of interest.

## REFERENCES

- Beslow LA, Abend NS, Smith SE. Cerebral sinus venous thrombosis complicated by cerebellar hemorrhage in a child with acute promyelocytic leukemia. *J Child Neurol* 2009;24:110-4.
- Boussier MG, Ferro JM. Cerebral venous thrombosis: An update. *Lancet Neurol* 2007;6:162-70.
- Bushnell C, Saposnik G. Evaluation and management of cerebral venous thrombosis. *Continuum (Minneapolis)* 2014;20:335-51.
- Ciccione M, Rigolin GM, Viglione GM, Borrelli M, Serino ML, Cuneo A. Thrombosis of the cerebral veins and sinuses in acute promyelocytic leukemia after all-trans retinoic acid treatment: A case report. *Blood Coagul Fibrinolysis* 2008;19:721-3.
- Dally N, Hoffman R, Haddad N, Sarig G, Rowe JM, Brenner B.

- Predictive factors of bleeding and thrombosis during induction therapy in acute promyelocytic leukemia—a single center experience in 34 patients. *Thromb Res* 2005;116:109-14.
6. de Bruijn SF, Stam J. Randomized, placebo-controlled trial of anticoagulant treatment with low-molecular-weight heparin for cerebral sinus thrombosis. *Stroke* 1999;30:484-8.
  7. De Stefano V, Sorà F, Rossi E, Chiusolo P, Laurenti L, Fianchi L, *et al.* The risk of thrombosis in patients with acute leukemia: Occurrence of thrombosis at diagnosis and during treatment. *J Thromb Haemost* 2005;3:1985-92.
  8. Dentali F, Crowther M, Ageno W. Thrombophilic abnormalities, oral contraceptives, and risk of cerebral vein thrombosis: A meta-analysis. *Blood* 2006;107:2766-73.
  9. Ferro JM, Canhão P, Stam J, Bousser MG, Barinagarrementeria F. Prognosis of cerebral vein and dural sinus thrombosis: Results of the international study on cerebral vein and dural sinus thrombosis (ISCVT). *Stroke* 2004;35:664-70.
  10. Hazani A, Weidenfeld Y, Tatarsky I, Bental E. Acute promyelocytic leukemia presenting as sudden blindness and sinus vein thrombosis. *Am J Hematol* 1988;28:56-7.
  11. Lee KR, Subrayan V, Win MM, Mohamad NF, Patel D. ATRA-induced cerebral sinus thrombosis. *J Thromb Thrombolysis* 2014;38:87-9.
  12. Ozsvath RR, Casey SO, Lustrin ES, Alberico RA, Hassankhani A, Patel M. Cerebral venography: Comparison of CT and MR projection venography. *AJR Am J Roentgenol* 1997;169:1699-707.
  13. Paxton AB, Micieli JA. Diagnosis of acute promyelocytic leukemia after presentation to neuro-ophthalmology. *J Neuroophthalmol* 2021 Aug 25. Doi: 10.1097/WNO.0000000000001259. Epub ahead of print
  14. Ryan MM. Acute promyelocytic leukemia: A summary. *J Adv Pract Oncol* 2018;9:178-87.
  15. Sanz MA, Fenaux P, Tallman MS, Estey EH, Löwenberg B, Naoe T, *et al.* Management of acute promyelocytic leukemia: Updated recommendations from an expert panel of the European LeukemiaNet. *Blood* 2019;133:1630-43.
  16. Saposnik G, Barinagarrementeria F, Brown RD Jr., Bushnell CD, Cucchiara B, Cushman M, *et al.* Diagnosis and management of cerebral venous thrombosis: A statement for healthcare professionals from the American heart association/American stroke association. *Stroke* 2011;42:1158-92.
  17. Shakibajhromi B, Borhani-Haghighi A, Ghaedian M, Feiz F, Vardanjani HM, Safari A, *et al.* Early, delayed, and expanded intracranial hemorrhage in cerebral venous thrombosis. *Acta Neurol Scand* 2019;140:435-42.
  18. Song LX, Lu HY, Chang CK, Li X, Zhang Z. Cerebral venous and sinus thrombosis in a patient with acute promyelocytic leukemia during all-trans retinoic acid induction treatment. *Blood Coagul Fibrinolysis* 2014;25:773-6.

**How to cite this article:** Salgado-Lopez L, Custozzo A, Raviv N, Abdelhak T, Peris-Celda M. Cerebral sinus thrombosis as an initial symptom of acute promyelocytic leukemia: Case report and literature review. *Surg Neurol Int* 2022;13:89.