

## Case Report

# Middle meningeal artery embolization before craniotomy for infected organizing chronic subdural hematoma: A case report and review of the literature

Mizuto Sato , Yoichi Mochizuki, Masahito Fukuchi, Koji Fujii

Department of Neurosurgery, Shizuoka City Shimizu Hospital, Shizuoka, Japan.

E-mail: \*Mizuto Sato - mizuto.sato@gmail.com; Yoichi Mochizuki - youichi19791214@yahoo.co.jp; Masahito Fukuchi - masafukuchi1598@gmail.com; Koji Fujii - unicornf@goo.jp



### \*Corresponding author:

Mizuto Sato,  
Department of Neurosurgery,  
Shizuoka City Shimizu  
Hospital, Shizuoka, Japan.  
mizuto.sato@gmail.com;

Received : 17 January 2022

Accepted : 07 April 2022

Published : 06 May 2022

### DOI

10.25259/SNI\_73\_2022

### Quick Response Code:



## ABSTRACT

**Background:** Organizing chronic subdural hematoma (OSDH) is intractable and its radical treatment remains controversial. Middle meningeal artery embolization has emerged as an adjunctive treatment to craniotomy for OSDH.

**Case Description:** The patient is an 86-year-old man. He had been taking warfarin for atrial fibrillation and was referred to the department for the treatment of bilateral chronic subdural hematoma (CSDH), which was found on head computed tomography after a fall. Bilateral burr hole drainages were performed, but his hematomas were organized, so the hematomas could not be drained sufficiently. The patient was discharged from the hospital without any neurological symptoms. Two months later, the patient presented with persistent fever and headache and had recurrent bilateral CSDHs. The hematoma on the right side was larger. Based on the initial intraoperative findings, OSDH was suspected, and craniotomy was performed on the right hematoma. *Propionibacterium acnes* were detected in the hematoma culture, and antimicrobial therapy was started postoperatively. Since the right hematoma recurred on the 7<sup>th</sup> postoperative day, bilateral middle meningeal artery (MMA) embolization with 20% n-butyl-2-cyanoacrylate was performed, followed by craniotomy for the left hematoma and drainage for the right recurrent hematoma. Antimicrobials were administered for 2 weeks after the last operations. Six months after the operations, both bilateral hematomas had almost disappeared.

**Conclusion:** Craniotomy is effective for the treatment of infected OSDH, and MMA embolization is useful to reduce the risk of bleeding complications in the perioperative period, and may also reduce the recurrence of CSDH.

**Keywords:** Chronic subdural hematoma, Middle meningeal artery embolization, Organizing subdural hematoma, *Propionibacterium acnes*

## INTRODUCTION

Chronic subdural hematoma (CSDH) is believed to be caused by disruption of the dural border cell layer in the dura mater due to minor head trauma, angiogenesis, and septal formation from hemorrhage, and resulting repeated microbleeding.<sup>[7]</sup>

The morbidity of CSDH is believed to increase with patient age, and an increasing number of patients take antithrombotic drugs, such as warfarin, DOACs, and antiplatelet drugs.<sup>[17]</sup>

This is an open-access article distributed under the terms of the Creative Commons Attribution-Non Commercial-Share Alike 4.0 License, which allows others to remix, transform, and build upon the work non-commercially, as long as the author is credited and the new creations are licensed under the identical terms.

©2022 Published by Scientific Scholar on behalf of Surgical Neurology International

Organizing chronic subdural hematoma (OSDH) is known as a variant of CSDH, which accounts for 0.5–2.0% of all CSDHs.<sup>[11]</sup> Its treatment remains controversial. The usefulness of craniotomy, small craniotomy, and endoscopic hematoma removal has all been reported.<sup>[3,4,6,14,15]</sup> Some reports recommend total removal of the inner membrane to prevent recurrence of hematoma,<sup>[2]</sup> while others suggest preservation of the inner membrane due to the risk of postoperative complications, such as acute subdural hematoma and epilepsy.<sup>[3]</sup>

Since the first report of MMA embolization as a treatment for CSDH in 2000,<sup>[13]</sup> its clinical usefulness has attracted much attention. In addition, there are few reports of MMA embolization being performed for OSDH. As embolization material, polyvinyl alcohol (PVA), PVA + coil, trisacryl gelatin microspheres, and n-butyl-2-cyanoacrylate (NBCA) have been used, and all of them have shown certain efficacy.<sup>[5,10,12,20]</sup>

## CASE DESCRIPTION

The patient was an 86-year-old man with a history of atrial fibrillation; he had been taking warfarin. The patient was referred to the department because bilateral CSDHs were found on the computed tomography (CT) scan, which was performed as an examination of his unsteadiness. The head CT showed bilateral convex lenticular hematomas with relatively high density but no calcification [Figure 1a]. The blood tests showed mild glucose intolerance with an HbA1c of 6.8%, but no other abnormalities were noted. Warfarin was stopped and bilateral perforator drainage was performed. The bilateral hematomas showed almost no leakage of fluid, even after incision of the hematoma outer membrane, and the operation was completed after cleaning the hematoma cavity as much as possible through perforation and placing a drainage tube in the hematoma cavity [Figure 1b]. A postoperative CT scan showed that most of the hematoma remained, although a little organizing hematoma had been removed. The patient's clinical symptoms improved and he was discharged home after restarting warfarin.

Two months after discharge from the hospital, the patient presented with a complaint of slight fever and headache that persisted for several days. The blood test performed at that time showed a mild elevation of serum C-reactive protein at 4.73 mg/dL. Although the CSDH had not increased significantly since the last time [Figure 1c], there was a compression of the brain parenchyma, so a craniotomy was proposed to remove the hematoma. The patient was admitted to the hospital for a detailed examination of his fever. Blood tests on admission showed leukocytes 5700, C-reactive protein 4.67 mg/dL, procalcitonin 0.03 ng/mL, and  $\beta$ D-glucan 9.0 pg/mL. Although there were no findings to actively suspect systemic bacterial infection, infection was not found

on the CT of the patient's body, and the reason for the elevated C-reactive protein was unknown. Magnetic resonance imaging (MRI) showed high signal in diffusion-weighted imaging around the outer membrane of both bilateral hematomas [Figure 1d], so the possibility of infectious OSDH was considered at this time, and craniotomy under general anesthesia was planned for the right-sided hematoma [Figure 1e], which had greater hematoma volume. Warfarin was replaced with heparin during the perioperative period.

The intraoperative findings showed that the dura was incised and a yellow hematoma outer membrane was evident. The hematoma was hard and organizing and was removed completely. The entire hematoma inner membrane was exposed. There were several areas of microscopic bleeding from the border between the outer and inner membrane, and the entire area was completely cauterized to hemostasis. Although an infectious hematoma was suspected, the inner membrane was preserved due to the fear of spreading the bacteria to the brain surface, and a risk of brain parenchymal damage. The hematoma was examined for culture, and *Propionibacterium acnes* were detected, leading to the diagnosis of infectious OSDH. The patient was treated with ampicillin/sulbactam from the postoperative period. Two weeks after surgery, a CT scan showed recurrence of the right hematoma [Figure 1f]. It was believed that if the left hematoma was also an infectious hematoma, a craniotomy would be necessary to reduce the number of bacteria, but in consideration of the recurrence of the right hematoma, it was decided to perform MMA embolization.

The MMA embolization revealed that the left external carotid artery imaging showed the vascular foci feeding the hematoma [Figure 2a: white arrows], mainly in the parietal region, and embolization with 20% NBCA was performed [Figure 2b: black arrows]. The right external carotid artery selective imaging showed no abnormal vessels reaching the hematoma due to the postoperative craniotomy [Figure 2c], but the remaining MMA branch was embolized with 20% NBCA [Figure 2d]. During the operation, the surgeons were careful to avoid dangerous anastomosis to recurrent meningeal artery.

The day after embolization, a craniotomy was performed for the left hematoma and drainage for the right hematoma under general anesthesia. The findings of the left craniotomy were the same as those of the right craniotomy: yellow outer membrane [Figure 3a], hard hematoma [Figure 3b], and complete exposure of the inner membrane after removal of hematoma [Figure 3c]. There was almost no microscopic bleeding from the inner membrane compared with the right side, probably due to the MMA embolization, so hemostasis was easy. Brown liquid hematoma was drained from the right recurrent hematoma. On this occasion, both the right and left side's hematomas were cultured too, but no bacteria

were detected. He was treated with intravenous ampicillin/sulbactam for 7 days postoperatively, followed by 1 week of oral amoxicillin. The patient was discharged with a postoperative course and is being followed up in an outpatient clinic. The course of imaging findings after surgery is shown in [Figure 4]. The CT scan just after surgery shows a drain tube inserted into the right hematoma cavity [Figure 4a]. We are taking CT scans of his head 1 week [Figure 4b], 1 month [Figure 4c], and six months after the surgery.

Six months after the surgery, the hematoma had almost disappeared on CT imaging [Figure 4d].

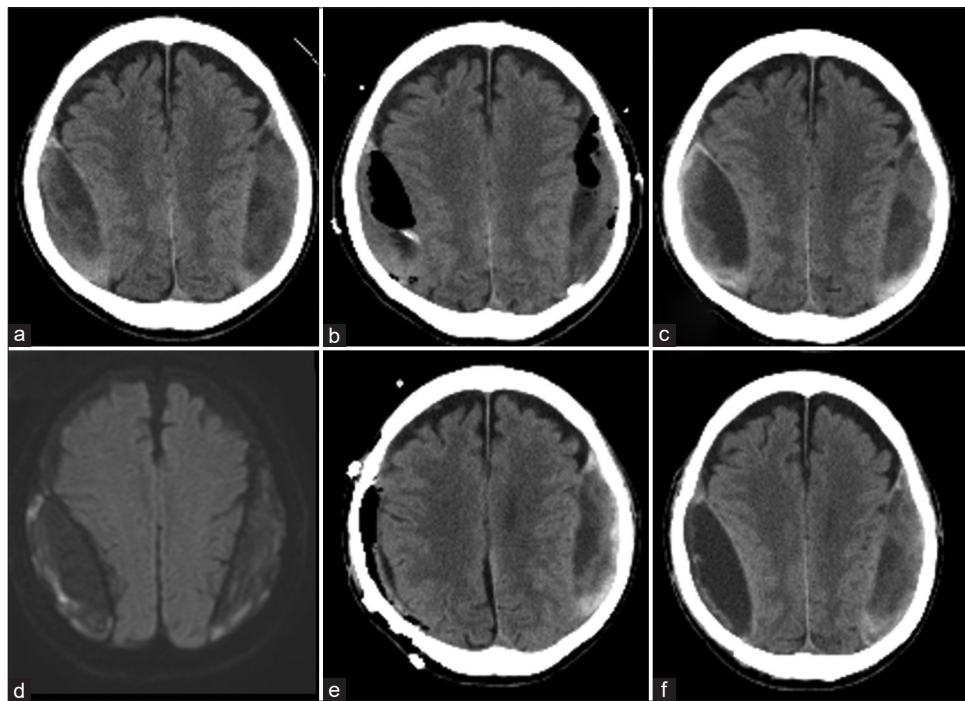
## DISCUSSION

CSDH is believed to be the result of the disruption of the dural border cell layer in the dura mater due to minor trauma, which leads to the formation of new blood vessels and septum within the hematoma.<sup>[7]</sup> In addition, due to the so-called CSDH cycle, inflammatory cells mobilized into the hematoma cavity attempt to repair the damage to the dural border cells and proliferate to form a new membrane.<sup>[7]</sup> Many of the inflammatory cells perform a pro-angiogenic role, which supports the development of new blood vessels in this subdural region. These vessels are “leaky” and promote microhemorrhage and leakage of spinal fluid into the new membrane connected subdural space.<sup>[8]</sup>

OSDH occurs in 0.5–2.0% of all CSDHs and is considered hard to treat radically.<sup>[11]</sup> It occurs when the hematoma has been present for a long period of time (6 months–1 year), and within the hematoma, there is a repeated bleeding due to the development of granulation tissue and the production of sinusoidal blood vessels at the inner and outer membrane borders of the hematoma. In addition, microenvironmental disturbances in the hematoma cavity due to circulatory disturbances and metabolic abnormalities caused by atherosclerosis, inflammation, and diabetes mellitus promote calcium deposition.<sup>[8]</sup>

Preoperative diagnosis of an OSDH is difficult and cannot be made on plain CT unless it is accompanied by calcification.<sup>[11]</sup> Several characteristic findings have been reported through MRI. T1-weighted images show a heterogeneous web-like appearance within the hematoma cavity, and diffusion-weighted images show hard coagulation with high signal and liquid hematoma with low signal. Contrast-enhanced MRI shows fragile vessels at the transition between the inner and outer membranes, and these capillaries are thought to be the source of hemorrhage in hematomas.<sup>[8]</sup>

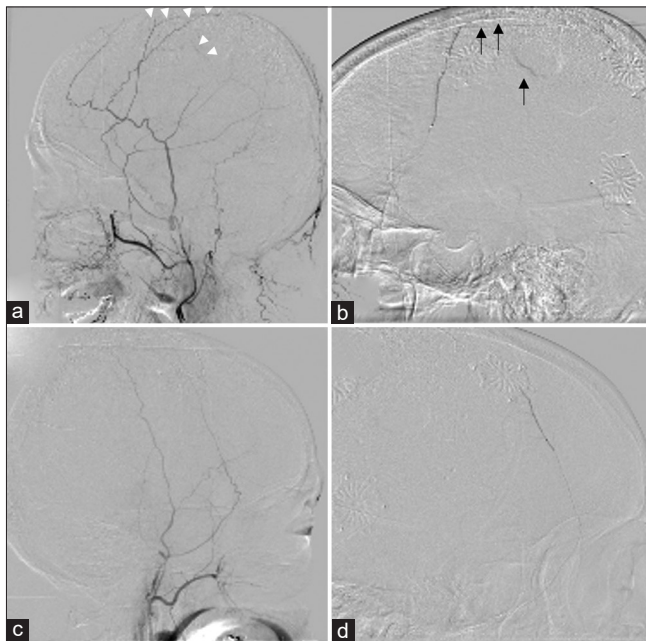
Morphologic changes in CSDH may suggest hematoma infection, especially in elderly patients, even when the results of blood tests and DWI findings are not typical for abscesses. Not only history, neurological examination, and blood tests



**Figure 1:** Imaging history of the patient before middle meningeal artery (MMA) embolization: the patient had bilateral biconvex lenticular hematoma (a). Bilateral burr hole irrigation was performed (b). Two months after his discharge, the hematoma was recurrent (c), and MRI showed high DWI image (d). After the craniotomy for the right hematoma (e), the right side hematoma recurred in 2 weeks (f).

but also radiological features, especially CT imaging, have been reported to show biconvex lenticular hematomas.<sup>[16]</sup>

As for cerebral angiographic findings, in selective imaging of the MMA, an abnormal network of punctate, mottled, and band-like vessels along the entire dilated and branched MMA can be seen mainly after the middle arterial phase. These are capillary-like vessels that exist in the hematoma outer membrane and it is thought that arterial pressure from the MMA disrupts these vessels, causing bleeding near the outer membrane. The diameter of these small arteries is reported to be as small as 50  $\mu\text{m}$ .<sup>[18]</sup>

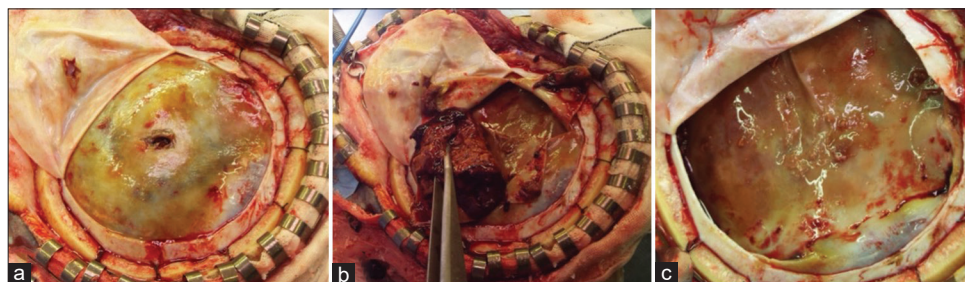

**Figure 2:** Middle meningeal artery (MMA) embolization was performed. The left external carotid artery imaging showed the vascular foci feeding the hematoma mainly in the parietal region (a: white arrows), and embolization with 20% n-butyl-2-cyanoacrylate (NBCA) was performed (b: black arrows). The right external carotid artery imaging showed no abnormal vessels reaching the hematoma due to the postoperative craniotomy (c), but the remaining MMA branch was embolized with 20% NBCA (d).

Although craniotomy may be considered preferable for the radical treatment of OSDHs, acute subdural hematoma complications after craniotomy have been reported in 6–12% of patients.<sup>[2,3]</sup> Since many patients with CSDHs are the elderly, craniotomy under general anesthesia may be avoided. As an alternative treatment, endoscopic removal of the hematoma by enlarging the perforating head or small craniotomy has been reported,<sup>[4,14,15]</sup> but as previously mentioned, the source of bleeding is fragile capillaries at the border between the outer and inner membranes, so radical treatment is difficult with these procedures. During craniotomy, it is controversial whether the inner membrane should be removed or preserved to prevent hematoma recurrence. If the inner membrane is removed, brain expansion can be predicted, but even in cases, where the inner membrane and arachnoid membrane are completely detached, postoperative epileptic complications are reported to be 25%.<sup>[2]</sup> Alternatively, preservation of the inner membrane remains a possibility of hematoma recurrence. To reduce the rate of recurrence in the case of craniotomy with preservation of the inner membrane, it is thought that MMA embolization is effective to reduce blood flow of inner membrane.

MMA embolization for CSDH was first reported in 2000,<sup>[13]</sup> and its efficacy has been reported in several case reports and case series.<sup>[9,19]</sup>

Anatomically, anastomosis of the MMA and ophthalmic artery through the recurrent meningeal artery is commonly recognized as dangerous anastomosis and requires attention during embolization. MMA embolization has been used for OSDH as well. As embolization material, PVA + coil, trisacryl gelatin microspheres (Embosphere®, Nihonkayaku, Tokyo, Japan), and NBCA have been used, and all of them have been reported to have some success [Table 1]. In the past, 250–350  $\mu\text{m}$  PVA and 300–500  $\mu\text{m}$  Embosphere® have also been found to be effective in preventing recurrence,<sup>[20]</sup> but since the diameter of capillary-like vessels in the hematoma membrane is reported to be 50  $\mu\text{m}$ ,<sup>[18]</sup> a liquid embolization material such as NBCA, which can easily reach the outer membrane of the hematoma, is also considered effective. If

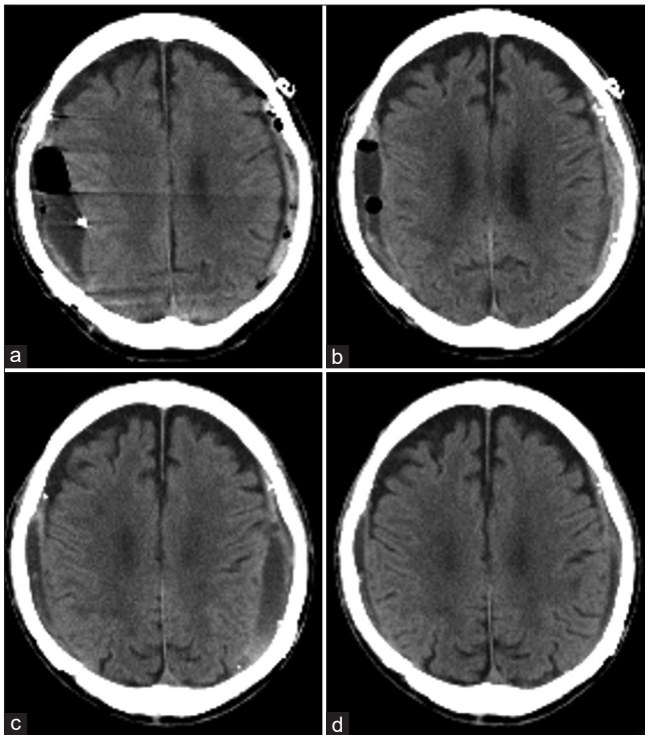


**Figure 3:** The day after embolization, we performed craniotomy for the left hematoma. The findings of the left craniotomy were the same as those of the right craniotomy. Yellow outer membrane (a), hard hematoma (b), and complete exposure of the inner membrane after removal of hematoma (c).

**Table 1:** Reports of MMA embolization for organizing chronic subdural hematoma.

Reports	No. of cases	Underlying disease	Anticoagulant drug	Embolic material	Concomitant surgery with embolization	Additional treatment after embolization	Recurrence	Remarks
Chihara et al. (2014)	1/3*	Alcoholic liver cirrhosis	None	PVA (250–300µm)+Coil	Drainage	Craniotomy	No	
Yamamoto et al. (2015)	1	None	None	NBCA	Drainage	Craniotomy+long-term drainage	No	Infected subdural hematoma
Hayashi et al. (2018)	3	Case 1: Hypertension Case 2: TAA**/ ACS*** Case 3: Hypertension	Case 1: None Case 2: Aspirin/ clopidogrel Case 3: None	Case 1: Collagen Case 2: NBCA (25%) Case 3: NBCA (17%)	Drainage	Craniotomy	No	
Yokoya et al. (2020)	2	Case 1: Diabetes mellitus Case 2: None	Case 1: None Case 2: None	Embospheres® (300–500 µm)+Coil	Drainage	Small craniotomy	No	
Kanazawa et al. (2021)	1	Cardiogenic brain embolism/atrial fibrillation	None	NBCA	Drainage	Craniotomy	No	Infected subdural hematoma
Present case	1	Atrial fibrillation	Warfarin	NBCA (20%)	Drainage	Craniotomy	No	Infected subdural hematoma

\*Of the three cases reported, one was an organizing chronic subdural hematoma, \*\*thoracic aortic aneurysm, \*\*\*acute coronary syndrome. NBCA: n-butyl-2-cyanoacrylate. Embospheres®: Trisacryl gelatin micro spheres [Nihonkayaku, Tokyo, Japan]



**Figure 4:** After the craniotomy for the left hematoma and drainage for the right hematoma (a), we followed computed tomography at postoperative day 7 (b), postoperative month 1 (c), and month 6 (d). Each side hematomas are almost disappeared.

the microcatheter can be guided to the appropriate location with attention to dangerous anastomosis, NBCA may be recommended as an embolic material.

In this case, the patient was taking warfarin for atrial fibrillation, and there was concern about postoperative bleeding during craniotomy. The biconvex lenticular hematomas and the high diffusion-weighted imaging signal suggested the possibility of infectious CSDH. It was thought that craniotomy was necessary to reduce the number of bacteria. Although there is no clear consensus on the radical treatment of infectious CSDH, early craniotomy is recommended for bacterial debulking.<sup>[6]</sup> The duration of postoperative antimicrobial therapy is also unclear, but in this case, the patient progressed well after a total of 2 weeks of antimicrobial therapy. Preoperative MMA embolization may reduce intraoperative bleeding and the risk of postoperative bleeding complications. Furthermore, recurrence of CSDH can be prevented, and the combined use of MMA embolization before craniotomy is believed to be very efficient for patients with a high risk of bleeding, such as in this case.

## CONCLUSION

As a treatment for organic chronic subdural hematoma, MMA embolization may avoid bleeding complications during and after craniotomy, as well as prevent recurrence of chronic subdural hematoma.

## Acknowledgment

The authors would like to thank Enago ([www.enago.jp](http://www.enago.jp)) for the English language review.

## Declaration of patient consent

The authors certify that they have obtained all appropriate patient consent.

## Financial support and sponsorship

Nil.

## Conflicts of interest

There are no conflicts of interest.

## REFERENCES

- Akaishi T, Karibe H, Endo T, Ishii T. Organized chronic subdural hematoma: A condition presenting mixed-density hematoma without gradation density on brain CT. *Case Rep Neurol* 2021;13:699-703.
- Balevi M. Organized chronic subdural hematomas treated by large craniotomy with extended membranectomy as the initial treatment. *Asian J Neurosurg* 2017;12:598-604.
- Callovin GM, Bolognini A, Callovin G, Gammon V. Primary enlarged craniotomy in organized chronic subdural hematomas. *Neurol Med Chir (Tokyo)* 2014;54:349-56.
- Chen K, Wang K, Chen D, Niu H, Yang S, Wang Y. Surgical procedure in the treatment of organized chronic subdural hematoma: A single-center experience. *J Neurol Surg A Cent Eur Neurosurg* 2021;82:241-7.
- Chihara H, Imamura H, Ogura T, Adachi H, Imai Y, Sakai N. Recurrence of a refractory chronic subdural hematoma after middle meningeal artery embolization that required craniotomy. *NMC Case Rep J* 2014;1:1-5.
- Dabdoub CB, Adorno JO, Urbano J, Silveira EN, Orlandi BM. Review of the management of infected subdural hematoma. *World Neurosurg* 2016;87:663.e1-8.
- Edlmann E, Giorgi-Coll S, Whitfield PC, Carpenter KL, Hutchinson PJ. Pathophysiology of chronic subdural haematoma: Inflammation, angiogenesis and implications for pharmacotherapy. *J Neuroinflammation* 2017;14:108.
- Fujioka M, Okuchi K, Miyamoto S, Sakaki T, Tsunoda S, Iwasaki S. Bilateral organized chronic subdural haematomas: High field magnetic resonance images and histological considerations. *Acta Neurochir (Wien)* 1994;131:265-9.
- Haldrup M, Ketharanathan B, Debrabant B, Schwartz OS, Mikkelsen R, Fugleholm K, *et al.* Embolization of the middle meningeal artery in patients with chronic subdural hematoma-a systematic review and meta-analysis. *Acta Neurochir (Wien)* 2020;162:777-84.
- Hayashi S, Nishimoto Y, Nonakla M, Higuchi S, Hosoda K, Miki T, *et al.* Craniotomy following middle meningeal artery embolization for organized chronic subdural hematoma: Three case reports. *Neurosurg Emerg* 2018;23:138-4.
- Imaizumi S, Onuma T, Kameyama M, Naganuma H. Organized chronic subdural hematoma requiring craniotomy--five case reports. *Neurol Med Chir (Tokyo)* 2001;41:19-24.
- Kanazawa T, Karatsu K, Kuramae T, Ishihara M. Postoperative infected organised subdural haematoma that necessitated wide craniotomy. *BMJ Case Rep* 2021;14:e245134.
- Mandai S, Sakurai M, Matsumoto Y. Middle meningeal artery embolization for refractory chronic subdural hematoma. *Case report. J Neurosurg* 2000;93:686-8.
- Rodziewicz GS, Chuang WC. Endoscopic removal of organized chronic subdural hematoma. *Surg Neurol* 1995;43:569-73.
- Takahashi S, Yazaki T, Nitori N, Kano T, Yoshida K, Kawase T. Neuroendoscope-assisted removal of an organized chronic subdural hematoma in a patient on bevacizumab therapy--case report. *Neurol Med Chir (Tokyo)* 2011;51:515-8.
- Tamai S, Watanabe T, Ichinose T, Murakami KI, Ueno M, Munemoto S, *et al.* Morphological characteristics of infected subdural hematoma: Comparison with images of chronic subdural hematoma. *Clin Neurol Neurosurg* 2020;194:105831.
- Tamura R, Sato M, Yoshida K, Toda M. History and current progress of chronic subdural hematoma. *J Neurol Sci* 2021;429:118066.
- Tanaka T, Kaimori M. Histological study of vascular structure between the dura mater and the outer membrane in chronic subdural hematoma in an adult. *No Shinkei Geka* 1999;27:431-6.
- Waqas M, Vakhari K, Weimer PV, Hashmi E, Davies JM, Siddiqui AH. Safety and effectiveness of embolization for chronic subdural hematoma: Systematic review and case series. *World Neurosurg* 2019;126:228-36.
- Yokoya S, Nishii S, Takezawa H, Katsumori T, Takagi Y, Goto Y, *et al.* Organized chronic subdural hematoma treated with middle meningeal artery embolization and small craniotomy: Two case reports. *Asian J Neurosurg* 2020;15:421-4.

**How to cite this article:** Sato M, Mochizuki Y, Fukuchi M, Fujii K. Middle meningeal artery embolization before craniotomy for infected organizing chronic subdural hematoma: A case report and review of the literature. *Surg Neurol Int* 2022;13:186.