



Case Report

Extensive spontaneous cervical epidural hematoma due to oral anticoagulant (dabigatran) successfully treated with reversal agent idarucizumab alone

Syed-Abdullah Uddin¹, Katerina Roma², Lindsey Ross¹, George Hanna¹, Doniel Drazin², Terrence T. Kim³

¹Department of Neurosurgery, Cedars-Sinai Medical Center, Los Angeles, California, ²Department of Neurosurgery, Pacific Northwest University of Health Sciences, Yakima, Washington, ³Cedars-Sinai Medical Center, Spine Center, Los Angeles, California, United States.

E-mail: Syed-Abdullah Uddin - abdullah.uddin.med@gmail.com; Katerina Roma - donieldrazin@gmail.com; Lindsey Ross - lindsey.ross@cshs.org; George Hanna - georgehanna4@gmail.com; Doniel Drazin - ddrazin@gmail.com; *Terrence T. Kim - terrence.kim@cshs.org



*Corresponding author:

Terrence T. Kim, MD,
Cedars-Sinai Medical Center,
Spine Center, Los Angeles,
California, United States.

terrence.kim@cshs.org

Received : 14 September 2021

Accepted : 12 January 2022

Published : 23 June 2022

DOI

10.25259/SNI_929_2021

Quick Response Code:



ABSTRACT

Background: Dabigatran is an anticoagulant (novel oral anticoagulant) that is a direct thrombin inhibitor and only recently has a reversal agent, idarucizumab, been made available (2015).

Case Description: An 86-year-old male taking dabigatran for atrial fibrillation, acutely presented with the spontaneous onset of neck pain and quadriparesis. When the MRI demonstrated a C2-T2 spinal epidural hematoma, the patient was given the reversal agent idarucizumab. Due to his attendant major comorbidities, he was managed nonoperatively. Over the next 7 days, the patient's neurological deficits resolved, and within 2 weeks, he had regained normal neurological function.

Conclusion: In this case, a C2-T2 epidural cervical hematoma attributed to dabigatran that was responsible for an acute, spontaneous quadriparesis was successfully treated with the reversal agent idarucizumab without surgical intervention being warranted.

Keywords: Anticoagulant reversal, Dabigatran, Idarucizumab, Pradaxa, Spinal epidural hematoma

INTRODUCTION

One of the first novel oral anticoagulants (NOACs) marketed was dabigatran. It is an oral direct thrombin inhibitor that has the longest half-life (12–17 h) of any of the direct anticoagulants (DOACs).^[7] It is used for the prevention of stroke and systemic embolism in patients with nonvalvular atrial fibrillation.^[3] However, a major concern for patients on dabigatran is that they can develop spontaneous epidural spinal hematomas or other spontaneous hemorrhages. As of 2015, the reversal agent idarucizumab became available.^[5] Here, an 86-year-old male with multiple major comorbidities acutely presented quadriparetic due to a spontaneous C2-T2 epidural hematoma attributed to dabigatran. In this case, he was successfully managed with the reversal agent of dabigatran, idarucizumab. Notably, within 2 subsequent weeks, his neurological deficit fully resolved warranting no further surgical intervention.

This is an open-access article distributed under the terms of the Creative Commons Attribution-Non Commercial-Share Alike 4.0 License, which allows others to remix, transform, and build upon the work non-commercially, as long as the author is credited and the new creations are licensed under the identical terms.

©2022 Published by Scientific Scholar on behalf of Surgical Neurology International

CASE PRESENTATION

An 86-year-old male with atrial fibrillation presented with the acute onset of a spontaneous quadriparesis (i.e., upper extremities 2–3/5, lower extremities 5/5, diffuse hyperesthesia throughout the upper extremities, marked ataxia, and poor tandem gait). His medical history included idiopathic Parkinson's disease of over 10 years duration. The patient's medications included the anticoagulant dabigatran etexilate plus additional antiplatelet agents (i.e., clopidogrel and aspirin). His other medications included amiodarone, carbidopa-levodopa, and rasagiline.

Laboratory studies

Laboratory values revealed a serum WBC $4.8 \times 10^3/\mu\text{L}$, Hgb 13.0 g/dL, platelets $111 \times 10^3/\mu\text{L}$, an elevated PT (PT 14.3 s), and PTT (PTT 65 s). The INR was, however, just 1.0. Of interest, the troponin level was normal (0.01 ng/mL).

MR imaging

MRI sagittal imaging (i.e., could not tolerate complete sequences) demonstrated an expansile ventral epidural hematoma extending from C2 to T2 that resulted in significant cord compression. The signal within the clot was hypointense on T1 and hyperintense on the T2 sequences [Figures 1a and b]. A flow void was also seen in the epidural space posterior to the C6-7 disc space.

Medical management: Reversal of dabigatran and avoidance of surgery

The patient's medical management included stopping aspirin, clopidogrel, and dabigatran etexilate. After consulting with the hematology-oncology service, the patient was given idarucizumab, a direct monoclonal antibody inhibitor to dabigatran. In addition, he was started on intravenous dexamethasone 6 mg every 6 hours and gabapentin 100 mg 3 times daily.

Follow-up

Within 2 weeks, the patient regained normal (i.e., his baseline) neurological function. The MRI obtained 1 month later (further confirmed complete resolution of the ventral epidural hematoma with no residual hemorrhage) [Figures 2a and b].

DISCUSSION

NOACs

NOACs which were originally indicated for atrial fibrillation are now widely used for deep vein thrombosis and pulmonary embolism. A study of intracranial bleeding due to blunt

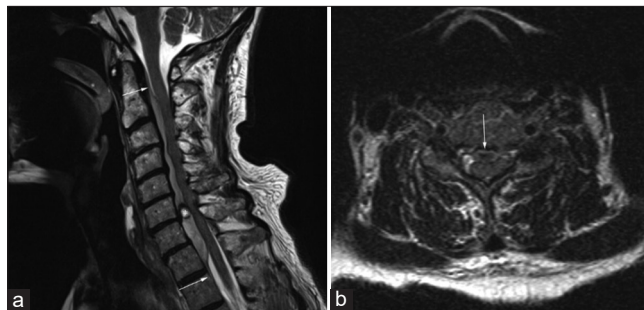


Figure 1: Cervical spine MRI (a) T2-weighted sagittal view demonstrating extensive ventral epidural hematoma extending from the mid-body of C2 to the superior edge of T2. *Indicates focal area of possible active hemorrhage measuring 7 mm × 6 mm at the level of the C6-7 disc space. (b) T2-weighted axial view with arrow indicating severe spinal cord impingement corresponding with focal area of hemorrhage. Arrows in the figure represent the extent of the epidural hematoma from the mid-C2 vertebral body to T2.

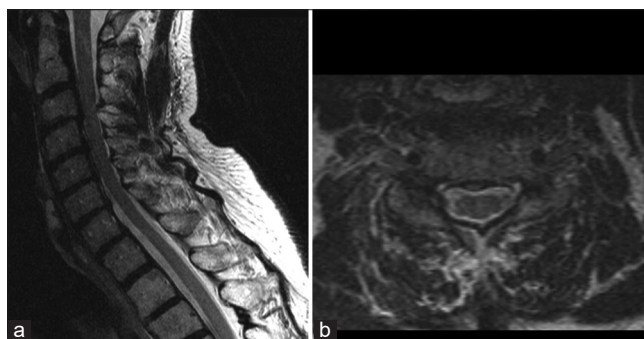


Figure 2: Cervical spine MRI obtained at 1 month follow-up with (a) T2-weighted sagittal view and (b) T2-weighted axial views demonstrating complete resolution of hematoma with resolution of previously demonstrated cord compression.

trauma in patients taking anticoagulants showed that the mortality and surgical intervention rates were significantly lower in the group receiving NOACs than in the warfarin group.^[7] However, until recently, none of the NOAC's had effective reversible agents. Although the half-lives of the NOAC's are significantly shorter than warfarin, withholding the drug does not suffice in rare bleeding emergencies such as intracranial hemorrhage. Administration of pro-thrombin complex concentrate (PCC) for reversal of dabigatran has not been shown to affect the surrogate markers of bleeding such as the thrombin time, ecarin clotting time, or activated partial thromboplastin time.^[10] Furthermore, the previous recommendations of administering 3-factor, 4-factor, PCC, and cryoprecipitate came from case studies alone with minimal evidence from randomized clinical trials.^[3,6,10]

Dabigatran and idarucizumab

In 2015, idarucizumab was approved as the first agent for antagonizing dabigatran. It is a humanized monoclonal

Table 1: Published cases reporting frequency of spinal epidural hematoma while on dabigatran with associated patient management and outcomes.

Study	Demographic	Presenting symptoms	Type/location of bleed	Treatment	Outcome
Present manuscript	86-yo M	Cervical P, BUE/BLE Wk, Numb, Imbal,	C2-T2 EDH	Dexamethasone+Idarucizumab	RESNF 1 month
Truumees <i>et al.</i> (2012) ^[11]	72-yo M	BLE Plegia, ASIA C	T7-T12 BFX, EDH	T4-L3 Lam, excessive bleeding delayed instrumentation to 7 days after initial surgery. (i.e., before idarucizumab 2015)	PR: UW, Bowel Intact, URET
Caputo <i>et al.</i> (2013) ^[2]	70-yo M	BLE Plegia Due to LESI	L3-L4 EDH	L3-L5 Lam	RESNF 6-months
Mathais <i>et al.</i> (2014) ^[8]	78-yo M	Cervical/right shoulder P/HP	C4-6 EDH	Idarucizumab+C3-C7 Lam	RESNF POD 4
Bamps <i>et al.</i> (2015) ^[11]	70-yo M	Cervical pain, quad, pares, AutD.	C2-C4 EDH	C2-C4 Lam PCC administered	RESNF ? TIME
Wolfe <i>et al.</i> (2017) ^[12]	67-yo M	LLE WK, loss P/V, RLE loss PT/URET urinary retention	C6-C7 SAH	IV Solu-Medrol, delayed idarucizumab	RESND 2 days

BUE: Bilateral upper extremity, POD: Postoperative day, BP: Blood pressure, PCC: Prothrombin complex concentrate, LLE: Left lower extremity, BLE: Bilateral lower extremity, yo: Years old, M: Male, EDH: Epidural hematoma, SAH: Subarachnoid hematoma, BFX: Burst fractures, BLE: Bilateral lower extremity, P: Pain, Plegia: Paraplegia, HP: Hemiparesis, LESI: Epidural steroid injection, URET: Urinary retention, Wk: Weakness, Numb: Numbness, IMB: Imbalance, Quad: Quadriplegia, Pares: Paresthesia, AutD: Autonomic dysfunction, PV: Position/vibration, PT: Pain/temperature, RESNF: Resolved neurological function, RH: Resolved hematoma, PR: Partial recovery, UW: Unable to walk, MR: Magnetic resonance imaging, Lam: Laminectomy

antibody fragment that has 350 times higher affinity to dabigatran compared to thrombin. Therefore, it antagonizes the effects of dabigatran within minutes.^[9] A study showed that idarucizumab completely reversed the anticoagulant activity of dabigatran in 88–98% of patients.^[4] The guidelines for the use of idarucizumab include life-threatening bleeding, bleeding into a critical organ or closed space, prolonged bleeding despite local hemostatic measures, high risk of recurrent bleeding because of overdose or delayed clearance of a drug, and the need for an urgent intervention associated with a high risk of bleeding.^[7]

Dabigatran and spinal hematomas

This case illustrates the relatively rare presentation of an extensive and spontaneous cervical epidural hematoma in a patient taking dabigatran. The presence of aspirin and clopidogrel can potentiate this problem [Table 1].^[1,2,8,11,12] Cases of dabigatran-associated spinal epidural hematoma reported in the literature before the FDA clearance of idarucizumab as a reversal agent in 2015 was treated with surgical intervention.^[2,11] Other cases reported successful reduction in hematoma size after the administration of idarucizumab but patients still required surgical decompression and evacuation.^[8,12]

CONCLUSION

An 86-year-old male on dabigatran and antiplatelet aggregates (i.e., aspirin and clopidogrel) presented with

an acute quadriplegia attributed to a spontaneous C2-T2 MR-documented ventral spinal epidural hematoma with marked cord compression. Through the administration of idarucizumab, a dabigatran antagonist, and the cessation of aspirin and clopidogrel, the patient's neurological deficit resolved over a 2-week period, without the need for surgery.

Declaration of patient consent

Patient's consent not required as patients identity is not disclosed or compromised.

Financial support and sponsorship

Nil.

Conflicts of interest

Dr. Kim is a consultant for Medtronic and Johnson & Johnson.

REFERENCES

- Bamps S, Decramer T, Vandebussche N, Verhamme P, Thijs V, Van Loon J, *et al.* Dabigatran-associated spontaneous acute cervical epidural hematoma. *World Neurosurg* 2015;83:257-8.
- Caputo AM, Gottfried ON, Nimjee SM, Brown CR, Michael KW, Richardson WJ. Spinal epidural hematoma following epidural steroid injection in a patient treated with dabigatran: A case report. *JBJS Case Connect* 2013;3 2 Suppl 9:e64.

3. Dumkow LE, Voss JR, Peters M, Jennings DL. Reversal of dabigatran-induced bleeding with a prothrombin complex concentrate and fresh frozen plasma. *Am J Health Syst Pharm* 2012;69:1646-50.
4. Gulati D, Dua D, Torbey MT. Hemostasis in intracranial hemorrhage. *Front Neurol* 2017;8:80.
5. Kermer P, Eschenfelder CC, Diener HC, Grond M, Abdalla Y, Abraham A, *et al.* Antagonizing dabigatran by idarucizumab in cases of ischemic stroke or intracranial hemorrhage in Germany-Updated series of 120 cases. *Int J Stroke* 2020;15:609-18.
6. Marlu R, Hodaj E, Paris A, Albaladejo P, Cracowski JL, Pernod G. Effect of non-specific reversal agents on anticoagulant activity of dabigatran and rivaroxaban: A randomised crossover *ex vivo* study in healthy volunteers. *Thromb Haemost* 2012;108:217-24.
7. Maruyama S, Hayakawa K, Kanayama S, Iwamura H, Wada D, Saito F, *et al.* Idarucizumab for a traumatic head injury patient taking dabigatran. *Int J Emerg Med* 2018;11:41.
8. Mathais Q, Esnault P, Cruc M, Bernard C, Prunet B, Gaillard PE. Spontaneous cervical spinal epidural hematoma associated with dabigatran. *World Neurosurg* 2018;112:264-6.
9. Pollack CV Jr., Reilly PA, Eikelboom J, Glund S, Verhamme P, Bernstein RA, *et al.* Idarucizumab for dabigatran reversal. *N Engl J Med* 2015;373:511-20.
10. Ross B, Miller MA, Ditch K, Tran M. Clinical experience of life-threatening dabigatran-related bleeding at a large, tertiary care, academic medical center: A case series. *J Med Toxicol* 2014;10:223-8.
11. Truumees E, Gaudu T, Dieterichs C, Geck M, Stokes J. Epidural hematoma and intraoperative hemorrhage in a spine trauma patient on pradaxa (dabigatran). *Spine (Phila Pa 1976)* 2012;37:E863-5.
12. Wolfe AR, Faroqui RM, Visvikis GA, Mantello MT, Perel AB, Tewari SO. Spinal subarachnoid and subdural hematoma presenting as a Brown-Séquard-like myelopathy following minor trauma in a patient on dabigatran etexilate. *Radiol Case Rep* 2017;12:257-60.

How to cite this article: Uddin S, Roma K, Ross L, Hanna G, Drazin D, Kim TT. Extensive spontaneous cervical epidural hematoma due to oral anticoagulant (dabigatran) successfully treated with reversal agent idarucizumab alone. *Surg Neurol Int* 2022;13:259.