



Original Article

# Outcome of surgical treatment for neglected congenital muscular torticollis: A series of 28 adolescent patients

Usman Ahmad Kamboh<sup>1</sup>, Mohammad Ashraf<sup>1,2</sup>, Shah Gul Zahra<sup>3</sup>, Muhammad Asif Raza<sup>1</sup>, Mehwish Manzoor<sup>4</sup>, Mehreen Mehboob<sup>1</sup>, Minaam Farooq<sup>3</sup>, Manzoor Ahmad<sup>1</sup>, Syed Shahzad Hussain<sup>1</sup>, Naveed Ashraf<sup>1</sup>

<sup>1</sup>Department of Neurosurgery, Allama Iqbal Medical College, Jinnah Hospital, Lahore, Pakistan, <sup>2</sup>Wolfson School of Medicine, University of Glasgow, Glasgow, Scotland, United Kingdom, <sup>3</sup>School of Medicine, King Edward Medical University, Lahore, Punjab, Pakistan, <sup>4</sup>Administration, Allama Iqbal Medical College, Jinnah Hospital, Lahore, Pakistan.

E-mail: \*Usman Ahmad Kamboh - [usmanschemer644@hotmail.com](mailto:usmanschemer644@hotmail.com); Mohammad Ashraf - [mohammad\\_5676@hotmail.com](mailto:mohammad_5676@hotmail.com); Shah Gul Zahra - [shahgulzahra4@gmail.com](mailto:shahgulzahra4@gmail.com); Muhammad Asif Raza - [razamonin@gmail.com](mailto:razamonin@gmail.com); Mehwish Manzoor - [mahwishmanzoor20@gmail.com](mailto:mahwishmanzoor20@gmail.com); Mehreen Mehboob - [dr.mehreenmehboob@gmail.com](mailto:dr.mehreenmehboob@gmail.com); Minaam Farooq - [minaamkemu2018@gmail.com](mailto:minaamkemu2018@gmail.com); Manzoor Ahmad - [manzoorahmad63@gmail.com](mailto:manzoorahmad63@gmail.com); Syed Shahzad Hussain - [drshahzadns@yahoo.com](mailto:drshahzadns@yahoo.com); Naveed Ashraf - [drnashraf@yahoo.com](mailto:drnashraf@yahoo.com)



\*Corresponding author:

Usman Ahmad Kamboh,  
Department of Neurosurgery,  
Allama Iqbal Medical College,  
Jinnah Hospital Lahore, Lahore,  
Pakistan.

[usmanschemer644@hotmail.com](mailto:usmanschemer644@hotmail.com)

Received : 03 April 2022

Accepted : 20 June 2022

Published : 08 July 2022

DOI

10.25259/SNI\_314\_2022

Quick Response Code:



## ABSTRACT

**Background:** Congenital muscular torticollis (CMT) is a common musculoskeletal anomaly that can be excellently managed at birth with conservative physiotherapy; as a result, literature on neglected cases of CMT in older patients is sparse, and there is controversy regarding the ideal surgical approach. This report aims to provide the outcome of 28 adolescent patients with neglected CMT who underwent unipolar release at the distal sternocleidomastoid muscle (SCM).

**Methods:** Twenty-eight adolescent patients with untreated CMT presented to our department between 2016 and 2019 and underwent unipolar release at the distal end of their SCM. All patients had no other anomaly based on clinical examination and radiological investigations. At the time of surgery, the mean age of patients was 15.8 years (range 13–18 years). There were 10 male and 18 female patients with the right side affected in 20 cases. All patients were followed up for 2 years. Patients were evaluated using an adapted version of the modified Lee's scoring system to assess cosmesis and the cervical-mandibular angle (CMA) to assess radiological change.

**Results:** The adapted modified Lee's scoring system indicated 17 patients (60.7%) had an excellent outcome, 6 patients (21.4%) had a good outcome, and 5 patients (17.9%) had a fair outcome. In particular, scarring was fine in 23 patients (82.1%) and only slight in the remaining. Independent to the categorical outcome, all patients subjectively reported high satisfaction with their cosmesis. The preoperative mean CMA was 19.6° (range, 8.5–31.5°), which was reduced to a mean of CMA of 14.0° (range, 3–28°) after surgery ( $P < 0.05$ ). No patient developed any permanent complication or required surgery for recurrence. No serious postoperative complications such as infection or hematoma were observed.

**Conclusion:** In uncomplicated cases of neglected CMT in adolescent patients, unipolar tenotomy of the distal SCM is a safe and reliable technique with good clinical outcomes.

**Keywords:** Adolescent, Congenital muscular torticollis, Neglected torticollis, Sternocleidomastoid muscle, Unipolar release

## INTRODUCTION

Torticollis is a Latin word that means twisted neck. First, Tubby in 1912 defined it as “a deformity, congenital, or acquired, characterized by a lateral inclination of the head to the shoulder, with torsion of the neck and deviation of the face.”<sup>[21]</sup>

This is an open-access article distributed under the terms of the Creative Commons Attribution-Non Commercial-Share Alike 4.0 License, which allows others to remix, transform, and build upon the work non-commercially, as long as the author is credited and the new creations are licensed under the identical terms.

©2022 Published by Scientific Scholar on behalf of Surgical Neurology International

Congenital muscular torticollis (CMT) is the third most common congenital musculoskeletal anomaly after dislocation of the hip and clubfoot.<sup>[19]</sup> The term CMT refers to a neck deformity that primarily involves a shortened sternocleidomastoid muscle (SCM) resulting in the patient's head turning toward the affected ipsilateral side and the chin pointing contralaterally.<sup>[6]</sup> Torticollis can be due to malposition of the fetus *in utero*, birth trauma, infection, and vascular injury, or it can be sequelae of an intrauterine or perinatal compartment syndrome. Patients with torticollis must be investigated to rule out the causes before the patient is labeled as a case of congenital torticollis. This includes the need for a detailed history and examination and relevant investigations such as X-ray cervical spine, anteroposterior, and lateral view; MRI cervical spine with cervical-medullary junction will reveal the presence of any cervical spine lesion or congenital hind brain herniation along with fibrotic band of SCM.

When diagnosed early, it is accepted that torticollis can be managed with good or excellent results using conservative physiotherapy.<sup>[6]</sup> Ling has stated that the optimal time for surgery is between 1 and 4 years if required.<sup>[2,14]</sup> This is based on the finding that most children treated before the age of 1 year respond well to conservative treatment.<sup>[2,14]</sup> However, literature regarding neglected cases of CMT in adolescent patients is sparse.<sup>[11,17,18]</sup> Because most of these cases are successfully treated in infancy, CMT reports in older patients are scares, and therefore, the optimal surgical treatment is controversial. Surgical approaches include unipolar sternocleidomastoid release, bipolar sternocleidomastoid release with or without Z-plasty, selective denervation, and dorsal cord stimulation. This paper describes our experience utilizing unipolar tenotomy of the distal SCM in a series of adolescent patients with neglected CMT.

## MATERIALS AND METHODS

This study was a prospective case series approved by our institutional review board and conducted at our neurosurgery department between 2016 and 2019. All images attached are with informed consent. We enrolled all patients who presented to our outpatient clinic with neglected congenital torticollis. All patients underwent a detailed neurological history and examinations and were advised relevant investigations including X-ray cervical spine and MRI with cervical-medullary junction. X-ray cervical spine was obtained for all patients to determine if a CT scan should be obtained, if a craniovertebral anomaly was suspected. Investigations and imaging were to ensure all cases could be labeled as CMT and other causes could be excluded from the study. All patients were followed up at their 2-year clinic visit.

## Inclusion and exclusion criteria

1. Patients of both sexes were aged 13–18 years.
2. Congenital torticollis with head tilt toward the affected side and tight band in the ipsilateral SCM.
3. Absence of any other abnormality in the neck as assessed on radiological imaging, including hindbrain herniation, cervical spine lesions, syringomyelia, and cervical spine and neck infection.
4. No previous medical or surgical treatment has been received for torticollis.

## Surgical procedure and postoperative management

All patients underwent a uniform operative technique of unipolar release of the lower end of SCM by the same neurosurgeon. Patients were positioned supine with their heads rotated toward the side opposite to torticollis. A transverse skin crease incision is marked 3 cm above the sternoclavicular end of the SCM. The skin and subcutaneous tissue were incised in the incision line, and the platysma was cut open. The lower end of the SCM was identified, and the sternal and clavicular head were released at the inferior end. The range of neck motion was also assessed at the inferior end, and the wound was closed in layers. Following surgery, manual stretching and rehabilitation of a cervical range of motion were performed by rehabilitation in the department twice daily, with each session lasting 30 min, for 3 days. On the 3<sup>rd</sup> postoperative day, all patients were discharged with the advice to continue manual stretching for 3 months and self-mirroring. Patients were advised a cervical collar for 3 months postoperatively.

## Outcome assessment

The outcomes in this series were assessed using the cervical-mandibular angle (CMA) and an adapted version of the modified Lee's criteria.<sup>[11]</sup> The CMA was calculated using radiological head tilt, defined as the angle between a line across the upper margin of the C7 vertebral body and another line that connects the inferior margins of the mandibular angles, as illustrated by Lee *et al.*<sup>[11]</sup>

An adapted version of the modified Lee's scoring system<sup>[11]</sup> was used. We did not have the resource to assess neck movements such as lateral bending and rotation objectively, so this parameter was omitted. In addition, the modified Lee's scoring system itself also excludes the facial asymmetry assessment criteria from the original Lee's criteria,<sup>[10]</sup> as craniofacial remodeling in this age group is relatively limited.<sup>[11]</sup> Our adapted scoring system is summarized in Table 1 and assesses cosmesis using the parameters' "head tilt," "scar," "loss of column," and "lateral band," giving a maximum score of 12. All parameters were clinically

**Table 1:** Assessing cosmesis using our adapted version of the modified Lee's score.<sup>[11]</sup>

Points	Head tilt	Scar	Loss of column	Lateral band
3	None	Fine	None	None
2	Mild	Slight	Slight	Slight
1	Moderate	Moderate	Obvious but cosmetically acceptable	Obvious but cosmetically acceptable
0	Severe	Unacceptable	Unacceptable	Unacceptable

evaluated as described in the original Lee's scoring system.<sup>[10]</sup> Outcome was categorized as follows:

1. Excellent: a score of 11 or 12
2. Good: a score of 9 or 10
3. Fair: a score <9.

Statistical Package for the Social Sciences Version 27 IMB was used to analyze the results. The CMA at baseline was compared to that at 2-year follow-up.  $P < 0.05$  was considered statistically significant.

## RESULTS

A total of 28 patients were studied, including 10 males and 18 females. The mean age was  $15.82 \pm 1.56$  (13–18 years). The right side was affected in 20 patients, while the left side was affected in 8. All patients were evaluated at a 2-year clinic follow-up [Table 2]. A total of 17 patients (60.7%) had an excellent cosmetic outcome, 6 (21.4%) had a good outcome, and 5 (17.9%) patients had a fair outcome [Table 2]. The preoperative head tilt was mild in 6 (21.4%) cases, moderate in 15 (53.5%) cases, and "severe" in 7 (25%) cases. Postoperatively, the head tilt was none in 23 (82.1%) patients and mild in 5 (17.9%) patients. Scarring was fine in 23 patients (82.1%) and slight in 5 (17.9%) patients. Loss of column was deemed none in 21 (75%) patients, slight in 6 (21.4%) patients, and obvious but cosmetically acceptable in 1 (3.6%). The presence of a lateral band was rated as none in 12 (42.9%) patients, slight in 13 (46.4%) patients, and obvious but cosmetically acceptable in 3 (10.7%) patients. The preoperative mean CMA was  $19.6^\circ$  (range, 8.5–31.5), which was reduced to a mean of CMA of  $14.0^\circ$  (range, 3–28) after surgery ( $P < 0.05$ ). No patient developed any permanent complication or required surgery for recurrence. No serious postoperative complications such as infection or hematoma were observed. Figure 1 illustrates the pre- and postoperative appearance of a patient who consented for their picture to be used.

## DISCUSSION

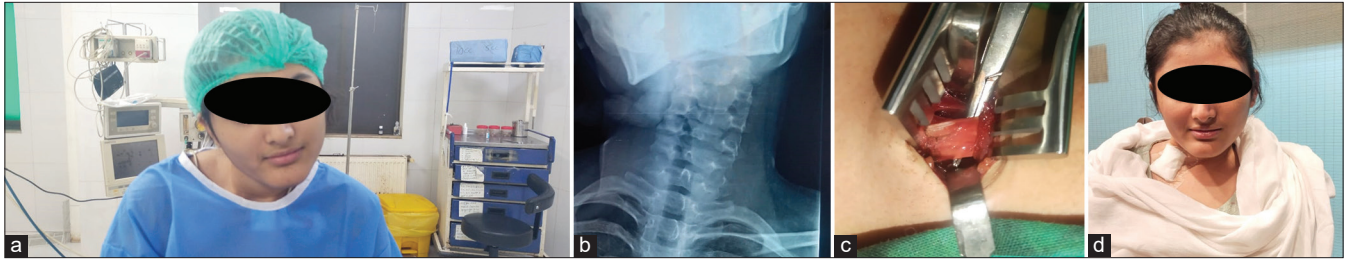
Most CMT cases resolve completely spontaneously within months after birth or with conservative measures initiated early, such as gentle controlled passive manual stretching exercises on the affected side. Sönmez *et al.* found that 95% of patients diagnosed and treated effectively before age 1 year

**Table 2:** Clinical features of 28 patients with congenital muscular torticollis treated with unipolar sternocleidomastoid release.

Variable (n=28)	Result
Age (years)	15.82±1.56 (range, 13–18)
Follow-up (months)	24
Sex (no.)	
Male	10
Female	18
Affected side (no.)	
Right	20
Left	08
Postoperative outcome	
Postoperative score	Mean=10.7, median=11, range=(8–12)
Excellent	17 (60.7%)
Good	06 (21.4%)
Fair	05 (17.9%)
Cervical-mandibular angle ( $^\circ$ )	
Preoperative	19.62±7.06 (range, 8.5–31.5)
Postoperative	14.03±6.87 (range, 3–28)

did not need surgical treatment.<sup>[20]</sup> In patients seen later, surgical intervention should be considered the treatment of choice to avoid further irreversible changes. Surgery is also recommended in patients with residual head tilt, passive rotation deficit, or lateral bending of more than  $15^\circ$  at the age of 6 months, despite early conservative interventions.<sup>[5]</sup>

The timing of surgery is controversial. Canale *et al.*<sup>[2]</sup> and Lee *et al.*<sup>[11]</sup> reported that full recovery of facial asymmetry after age 4 years is difficult to achieve. Lee *et al.*,<sup>[10]</sup> Minamitani *et al.*,<sup>[15]</sup> and Chen and Ko<sup>[3]</sup> reported that late release of the SCM for patients more than 6 years of age could yield acceptable results. However, literature assessing SCM release in adolescent and adult patients (over 20 years of age) is limited.<sup>[11,17,18]</sup> In addition, controversy also exists regarding the appropriate surgical method for older patients with neglected CMT.<sup>[9,11,14,17,18,22]</sup> Ling<sup>[14]</sup> proposed that benefit of surgery is limited over the age of 5 years, and the complication rate is high. However, other authors have demonstrated that surgical management of adult patients with neglected CMT using a bipolar release of the SCM gives excellent results by showing complete muscle release, satisfactory cosmetic appearance, and no recurrence.<sup>[22]</sup> Patients as old as 33 years have been treated using a bipolar release of the SCM without complication; even though facial asymmetry and underlying



**Figure 1:** Attached with patient informed consent. (a) Patients' immediate preoperative posture, (b) preoperative X-ray, (c) intraoperative tenotomy, (d) patient's postoperative picture.

fixed skeletal changes remain, the surgery and postoperative controlled gradual stretching restored near full range of neck motion.<sup>[16]</sup> Omid-Kashani *et al.*,<sup>[17]</sup> however, evaluated 18 adult and skeletally matured patients (mean age 21 years) surgically treated using bipolar release for neglected CMT and prospectively found that most patients had either an excellent or a good outcome.<sup>[17]</sup> The authors recommended bipolar sectioning in adulthood even with irreversible facial and skeletal deformities as the surgery restores the range of neck movements and head tilt. Patwardhan *et al.*,<sup>[18]</sup> studied 12 adult patients with neglected CMT (mean age 24) who were surgically treated using bipolar release with Z-plasty and were followed up for a minimum of 2 years. Most patients showed excellent results in the range of neck movement, head tilt improved in all 12 patients, and cosmesis improved in 11 patients.<sup>[18]</sup> Ippolito and Tudisco evaluated a group of eight adults with an average age of 26 years who underwent an open tenotomy and were followed for an average of 12 years. Moreover, while there was no resolution in facial asymmetry, range of neck movement improvement for all patients, and no complications were reported.<sup>[9]</sup> Lee *et al.*,<sup>[11]</sup> studied 31 adult patients of CMT (mean age 30.3 years, range 20–54 years) who underwent bipolar SCM release and reported excellent outcomes in 13%, good outcomes in 58%, and fair outcomes in 29% of patients. The average follow-up was 14.9 months (range 12–30 months); three patients developed a transient sensory deficit on the ipsilateral ear lobe, but no significant permanent complications were recorded, and no recurrence was documented.<sup>[11]</sup>

Concerning adolescent and younger patients, age, head tilt, scar formation, and craniofacial asymmetry are important parameters determining outcomes after surgery.<sup>[4,14,17]</sup> In children up to 13 years of age, with CMT and no other anomaly, partial resection of the SCM is reported to yield acceptable results with no recurrence, as reported by Akazawa *et al.*,<sup>[1]</sup> A similar approach by Lee *et al.*,<sup>[12]</sup> found similar outcomes but weakened the SCM muscle and altered its contour. However, this cohort consisted of patients as young as 9 months. Z-plasty can lead to tethering, and recurrent deformities in younger patients,<sup>[1]</sup> and studies have also shown that Z-plasty is not essential in older children.<sup>[3,17]</sup>

Chen and Ko reported a series of 18 neglected CMT patients aged 6–22 years (mean age of 11 years) in whom bipolar release was performed in 16 patients and bipolar release with Z-plasty in the remaining two patients.<sup>[3]</sup> This cohort had asymmetric articular facet of the axis and a tilt of the odontoid process toward the side of the torticollis.<sup>[3]</sup> The authors observed complete improvement of the tilt of the odontoid process after surgery, but the articular facets of the axis persisted. In addition, the two older patients did not show an improvement in facial asymmetry.<sup>[3]</sup> Based on the original Lees scoring system and a follow-up of 5 years, Chen and Ko concluded excellent results in 7 patients (38.9%), good results in 3 patients (16.7%), fair results in 6 patients (33.3%), and poor results in 2 patients (11.1%). While Ferkel *et al.*,<sup>[7]</sup> advocacy for his combined approach of bipolar release and Z-plasty was to preserve the normal v-contour of the SCM in the neckline, one of the two bipolar release with Z-plasty patients by Chen and Ko required a revision due to recurrence of torticollis 6 years after the initial release.<sup>[3]</sup> In addition, the authors also reported that there was no loss of normal contour of the SCM in patients who only underwent bipolar release without Z-plasty. Chen and Ko then recommended solely bipolar release in older patients with persistent deformities,<sup>[3]</sup> and Gill *et al.* have also favored bipolar release, especially in patients with relapsed CMT.<sup>[8]</sup>

Our study also showed good surgical results in adolescent patients with neglected CMT and no other abnormalities. In our series of adolescent patients treated with simple unipolar release, over 80% of patients had either an excellent or good result with no complications. We opted for a unipolar resection at the distal end of the SCM; rotation and lateral flexion on the left side improved, and SCM tension disappeared during surgery. Excellent results were found in 60.7% of patients and good results in 21.4%. No significant complications and recurrences were observed in any patients. In the study by Canale *et al.*, noticeable cosmetic deformity was observed in approximately 31% of patients.<sup>[2]</sup> In Lee *et al.*'s cohort of adults with neglected CMT treated using bipolar release, 22.6% of patients had slight scarring while 6.4% had moderate scarring as per the modified Lee's scoring criteria,<sup>[11]</sup> which was also used in

our cohort where scar appearance was rated “fine” in 82% of patients, slight in 17.9%, and no patient had moderate scarring. The unipolar release gave most patients satisfactory results in the neck contour and showed a fair range of neck movement. A study by Lim *et al.*<sup>[13]</sup> reported that the site of release was determined during the surgery, with bipolar release undertaken to prevent surgical morbidity in patients when manipulation could not give adequate correction after unipolar release.<sup>[13]</sup> If we can recognize that SCM tension will decrease and limitation of the range of motion for the neck will improve, selection of unipolar resection can be recommended as a surgical option for the adolescent patient with neglected CMT and it is appropriate in uncomplicated cases than more extensive surgical options like bipolar release with or without Z plasty. Unipolar release of CMT in most patients in this study improved the head tilt, leading to better life quality since the surgery, and patients adapted quite well to their new neck position.

The satisfaction rate in the follow-up was above 85%, even in those with a fair outcome. This is similar to Lee *et al.*<sup>[11]</sup> cohort of adult patients with CMT undergoing bipolar release. Despite a sizeable portion of their cohort having less than “excellent” outcomes; the patient’s self-reported global satisfaction rating score was 93.7% (90–100).<sup>[11]</sup> This can be explained by the fact that the severity of cosmetic facial deformity that occurs in neglected CMT in older patients and the obvious impact this has on mental health is so severe that any improvement is life changing from the patient’s perspective. This is especially true in our sociocultural demographic for women who face increasing pressure for an arranged marriage in their late teens to early 20s, a concern that the parents of our female patients mentioned. Our study has limitations. The sample size is small, but neglected CMT adolescent patients are few, given that early diagnosis and conservative management are increasing, therefore, reducing the need for those who require surgery. Assessment of neck movements such as rotation and lateral bending was assessed subjectively. We also did not assess facial asymmetry but subjectively, all patients reported improvement in their own perception of facial asymmetry, as did their relatives, which was documented in their clinic follow-up. In addition, while some authors have stated that a minimum 2-year follow-up may be sufficient given that wound healing takes 6 months–1 year and craniofacial remodeling is not expected in older patients; we still emphasize that longer follow-up with objective measurements assessing clinical parameters, and more thorough measurements evaluating the impact on a patient’s quality of life should be employed by the future studies.

## CONCLUSION

Adolescent patients with neglected CMT benefit from unipolar SCM release at the distal end. The surgery restores

the range of neck motion, resolves the head tilt, has minimum scarring, and greatly improves cosmesis, thus significantly improving the patient’s quality of life. All patients were greatly satisfied with their outcome, independent of whose outcome was clinically classified as excellent, good, or fair. Therefore, the unipolar release of the SCM is a safe and effective technique in adolescent patients with neglected CMT.

## Declaration of patient consent

Institutional Review Board (IRB) permission obtained for the study.

## Financial support and sponsorship

Nil.

## Conflicts of interest

There are no conflicts of interest.

## REFERENCES

1. Akazawa H, Nakatsuka Y, Miyake Y, Takahashi Y. Congenital muscular torticollis: Long-term follow-up of thirty-eight partial resections of the sternocleidomastoid muscle. *Arch Orthop Trauma Surg* 1993;112:205-9.
2. Canale S, Griffin D, Hubbard C. Congenital muscular torticollis. A long-term follow-up. *J Bone Joint Surg Am* 1982;64:810-6.
3. Chen CE, Ko JY. Surgical treatment of muscular torticollis for patients above 6 years of age. *Arch Orthop Trauma Surg* 2000;120:149-51.
4. Cheng J, Tang S. Outcome of surgical treatment of congenital muscular torticollis. *Clin Orthop Relat Res* 1999;362:190-200.
5. Cheng J, Wong M, Tang S, Chen T, Shum S, Wong E. Clinical determinants of the outcome of manual stretching in the treatment of congenital muscular torticollis in infants: A prospective study of eight hundred and twenty-one cases. *J Bone Joint Surg Am* 2001;83:679-87.
6. Do TT. Congenital muscular torticollis: Current concepts and review of treatment. *Curr Opin Pediatr* 2006;18:26-9.
7. Ferkel RD, Westin GW, Dawson EG, Oppenheim WL. Muscular torticollis. A modified surgical approach. *J Bone Joint Surg Am* 1983;65:894-900.
8. Gill S, Nagi O, Gakhar H. Bipolar release for neglected and relapsed cases of congenital muscular torticollis. *Indian J Orthop* 2005;39:45.
9. Ippolito E, Tudisco C. Idiopathic muscular torticollis in adults. *Arch Orthop Trauma Surg* 1986;105:49-54.
10. Lee E, Kang Y, Bose K. Surgical correction of muscular torticollis in the older child. *J Pediatr Orthop* 1986;6:585-9.
11. Lee GS, Lee MK, Kim WJ, Kim HS, Kim JH, Kim YS. Adult patients with congenital muscular torticollis treated with bipolar release: Report of 31 cases. *J Korean Neurosurg Soc* 2017;60:82.

12. Lee IJ, Lim SY, Song HS, Park MC. Complete tight fibrous band release and resection in congenital muscular torticollis. *J Plast Reconstr Aesthet Surg* 2010;63:947-53.
13. Lim KS, Shim JS, Lee YS. Is sternocleidomastoid muscle release effective in adults with neglected congenital muscular torticollis? *Clin Orthop Relat Res* 2014;472:1271-8.
14. Ling C. The influence of age on the results of open sternomastoid tenotomy in muscular torticollis. *Clin Orthop Relat Res* 1976;116:142-8.
15. Minamitani K, Inoue A, Okuno T. Results of surgical treatment of muscular torticollis for patients greater than 6 years of age. *J Pediatr Orthop* 1990;10:754-9.
16. Oh I, Nowacek CJ. Surgical release of congenital torticollis in adults. *Clin Orthop Relat Res* 1978;131:141-5.
17. Omid-Kashani F, Hasankhani EG, Sharifi R, Mazlumi M. Is surgery recommended in adults with neglected congenital muscular torticollis? A prospective study. *BMC Musculoskelet Disord* 2008;9:158.
18. Patwardhan S, Shyam A, Sancheti P, Arora P, Nagda T, Naik P. Adult presentation of congenital muscular torticollis: A series of 12 patients treated with a bipolar release of sternocleidomastoid and Z-lengthening. *J Bone Joint Surg Br* 2011;93:828-32.
19. Petronic I, Brdar R, Cirovic D, Nikolic D, Lukac M, Janic D, *et al.* Congenital muscular torticollis in children: Distribution, treatment duration and out come. *Eur J Phys Rehabil Med* 2010;46:153-7.
20. Sönmez K, Türkyilmaz Z, Demiroğulları B, Ozen IO, Karabulut R, Bağbancı B, *et al.* Congenital muscular torticollis in children. *ORL J Otorhinolaryngol Relat Spec* 2005;67:344-7.
21. Tubby AH. Deformities, Including Diseases of the Bones and Joints: A Text-book of Orthopaedic Surgery. Vol. 2. New York: Macmillan and Company, Limited; 1912.
22. Yuan B, Qu F, Zhao G, Wang J, Shen X, Liu Y. Arthroscopic surgical treatment for neglected congenital muscular torticollis in adults. *J Craniofac Surg* 2015;26:512-5.

**How to cite this article:** Kamboh UA, Ashraf M, Zahra SG, Raza MA, Manzoor M, Mehboob M, *et al.* Outcome of surgical treatment for neglected congenital muscular torticollis: A series of 28 adolescent patients. *Surg Neurol Int* 2022;13:292.