




Case Report

Successful treatment of focal hand dystonia after cervical whiplash injury by thalamotomy

Isamu Miura , Shiro Horisawa , Takakazu Kawamata , Takaomi Taira 

Department of Neurosurgery, Tokyo Women's Medical University, Tokyo, Japan.

E-mail: *Isamu Miura - miura.isamu@twmu.ac.jp; Shiro Horisawa - neurosurgery0222@gmail.com; Takakazu Kawamata - tkawamata@twmu.ac.jp; Takaomi Taira - ttaira@twmu.ac.jp



*Corresponding author:

Isamu Miura,
Department of Neurosurgery,
Tokyo Women's Medical
University, Tokyo, Japan.

miura.isamu@twmu.ac.jp

Received : 18 May 2022

Accepted : 09 August 2022

Published : 26 August 2022

DOI

10.25259/SNI_474_2022

Quick Response Code:



ABSTRACT

Background: Posttraumatic focal hand dystonia after cervical whiplash injury is rare. Moreover, the treatment of peripheral posttraumatic dystonia is usually ineffective. Herein, we report a case of successful thalamotomy for a patient with focal hand dystonia after cervical whiplash injury.

Case Description: A 39-year-old woman was hit from behind by a car; subsequently, she felt strange in the right hand and was diagnosed with whiplash injury. A month later, she developed a persistent abnormal posture of the right hand. Brain imaging showed no lesions, and cervical magnetic resonance imaging showed stenosis but no spinal cord signal changes. Posttraumatic dystonia was diagnosed, for which the patient underwent left ventro-oral (Vo) thalamotomy. One year after the first surgery, the patient underwent left Vo and ventral intermediate nucleus (Vim) thalamotomy due to recurrence of dystonia. Nine years after the second surgery, the patient continues to be able to maintain her normal physical routine.

Conclusion: Vo-Vim thalamotomy may be a feasible and effective treatment for focal hand dystonia after cervical whiplash injury.

Keywords: Posttraumatic dystonia, Stereotactic thalamotomy, Ventral intermediate nucleus, Ventro-oral, Whiplash

INTRODUCTION

Trauma is thought to be a cause of secondary dystonia.^[5] Although controversial, peripheral trauma which is defined as trauma outside the central nervous system (CNS) can also be a cause of dystonia. Cervical whiplash injury is common, and some cases of posttraumatic dystonia following whiplash have been reported.^[5,17] The most common form of dystonia following whiplash is cervical dystonia, while focal hand dystonia after whiplash is rare.^[1,4,14,15] The report of surgical interventions of posttraumatic dystonia, especially peripheral posttraumatic dystonia, is very rare.^[2,10] Ventro-oral (Vo) thalamotomy is one of the candidate treatments for primary focal hand dystonia.^[8,13] However, no reports have revealed the outcome of Vo thalamotomy in a patient with peripheral posttraumatic focal hand dystonia. Herein, we report a case of successful Vo and ventral intermediate nucleus (Vim) thalamotomy for a patient with focal hand dystonia after cervical whiplash injury. We have also provided a review of the literature regarding posttraumatic dystonia.

CASE REPORT

The patient was a 39-year-old right-handed woman with an unremarkable medical history. She was hit from behind by a car while waiting at a traffic signal on her motorbike; subsequently, she had neck pain and felt restricted movement in the right hand. The patient was diagnosed with whiplash injury. One month later, she developed a persistent abnormal posture of the right hand. Electrophysiological examination showed no abnormal findings. Head computed tomography (CT) and brain magnetic resonance imaging (MRI) showed no lesions. Cervical MRI showed cervical canal stenosis but no spinal cord signal change. She was diagnosed with posttraumatic dystonia and referred to our hospital for surgical treatment.

On admission, her right thumb was adducted at the metacarpophalangeal (MP) joint and extended at the distal interphalangeal (DIP) joint. The second to fourth fingers were fixed in flexion at the DIP and proximal interphalangeal (PIP) joints. Her fifth finger was flexed at the DIP and PIP joints and extended at the MP joint [Figure 1]. She was able to voluntarily extend or flex her fingers a little, but when she attempted to grip, her wrist flexed involuntarily. She reported no pain in her right hand. Although she reported some discomfort in her right lower limb, she was able to walk. Consequently, we planned Vo thalamotomy for focal hand dystonia after cervical whiplash injury.

First surgery

The patient underwent left Vo thalamotomy with the stereotactic target set at 1 mm above, 15 mm lateral to, and 2 mm posterior to the midpoint of the anterior commissure/posterior commissure line. Surgery was performed under local anesthesia without any microelectrode recording. A monopolar radiofrequency probe (tip diameter, 1.0 mm; uninsulated length, 4.0 mm) was used. Macrostimulation (130 Hz, 100 μ s pulse width, up to 15 mA) did not induce any adverse effects. Coagulation was performed at 70°C for 30 s at the tentative target, after which the electrode was withdrawn.

The extension and flexion of the right finger became smooth during the operation. There were no neurological deficits including paresthesia, dysphagia, sensory loss, or motor paresis after the surgery.

One day after the surgery, the patient extended and flexed the second to fourth fingers. Wrist movement got smooth. Seven days after the operation, the patient could write smoothly and was discharged. The patient reported recurrence of the right hand dystonia 14 months later; accordingly, revision surgery was planned.

Second surgery

The patient underwent left Vo and Vim thalamotomy; the stereotactic target coordinates, anesthesia, radiofrequency probe used, and coagulation procedure were all the same as those used for the first surgery. Macrostimulation (130 Hz, 100 μ s pulse width, up to 15 mA) did not induce any adverse effects. Coagulation was performed at the tentative target. The electrode was withdrawn in 1 and 3 mm increments to increase lesion size, resulting in three contiguous lesions. As symptoms did not improve, the target was changed to 3 mm anterior and 3 mm posterior to the previous target. Three contiguous lesions anterior and two lesions posterior to the tentative target were made, resulting in a total of eight lesions [Figure 2]. After coagulation, the movement of the patient's right hand became smooth.

There were no neurological deficits including paresthesia, dysphagia, sensory loss, or motor paresis after the second surgery. The patient was discharged 7 days after the second surgery. At the 8-year follow-up, although she reported occasionally experiencing awkwardness in her right hand, especially on cold days, the patient has maintained her normal physical routine.

DISCUSSION

Although trauma often precedes the onset of dystonia, its role in the development of dystonia has medical, psychological,



Figure 1: Improvement of the patient's right hand posture over the course of thalamotomy. Writing posture (a) and posture while holding a cup (b) before the surgery. Writing posture after the surgery (c).

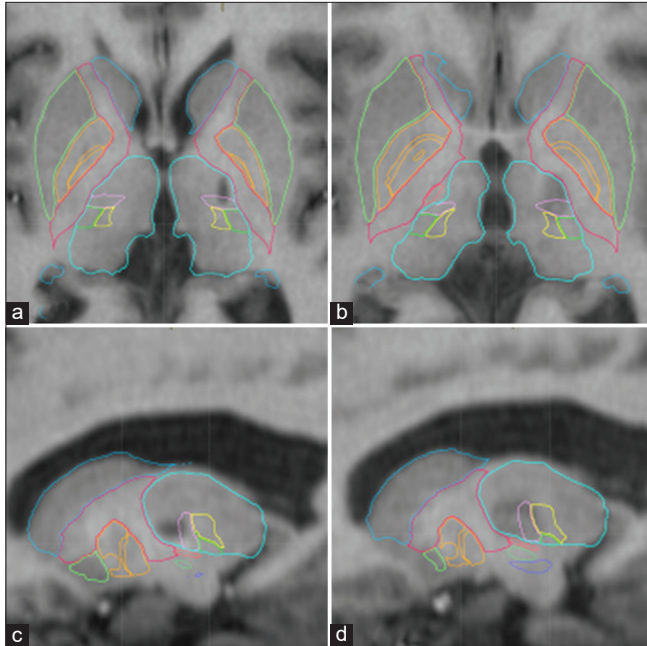


Figure 2: Lesions revealed by T1-weighted MRI. A coagulation lesion can be seen on the ventro-oral (Vo) and ventral intermediate nucleus (Vim) border of the left thalamus before the second surgery (a and b). After the second surgery, coagulation lesions can be seen on both the Vo and Vim of the left thalamus (c and d).

and legal implications and is a controversial topic.^[5] Posttraumatic dystonia can be classified into two types based on injury location. Central posttraumatic dystonia (CPD) usually occurs following severe head trauma; in such cases, onset can be delayed, confounding the association.^[5] Lesions are commonly observed on brain MRI or head CT. Peripheral posttraumatic dystonia (PPD) refers to the rare occurrence of dystonia following trauma to a region of the body outside the CNS. Complex regional pain syndrome may occur concurrently with dystonia, although the trauma is generally less severe compared to that in CPD. The onset of PPD is generally within a few days to 1 year after the injury. In the present case, the trauma was a typical whiplash injury sustained when the patient was hit from behind by a car. The patient's right hand was affected immediately after the injury, with abnormal posture developing and worsening within 1 month. The patient had no lesion of brain, cervical, or limbs lesions at the accident. Most cases of posttraumatic dystonia after cervical whiplash injury involve torticollis or cervical dystonia.^[4,15] Posttraumatic focal hand dystonia after a cervical whiplash injury is rare.^[1,14] Regarding whether posttraumatic dystonia after cervical whiplash injury should be classified as CPD or PPD, Tamburin and Zanette reported the case of a patient who developed a dystonic posture after a cervical whiplash injury caused by a small lesion on the cervical spinal cord.^[14] As the cervical spinal cord is part of the CNS, it was a case of CPD. In contrast, whiplash induces

pressure on the nerve root ganglia,^[16] which are outside the CNS; therefore, if a nerve root is injured, posttraumatic dystonia after whiplash is PPD. In our case, there were no lesions in the brain or cervical cord, and the onset of symptoms occurred immediately after the injury. These findings imply that this was a case of PPD.

The treatment of PPD, most commonly using botulinum toxin injections,^[3,18] is usually ineffective.^[5,9,10] Vo thalamotomy is one of the candidate treatments for focal hand dystonia.^[8,13] The Vo nucleus of the thalamus is a relay point in the corticobasal ganglia-thalamo-cortical circuit and a major termination site for basal ganglia outputs that control the motor cortex. The effects of Vo thalamotomy on focal hand dystonia may be based on alteration in this basal ganglia-thalamo-cortical circuit.^[8] The effectiveness of Vim thalamotomy has also been previously reported.^[11,12] Moreover, recurrence after Vo thalamotomy has been reported to occur due to insufficient or incorrect coagulation over the entire Vo nucleus of the thalamus.^[7] In our case, the thalamotomy lesion after the first operation did not cover a part of the Vo nucleus [Figure 2]. Therefore, in the second surgery, the target should be more on the posterior side. As a result, Vim coagulation was added. The Vop-Vim may be a target for focal hand dystonia in the cases of failure of Vo thalamotomy.^[6] After the second surgery, the lesions covered both the Vo and Vim. In fact, it is unclear which parts of Vo and Vim should be targeted; this aspect also needs further investigation. Due to symptom recurrence, the patient underwent rethalamotomy, which ultimately resulted in a successful outcome.

CONCLUSION

Here we presented a patient with focal hand dystonia after cervical whiplash injury. Vo-Vim thalamotomy may be a feasible and effective treatment for peripheral posttraumatic dystonia.

Declaration of patient consent

The authors certify that they have obtained all appropriate patient consent.

Financial support and sponsorship

Nil.

Conflicts of interest

There are no conflicts of interest.

REFERENCES

1. Cagnin A, Gasparoli E, Santelli L, Marcante A, Briani C. Posttraumatic dystonia and hemiplegic migraine: Different

- expressions of neuronal hyperexcitability? *Neurologist* 2012;18:36-8.
2. Capelle HH, Grips E, Weigel R, Blahak C, Hansjörg B, Wohrle JC, *et al.* Posttraumatic peripherally-induced dystonia and multifocal deep brain stimulation: Case report. *Neurosurgery* 2006;59:E702.
 3. Cavallieri F, Valzania F, Vercueil L, Moro E, Fraix V. A case of peripherally induced task-specific “lipstick dystonic tremor”. *Tremor Other Hyperkinet Mov (N Y)* 2019;9:689.
 4. Foley-Nolan D, Kinirons M, Coughlan RJ, O'Connor P. Post whiplash dystonia well controlled by transcutaneous electrical nervous stimulation (TENS): Case report. *J Trauma* 1990;30:909-10.
 5. Frei K. Posttraumatic dystonia. *J Neurol Sci* 2017;379:183-91.
 6. Hirato M, Miyagishima T, Takahashi A, Yoshimoto Y. Stereotactic selective thalamotomy for focal dystonia with aid of depth microrecording. *World Neurosurg* 2018;117:e349-61.
 7. Horisawa S, Goto S, Nakajima T, Ochiai T, Kawamata T, Taira T. Stereotactic thalamotomy for hairdresser's dystonia: A case series. *Stereotact Funct Neurosurg* 2016;94:201-6.
 8. Horisawa S, Ochiai T, Goto S, Nakajima T, Takeda N, Fukui A, *et al.* Safety and long-term efficacy of ventro-oral thalamotomy for focal hand dystonia: A retrospective study of 171 patients. *Neurology* 2019;92:e371-7.
 9. Jankovic J. Peripherally induced movement disorders. *Neurol Clin* 2009;27:821-32, vii.
 10. Kim JP, Chang WS, Chang JW. The long-term surgical outcomes of secondary hemidystonia associated with post-traumatic brain injury. *Acta Neurochir (Wien)* 2012;154:823-30.
 11. Li HX, He L, Zhang CC, Eisinger R, Pan YX, Wang T, *et al.* Deep brain stimulation in post-traumatic dystonia: A case series study. *CNS Neurosci Ther* 2019;25:1262-9.
 12. Rojas-Medina LM, Esteban-Fernández L, Rodríguez-Berrocá V, Del Álamo de Pedro M, Ley Urzaiz L, Bailly-Baillere IR. Deep brain stimulation in posttraumatic tremor: A series of cases and literature review. *Stereotact Funct Neurosurg* 2016;94:379-86.
 13. Taira T, Hori T. Stereotactic ventrooralis thalamotomy for task-specific focal hand dystonia (writer's cramp). *Stereotact Funct Neurosurg* 2003;80:88-91.
 14. Tamburin S, Zanette G. Focal hand dystonia after cervical whiplash injury. *J Neurol Neurosurg Psychiatry* 2003;74:134.
 15. Tarsy D. Comparison of acute- and delayed-onset posttraumatic cervical dystonia. *Mov Disord* 1998;13:481-5.
 16. Tencer AF, Huber P, Mirza SK. A comparison of biomechanical mechanisms of whiplash injury from rear impacts. *Annu Proc Assoc Adv Automot Med* 2003;47:383-98.
 17. van Rooijen DE, Geraedts EJ, Marinus J, Jankovic J, van Hilten JJ. Peripheral trauma and movement disorders: A systematic review of reported cases. *J Neurol Neurosurg Psychiatry* 2011;82:892-8.
 18. Vasileiadis GI, Sakellariou VI, Papagelopoulos PJ, Zoubos AB. Posttraumatic focal dystonia of the shoulder. *Orthopedics* 2012;35:e977-80.

How to cite this article: Miura I, Horisawa S, Kawamata T, Taira T. Successful treatment of focal hand dystonia after cervical whiplash injury by thalamotomy. *Surg Neurol Int* 2022;13:387.

Commentary

The authors of this case report describe very practical approach to a rarely-encountered but nevertheless very frustrating situation when the initial symptomatic improvement after an uneventful stereotactic lesioning procedure disappears over time. The decision they made – to repeat surgery, shift the target based on the patient's response, and enlarge the area of thermocoagulation – was a good one, and the lasting symptomatic relief (over the 8 years of follow up) is indeed a confirmation of the correctness of their choice.

One may argue that in patients with post-traumatic dystonia, the surgical intervention should avoid further injury to the nervous system, and that preferred approach should be non-destructive, i.e., neuromodulation – deep brain stimulation, but the advantages of straightforward stereotactic thalamotomy (procedural simplicity, minimal follow up requirements, much lower cost) as illustrated in this case, definitely support judicious use of targeted lesioning in selected patients.

With relative rarity of dystonia due to whiplash, it would be unlikely to see a large clinical series covering its surgical treatment; therefore, a case report with a useful teaching point on management of symptomatic recurrence should serve as an illustration of clinical thinking and individually tailored treatment choice.

Konstantin Slavin, MD

University of Illinois at Chicago; Chicago, IL, USA

kslavin@uic.edu