



## Case Report

# Oculomotor nerve palsy presumably caused by cisternal drain during microsurgical clipping

Hiroki Sugiyama, Satoshi Tsutsumi, Hisato Ishii

Department of Neurological Surgery, Juntendo University Urayasu Hospital, Urayasu, Japan.

E-mail: Hiroki Sugiyama - hi-sugiyama@juntendo.ac.jp; \*Satoshi Tsutsumi - shotaro@juntendo-urayasu.jp; Hisato Ishii - hisato-i@juntendo.ac.jp



### \*Corresponding author:

Satoshi Tsutsumi,  
Department of Neurological  
Surgery, Juntendo University  
Urayasu Hospital, Urayasu,  
Japan.

shotaro@juntendo-urayasu.jp

Received : 20 April 2022  
Accepted : 18 August 2022  
Published : 02 September 2022

DOI  
10.25259/SNI\_364\_2022

Quick Response Code:



## ABSTRACT

**Background:** Oculomotor nerve palsy can be caused by diverse etiologies, but no report has yet documented its association with a cisternal drain.

**Case Description:** A 35-year-old woman presented with severe headache. The patient did not exhibit oculomotor nerve palsy at presentation. Cranial computed tomography (CT) revealed diffuse subarachnoid hemorrhage. The patient underwent open microsurgical clipping of a ruptured middle cerebral artery aneurysm. During surgery, a cisternal drain was placed in the basal cistern at the medial aspect of the clinoidal portion of the internal carotid artery. The patient presented with the left oculomotor nerve palsy immediately after surgery. CT revealed displacement of the cisternal drain to the lateral aspect of the anterior clinoid process. The patient's mydriasis and sluggish light reaction recovered after 7 days, while extraocular movements persisted for 50 days. The constructive interference steady-state sequence detected the left oculomotor nerve coursing adjacent to the clinoidal internal carotid artery.

**Conclusion:** Oculomotor nerve palsy can be caused by collision with a thin silastic tube placed during surgery for aneurysmal subarachnoid hemorrhage. Withdrawal of the drain as early as possible is recommended when drain-associated oculomotor nerve palsy is suspected.

**Keywords:** Cisternal drain, Compressive neuropathy, Functional outcome, Oculomotor nerve palsy

## INTRODUCTION

Cisternal drainage is a common neurosurgical procedure performed during microsurgical clipping of an aneurysmal subarachnoid hemorrhage, with the aim of continuous removal of subarachnoid clots lodged in the basal cistern.<sup>[5]</sup> In general, the procedure is thought to be safe and effective for the prevention of symptomatic vasospasm, especially when the subarachnoid clots are thick.<sup>[7,12-14]</sup> Although rare, cerebral ischemic injuries associated with a cisternal drain have been documented.<sup>[4,16]</sup>

The oculomotor nerve, the third cranial nerve, initially arises from the medial aspect of the cerebral peduncle at the midbrain level. This then courses forward in the interpeduncular fossa and basal cistern, passes through the oculomotor triangle, and courses in the cavernous sinus. The nerve, then, passes through the central superior orbital fissure and enters the orbit.<sup>[11]</sup> The cisternal segments of the oculomotor nerve can be injured in an isolated manner by mild and severe traumatic brain injuries, acute epidural hemorrhage, sphenoid bone fracture, cerebral aneurysms, and intraoperative maneuvers using monopolar and bipolar coagulators.<sup>[2,3,6,8,9,15]</sup> Complete

This is an open-access article distributed under the terms of the Creative Commons Attribution-Non Commercial-Share Alike 4.0 License, which allows others to remix, transform, and build upon the work non-commercially, as long as the author is credited and the new creations are licensed under the identical terms.

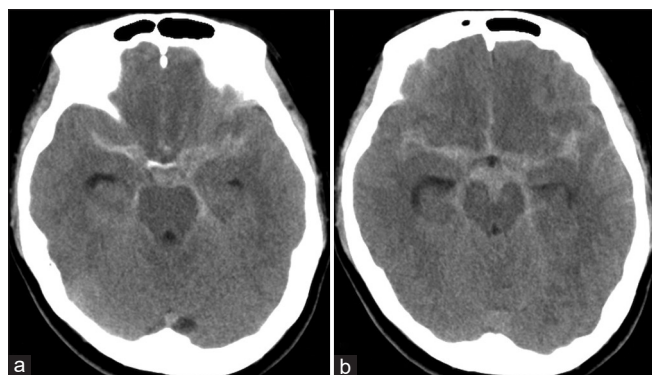
©2022 Published by Scientific Scholar on behalf of Surgical Neurology International

recovery from isolated, traumatic oculomotor nerve palsy is generally rare.<sup>[1,10,17]</sup>

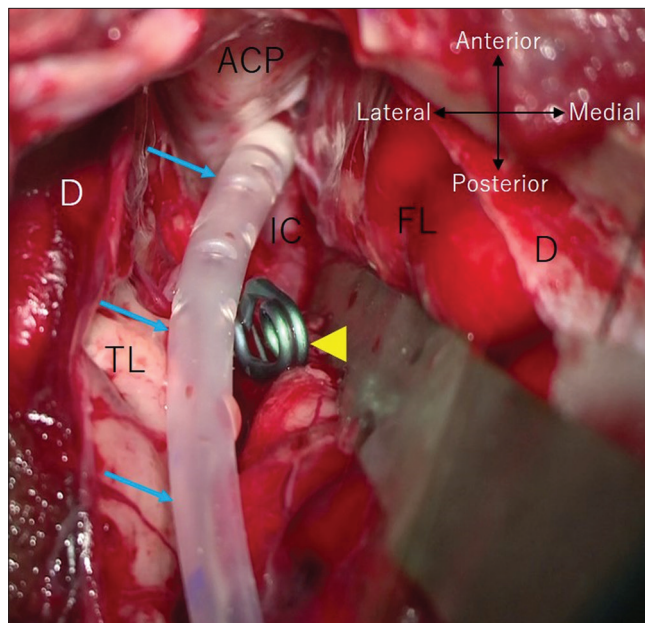
Here, we report a unique case of oculomotor nerve palsy, presumably caused by compression of a cisternal drain placed during surgery for aneurysmal subarachnoid hemorrhage.

## CASE PRESENTATION

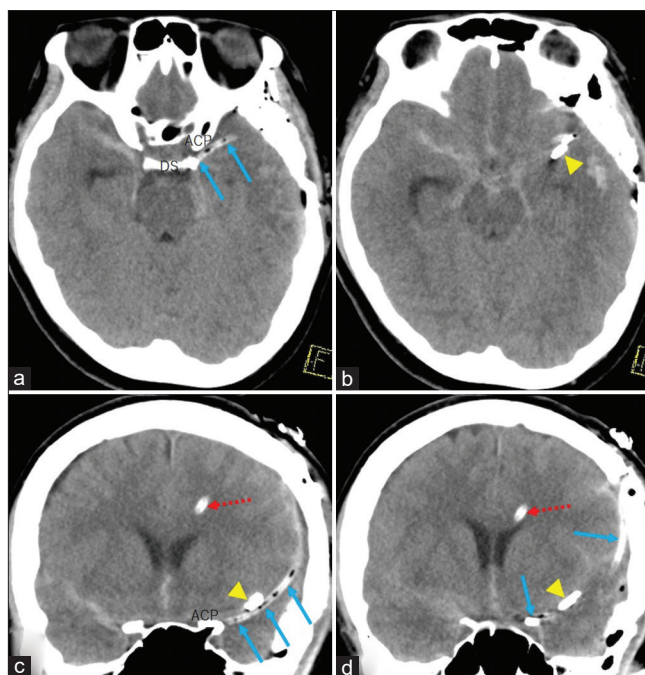
A 35-year-old, previously healthy woman, presented with severe headache and was transferred to the hospital. At presentation, the patient was drowsy, but did not show any focal neurological deficits. Her ocular position was neutral on both sides, and she presented with isochoric pupils. Ptosis was not found. Cranial computed tomography (CT) revealed a diffuse subarachnoid hemorrhage with a subtle ventriculomegaly. No abnormal findings were observed in the midbrain [Figure 1]. Three-dimensional CT angiography revealed a saccular aneurysm, 3 mm in diameter, at the branching site of the distal M1 segment of the left middle cerebral artery. The patient underwent open microsurgical clipping. During surgery, a ventricular catheter was placed in the left anterior horn, and the cerebrospinal fluid was intermittently drained to avoid excessive retraction to the left frontal lobe. After satisfactory clip application to the aneurysm neck, a commercially available silastic tube, 3.0 mm in an outer diameter, was placed in the basal cistern at the medial aspect of the clinoidal portion of the internal carotid artery and the anterior clinoid process [Figure 2]. Hematolytic agents such as papaverine or urokinase were not infused through the drain. The patient was well-oriented immediately after surgery, but presented with the left oculomotor nerve palsy represented by ptosis, mydriasis with sluggish light reaction, and restriction of extraocular movements, in 2/5, in the upward, downward, and leftward gaze. Prompt CT revealed that the tip of the cisternal



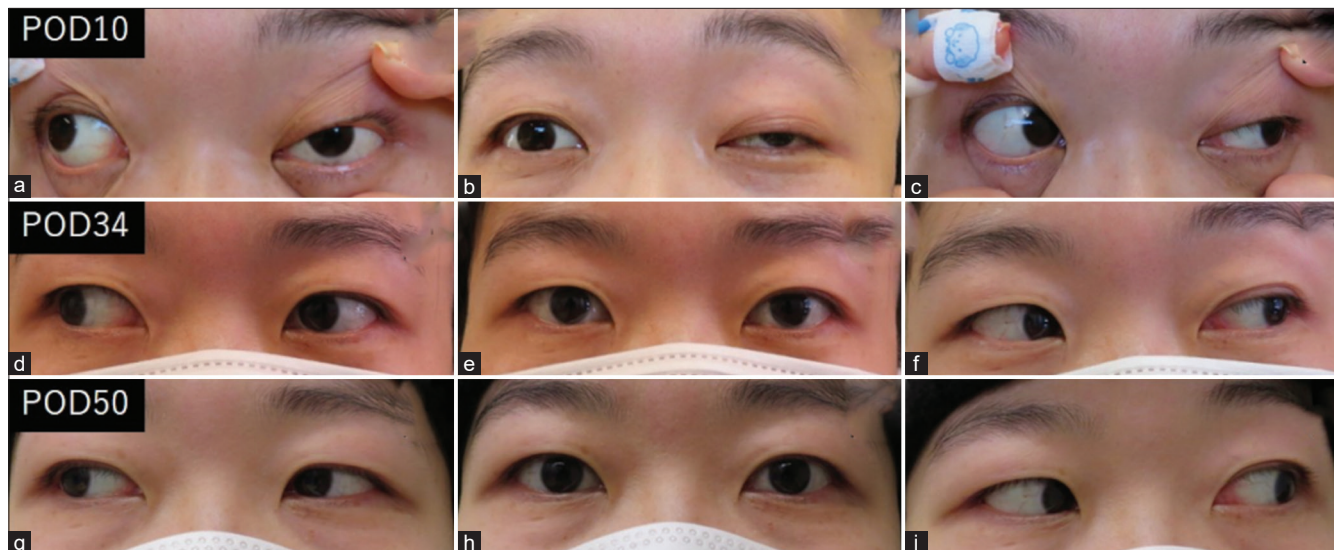
**Figure 1:** Axial computed tomography at the level of the upper pons (a) and midbrain (b) diffuse subarachnoid hemorrhage with slight ventriculomegaly, but no abnormal findings identified in the midbrain.



**Figure 2:** Intraoperative photo showing a cisternal drain (arrows), placed with the tip at the medial aspect of the internal carotid artery and anterior clinoid process following application of a clip (arrowhead) to the neck of the middle cerebral artery aneurysm. D: Dura mater, FL: frontal lobe, and TL: temporal lobe. ACP: Anterior clinoid process; IC: Internal carotid artery.



**Figure 3:** Axial (a and b) and coronal (c and d) computed tomography performed immediately after surgery showing the tip of the cisternal drain (a, c, d, arrows) displaced to the lateral aspect of the anterior clinoid process (ACP). DS: Dorsum sellae; Arrowhead: A clip applied to the ruptured middle cerebral artery aneurysm; Dashed arrow: ventricular catheter.

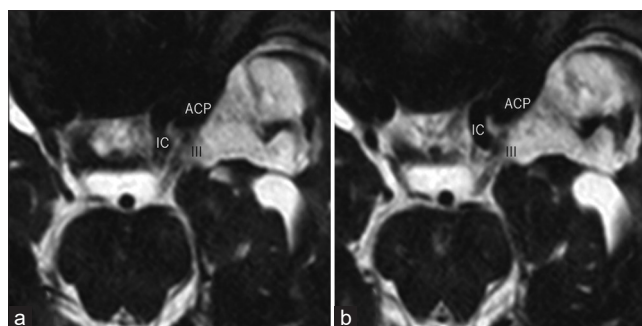


**Figure 4:** (a-i) Photos of the patient's ocular movements at postoperative day 3 showing ptosis, limitations of gaze in the lower and medial directions, and mydriasis in the left eye. POD: Postoperative day.

drain was displaced to the lateral aspect of the anterior clinoid process [Figure 3]. No other significant CT findings associated with the patient's symptoms were observed. Assuming mechanical injury to the left oculomotor nerve, the cisternal drain was immediately withdrawn, and steroid pulse therapy (methylprednisolone, 500 mg/day) was administered for 2 days. The patient's mydriasis and sluggish light reaction recovered 7 days after surgery; however, photophobia in the left eye persisted for 6 months. In contrast, recovery from restriction of extraocular movements was necessitated 50 days after surgery [Figure 4]. The constructive interference steady-state (CISS) sequence performed on postoperative day 30 detected the cisternal portion of the left oculomotor nerve coursing adjacent to the lateral wall of the clinoidal portion of the internal carotid artery [Figures 5 and 6].

## DISCUSSION

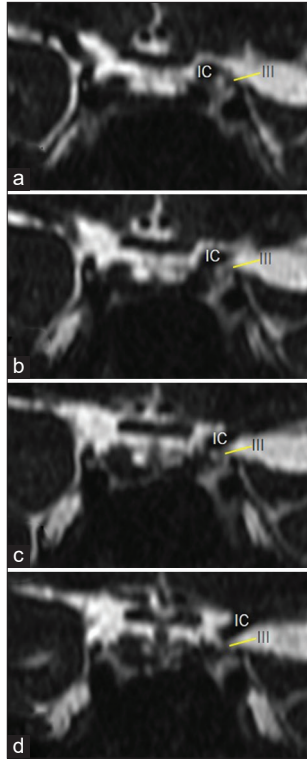
In the present patient, oculomotor nerve palsy was initially not found, but developed on the ipsilateral side immediately after surgery. CT performed immediately after surgery showed displacement of the tip of the cisternal drain, initially placed to the medial aspect of the anterior clinoid process, to the lateral aspect. No other significant CT findings associated with oculomotor nerve palsy were found. Furthermore, on the CISS sequence, the cisternal portion of the left oculomotor nerve was found to course adjacent to the lateral wall of the clinoidal internal carotid artery. Therefore, we assumed that the oculomotor nerve palsy was caused by collision with the displaced cisternal drain. Displacement of the drain probably occurred when releasing the retraction to the left frontal lobe at the final stage of the microsurgery,



**Figure 5:** (a and b) Adjacent images of the axial constructive interference steady-state sequence performed on postoperative day 30, showing the cisternal portion of the left oculomotor nerve (III) coursing adjacent to the lateral wall of the clinoidal internal carotid artery (IC). ACP: Anterior clinoid process.

combined with the tight intracranial cavity of a young patient sustaining subarachnoid hemorrhage.

Few reports have documented cases of traumatic oculomotor nerve palsy.<sup>[3,6,8,10,17]</sup> To the best of our knowledge, this is the first case of traumatic oculomotor nerve palsy associated with a cisternal drain. The neuropathy showed remarkable resolution for 50 days after the injury, although photophobia persisted for 6 months. The small diameter and soft material of the drain, in addition to the prompt withdrawal on cognition of abnormal oculomotor symptoms, may be associated with the process of functional recovery. Interestingly, pupillary sphincter function, which is regulated by fine parasympathetic fibers of the oculomotor nerve, showed faster initial recovery than extraocular movements that are controlled by thicker motor fibers of the nerve. Traumatic oculomotor nerve palsy caused by a cisternal drain



**Figure 6:** (a-d) Serial images of the coronal constructive interference steady-state sequence performed on postoperative day 30, showing the cisternal portion of the left oculomotor nerve (III) coursing adjacent to the lateral wall of the clinoidal internal carotid artery (IC). a (anterior)→ d (posterior).

may be a distinct neuropathy. Case accumulation, coupled with careful observation and timely management, could lead to more accurate knowledge of this condition.

Cisternal drainage is a common neurosurgical procedure performed during microsurgical clipping of an aneurysmal subarachnoid hemorrhage but can cause neurovascular complications.<sup>[4,16]</sup> On the other hand, the vast majority of ruptured cerebral aneurysms have been endovascularly treated that do not require placement of cisternal drainage. Therefore, oculomotor nerve palsy associated with cisternal drain would be more infrequent in the future.

## CONCLUSION

Oculomotor nerve palsy can be caused by collision with a thin silastic tube placed during surgery for aneurysmal subarachnoid hemorrhage. Withdrawal of the drain as early as possible is recommended when drain-associated oculomotor nerve palsy is suspected.

## Declaration of patient consent

The authors certify that they have obtained all appropriate patient consent.

## Financial support and sponsorship

Nil.

## Conflicts of interest

There are no conflicts of interest.

## REFERENCES

1. Aoun SG, Welch BG, Cortes M, Stutzman S, MacAllister MC, El Ahmadi TY, *et al.* Objective pupillometry as an adjunct to prediction and assessment for oculomotor nerve injury and recovery: Potential for practical applications. *World Neurosurg* 2019;121:e475-80.
2. Fujiwara S, Fujii K, Nishio S, Matsushima T, Fukui M. Oculomotor nerve palsy in patients with cerebral aneurysms. *Neurosurg Rev* 1989;12:123-32.
3. Gupta PK, Arif M, Shaik L, Singh R, Shah K. Solitary sign of third nerve palsy in a conscious patient with epidural hemorrhage. *Cureus* 2020;12:e10003.
4. Horiuchi T, Yamamoto Y, Kuroiwa M, Rahmah NN, Hongo K. Pontine infarction caused by medial branch injury of the basilar artery as a rare complication of cisternal drain placement. *J Clin Neurosci* 2012;19:592-3.
5. Kawakami Y, Shimamura Y. Cisternal drainage after early operation of ruptured intracranial aneurysm. *Neurosurgery* 1987;20:8-14.
6. Kim T, Nam K, Kwon BS. Isolated oculomotor nerve palsy in mild traumatic brain injury. *Am J Phys Med Rehabil* 2020;99:430-5.
7. Kinouchi H, Ogasawara K, Shimizu H, Mizoi K, Yoshimoto T. Prevention of symptomatic vasospasm after aneurysmal subarachnoid hemorrhage by intraoperative cisternal fibrinolysis using tissue-type plasminogen activator combined with continuous cisternal drainage. *Neurol Med Chir (Tokyo)* 2004;44:569-75.
8. Kuo LT, Huang AP, Yang CC, Tsai SY, Tu YK, Huang SJ. Clinical outcome of mild head injury isolated oculomotor nerve palsy. *J Neurotrauma* 2010;27:1959-64.
9. Kurokawa Y, Ishizaki E, Inaba K. Incomplete oculomotor nerve palsy caused by an unruptured internal carotid-anterior choroidal artery aneurysm--case report. *Neurol Med Chir (Tokyo)* 2005;45:143-7.
10. Lin C, Dong Y, Lv L, Yu M, Hou L. Clinical features and functional recovery of traumatic isolated oculomotor nerve palsy in mild head injury with sphenoid fracture. *J Neurosurg* 2013;118:364-9.
11. Natori Y, Rhoton AL Jr. Microsurgical anatomy of the superior orbital fissure. *Neurosurgery* 1995;36:762-75.
12. Ogura K, Hara M, Tosaki F, Hirai N. Effect of cisternal drainage after early operation for ruptured intracranial aneurysms. *Surg Neurol* 1988;30:441-4.

13. Otawara Y, Ogasawara K, Kubo Y, Sasoh M, Ogawa A. Effect of continuous cisternal cerebrospinal fluid drainage for patients with thin subarachnoid hemorrhage. *Vasc Health Risk Manag* 2007;3:401-4.
14. Sasaki T, Kodama N, Kawakami M, Sato M, Asari J, Sakurai Y, *et al.* Urokinase cisternal irrigation therapy for prevention of symptomatic vasospasm after aneurysmal subarachnoid hemorrhage: A study of urokinase concentration and the fibrinolytic system. *Stroke* 2000;31:1256-62.
15. Schietroma JJ, Tenzel RR. The effects of cautery on the optic nerve. *Ophthalmic Plast Reconstr Surg* 1990;6:102-7.
16. Tsunoda S, Inoue T, Ono H, Naemura K, Akabane A. Paramedian thalamic infarction caused by cisternal drain placement in open clipping for aneurysmal subarachnoid hemorrhage: Two case reports. *Surg Neurol Int* 2020;11:164.
17. Uberti M, Hasan S, Holmes D, Ganau M, Uff C. Clinical significance of isolated third cranial nerve palsy in traumatic brain injury: A detailed description of four different mechanisms of injury through the analysis of our case series and review of the literature. *Emerg Med Int* 2021;2021:5550371.

**How to cite this article:** Sugiyama H, Tsutsumi S, Ishii H. Oculomotor nerve palsy presumably caused by cisternal drain during microsurgical clipping. *Surg Neurol Int* 2022;13:398.