



## Case Report

# Horner's syndrome secondary to T1-T2 intervertebral disc prolapse

Mariette Anto<sup>1</sup>, Adarsh Manuel<sup>1</sup>, Akarsh Jayachandran<sup>1</sup>, Santhosh George Thomas<sup>1</sup>, Anu Joseph<sup>1,2</sup>, Anjitha Thankachan<sup>1</sup>, Biji Bahuleyan<sup>1</sup>

<sup>1</sup>Department of Neurosurgery, <sup>2</sup>Department of Ophthalmology, Lisie Hospital, Ernakulam, Kerala, India.

E-mail: Mariette Anto - marietteanto@gmail.com; Adarsh Manuel - adarshmanuel@gmail.com; Akarsh Jayachandran - akarshjayachandran@gmail.com; Santhosh George Thomas - santhoshgeorgethomas@gmail.com; Anu Joseph - anujoseph305@gmail.com; Anjitha Thankachan - thankachananjitha31@gmail.com; \*Biji Bahuleyan - drbijib@gmail.com



### \*Corresponding author:

Biji Bahuleyan,  
Department of Neurosurgery,  
Lisie Hospital, Ernakulam,  
Kerala, India.

drbijib@gmail.com

Received : 28 June 2022

Accepted : 20 August 2022

Published : 09 September 2022

### DOI

10.25259/SNI\_580\_2022

### Quick Response Code:



## ABSTRACT

**Background:** T1-T2 intervertebral disc prolapse (IVDP) is a rare clinical condition. Horner's syndrome is an extremely rare clinical finding in these patients.

**Case Description:** A 56-year-old man presented with the left C8 T1 radiculopathy, left hand grip weakness, and ipsilateral Horner's syndrome. Magnetic resonance imaging of the spine showed a contrast-enhancing lesion in the left T1 foramen compressing the left T1 nerve root. He underwent left T1 hemilaminectomy, upper half of left T2 hemilaminectomy and removal of the left foraminal lesion. A biopsy of the lesion was sent for histopathological diagnosis which revealed tissue consistent with disc material. Postoperatively, he had near-complete recovery with residual minimal Horner's syndrome.

**Conclusion:** T1-T2 IVDP should be considered in the differential diagnosis when a patient presents with C8 T1 radiculopathy and Horner's syndrome.

**Keywords:** Horner's syndrome, Radiculopathy, Spine, Thoracic disc prolapse

## INTRODUCTION

The incidence of thoracic disc prolapse is reported to be around 1 in 1000–1 in 1,000,000.<sup>[8,28]</sup> This accounts for <1% of all intervertebral disc prolapse (IVDP).<sup>[8,9]</sup> Among these, only around 4% of cases are above the level of T3.<sup>[9]</sup> Only around 24% of upper thoracic disc prolapses are found to be associated with Horner's syndrome.<sup>[27]</sup> In this case report, we present the diagnostic challenges and management of an extremely rare case of T1-T2 IVDP associated with Horner's syndrome.

## CASE REPORT

A 56-year-old man with no previously known comorbidities presented with a 3-week history of radicular pain along the medial aspect of the left arm and forearm, numbness along the medial aspect of the left arm and forearm, and progressive left-hand grip weakness.

On examination, he had left-sided partial ptosis and miosis [Figure 1a], wasting of the left forearm muscles and small muscles of the hand [Figure 1b], weakness of the intrinsic muscles of the left hand, and decreased sensation along the medial aspect of his left arm and forearm. His reflexes were normal.

This is an open-access article distributed under the terms of the Creative Commons Attribution-Non Commercial-Share Alike 4.0 License, which allows others to remix, transform, and build upon the work non-commercially, as long as the author is credited and the new creations are licensed under the identical terms.

©2022 Published by Scientific Scholar on behalf of Surgical Neurology International

Blood counts and inflammatory markers were normal. Chest X-ray and computed tomography (CT) thorax were normal. A magnetic resonance imaging (MRI) of the cervicothoracic spine revealed T1-T2 disc prolapse on T2-weighted images [Figures 2a and b]. On injecting gadolinium, contrast-enhancement [Figures 3a and b] was seen around the T1-T2 disc space. The lesion was seen compressing the left T1 nerve root. The radiological differential diagnosis of the lesion we considered was (i) inflammatory lesions such as pyogenic discitis or Pott's spine, (ii) benign lesions such as schwannoma, neurofibroma, or meningioma, (iii) malignant lesions such as metastasis, lymphoma, or Pancoast tumor, or (iv) cervicothoracic IVDP.

Under general anesthesia, he underwent left T1 hemilaminectomy, upper half of left T2 hemilaminectomy, and removal of the lesion through a posterior approach in prone position with electrophysiological monitoring. Intraoperatively, the foraminal lesion was seen filling the left T1 foramen and pushing the T1 nerve root superiorly and the dural tube medially. The lesion appeared fibrous and was seen extending into the T1-T2 disc space. The lesion was removed and the nerve root and dural tube were made lax. The dura and the nerve roots were not infiltrated by the lesion. There was no purulent material. Biopsy of the lesion revealed tissue

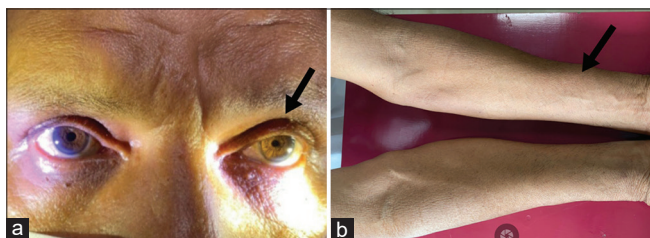
consistent with disc material with no evidence of granuloma, atypical, or malignant cells. The tissue culture from the lesion was reported as sterile. Immediately after surgery, his left upper limb radicular pain improved significantly. At 3-month follow-up, there was a total improvement in his left upper limb radicular pain, numbness, and weakness. Left forearm wasting was gradually improving, and there was residual minimal Horner's syndrome.

## DISCUSSION

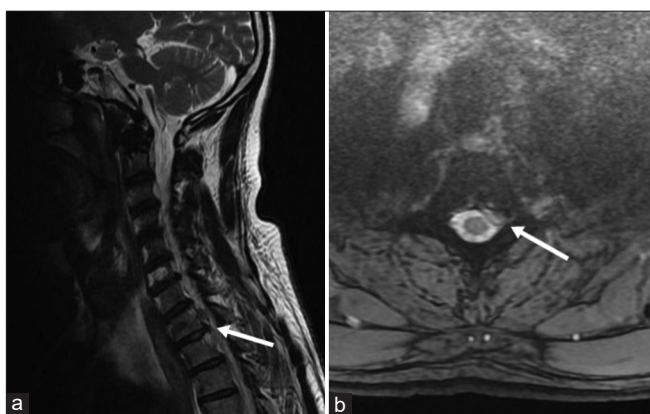T1-T2 IVDP is an extremely rare clinical entity.<sup>[24,26]</sup> The uncommonness of this condition is probably due to the relative stability of the vertebral column at this level.<sup>[17]</sup> Horner's syndrome in association with T1-T2 IVDP<sup>[5,6,11,13-15,20,23,25,27,28]</sup> has only been rarely reported.

The oculosympathetic pathway consists of central, preganglionic, and postganglionic neurons with two relay centers, the ciliospinal center of Budge and the superior cervical ganglion.<sup>[2,21]</sup> Interruption of any segment of the oculosympathetic pathway can cause Horner's syndrome.<sup>[2,21]</sup> The injury could be traumatic, neoplastic, vascular, or inflammatory etiology.<sup>[2]</sup> Horner's syndrome or oculosympathetic paralysis presents as a triad of ipsilateral pupillary constriction, facial anhidrosis, and ptosis caused by the relaxation of the superior tarsal muscle.<sup>[1,2,21,23,27]</sup>

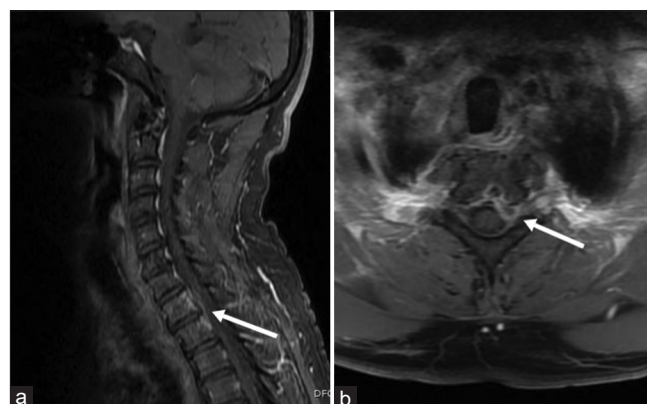
In T1-T2 IVDP, the disc can impinge on the sympathetic chain within the T1 root.<sup>[27]</sup> This causes disruption of the ipsilateral preganglionic sympathetic pathway with unopposed parasympathetic activity resulting in Horner's syndrome.<sup>[27]</sup> We believe that compression of the sympathetic chain by the T1-T2 disc at the T1 foramen could be the cause of Horner's syndrome in our case. The exact reason why



**Figure 1:** (a) Photograph showing ptosis and miosis of the left eye (black arrow), (b) Photograph showing wasting of left forearm muscles (black arrow).



**Figure 2:** (a) T2-weighted sagittal magnetic resonance imaging (MRI) image of the spine showing T1-T2 disc prolapse (white arrow), (b) T2-weighted axial MRI image of the spine showing a lesion at the left T1 foramen (white arrow).



**Figure 3:** (a) Gadolinium-enhanced T1-weighted sagittal magnetic resonance imaging (MRI) image of the spine showing contrast-enhancement around T1-T2 disc space (white arrow), (b) Gadolinium-enhanced T1-weighted axial MRI image of the spine showing a contrast-enhancing lesion at the left T1 foramen (white arrow).

**Table 1:** Summary of reported cases of T1-T2 disc prolapse associated with Horner's syndrome.

Reference	Age/Sex	Clinical features	Investigation	Treatment	Outcome
Hammon <sup>[14]</sup> (1968)	33/ Male	Lt T1 radiculopathy, Lt ptosis and miosis	Myelogram - Lt T1-T2 defect	Surgery - Hemilaminectomy and discectomy	Total recovery
Gelch <sup>[13]</sup> (1978)	40/ Male	Lt upper limb radiculopathy, Lt hand grip weakness, Lt ptosis and miosis	Myelogram - Lateral defect at T1-T2	Surgery - Partial laminectomy and discectomy	Near-total recovery with mild residual miosis
Lloyd <i>et al.</i> <sup>[20]</sup> (1979)	50/Male	Interscapular back pain radiating to Lt chest and arm, Lt hand intrinsic muscles weakness, Lt ptosis and miosis	Myelogram - Smooth extradural defect at Lt T1-T2	Surgery - Laminectomy and discectomy	Total recovery
Simper and Jorgensen <sup>[25]</sup> (1989)	UK	Lt upper limb radiculopathy, Lt ptosis and miosis	Myelogram and CT spine - Herniation of T1-T2 disc	Surgery - Laminectomy and discectomy	Total recovery
Caner <i>et al.</i> <sup>[6]</sup> (2003)	57/Male	Lt chest pain radiating to Lt upper limb, Lt T1 sensory loss, Lt hand intrinsic muscle weakness, Lt ptosis	MRI spine - Herniation of T1-T2 disc	Surgery - Discectomy through anterior approach	Total recovery
Spacey <i>et al.</i> <sup>[27]</sup> (2014)	54/Male	Periscapular pain radiating to the Rt medial forearm, Rt T1 sensory loss, Rt hand intrinsic muscle weakness, Rt ptosis and partial miosis	MRI spine - Lesion at the level of T1-2 with compression of the Rt T1 root	Conservative	Near-total recovery with mild residual ptosis
Foss-Skiftesvik <i>et al.</i> <sup>[11]</sup> (2015)	60/ Male	Thoracic back pain radiating to Rt upper limb, Rt T1 sensory loss, Rt hand intrinsic muscle weakness, Rt ptosis and miosis	MRI spine - Paramedian herniation of T1-T2 disc compressing Rt T1 nerve root	Conservative	Near-total recovery with mild T1 paraesthesia and mild ptosis
Heckmann and Pauli <sup>[15]</sup> (2016)	45/Female	Midscapular pain radiating to Lt upper limb, Lt T1 sensory loss, Lt hand grip weakness, Lt ptosis and partial miosis	MRI spine - Lt lateral disc herniation at T1-T2 level obliterating the T1-T2 intervertebral foramen	Surgery - Foraminotomy and discectomy via posterior approach	Total recovery
Teixeira <i>et al.</i> <sup>[28]</sup> (2017)	34/ Female	Neck and scapular pain radiating to Lt upper limb, Lt T1 sensory loss, Lt ptosis and miosis	MRI spine - Lt disc herniation at T1-T2 with intraforaminal compression of T1 nerve root	Surgery - Lt T1-T2 laminotomy, partial medial facetectomy and microdiscectomy.	Total recovery
Bhandutia <i>et al.</i> <sup>[5]</sup> (2017)	29/ Male	Rt upper limb radiculopathy, Rt T1 sensory loss, Rt ptosis, miosis and anhidrosis	MRI spine - Rt paracentral disc herniation at T1-T2 level	Surgery - Hemilaminectomy medial facetectomy and discectomy	NK
Possley <i>et al.</i> <sup>[23]</sup> (2018)	29/Male	Periscapular pain radiating to Lt upper limb, Lt T1 sensory loss, Lt handgrip weakness, Lt ptosis and miosis	MRI spine - T1-T2 Lt paracentral disc prolapse with Lt lateral stenosis with compression of Lt T1 nerve root	Surgery - Lamino-foraminotomy and discectomy	Near-total recovery with mild ptosis and miosis
Our case	56/Male	Lt C8 T1 radiculopathy, Lt T1 sensory loss, Lt handgrip weakness, Lt ptosis and miosis	MRI spine - Contrast-enhancing lesion in the Lt T1 foramen with compression of the Lt T1 nerve root	Surgery - Complete T1 and partial T2 Lt hemilaminectomy and discectomy	Near-total recovery with mild ptosis and miosis

MRI: Magnetic resonance imaging, Lt: left, Rt: Right, NK: Not known, CT: Computed tomography

anhidrosis was not seen in our case is unknown. This could be due to incomplete disruption of the sympathetic pathway at the T1 foramen.

There are multiple causes for the upper limb radiculopathy associated with Horner's syndrome. Pancoast tumor is reported to be the most common cause of T1 nerve root compression presenting with Horner's syndrome.<sup>[20]</sup> Other causes include (i) T1-T2 IVDP<sup>[5,6,11,13-15,20,23,25,27,28]</sup> as seen in our case, (ii) traumatic spinal cord injury at the cervicothoracic junction,<sup>[7,30]</sup> (iii) infective spine lesions such as osteomyelitis<sup>[18]</sup> or Pott's spine, and (iv) neoplastic lesions such as vertebral metastasis,<sup>[4]</sup> neurofibroma,<sup>[19,22]</sup> or schwannoma.<sup>[16]</sup>

Careful evaluation of the history and proper clinical examination can help localize the lesion.<sup>[21]</sup> MRI of the spine is the investigative procedure most commonly used to confirm the diagnosis of thoracic disc prolapse.<sup>[21]</sup> Contrast-enhanced MRI is indicated when inflammatory or neoplastic lesions are suspected. On contrast MRI, gadolinium enhancement is rarely seen in IVDP,<sup>[3,10,29]</sup> as seen in our case. Due to its atypical presentation on contrast MRI, we initially suspected the lesion to be inflammatory or neoplastic. However, the biopsy sent for histopathological diagnosis revealed tissue consistent with disc material. Our case is novel in that it is the first reported case of T1-T2 disc prolapse showing contrast-enhancement on MRI.

With technological advancement, intraoperative ultrasound and neuronavigation are being increasingly used for image-guided spine surgery.<sup>[12]</sup> These modalities allow for minimally invasive spine surgeries and permit maximal resection of spinal lesions while preserving vital neural structures.<sup>[12]</sup> Hence, liberal use of intraoperative imaging should be done to ensure complete resection of spinal lesions without damage to the spinal cord and surrounding neural structures.

In 2019, Rahimizadeh *et al.*<sup>[24]</sup> identified previously reported 32 cases of T1-T2 IVDP. In addition to this, they analyzed and reported four new cases from their own experience. We were able to identify six more previously reported cases<sup>[5,11,15,23,25,28]</sup> in addition to the 36 cases reviewed by Rahimizadeh *et al.* This makes our case the 43<sup>rd</sup> reported case of T1-T2 IVDP published in the literature. Among these reported cases of T1-T2 IVDP, we were able to identify Horner's syndrome in only 11 cases (26.2%).<sup>[5,6,11,13-15,20,23,25,27,28]</sup>

[Table 1] summarizes all the 11 cases of T1-T2 IVDP associated with Horner's syndrome published in the literature. The age of these patients ranged from 29 to 60 years. There was a male preponderance. Scapular pain,<sup>[15,20,23,27,28]</sup> thoracic back pain,<sup>[11]</sup> upper limb radiculopathy,<sup>[5,6,11,13-15,20,23,25,27,28]</sup> sensory loss,<sup>[5,6,11,15,23,27,28]</sup> and weakness of intrinsic muscles of the hand<sup>[6,11,13,15,20,23,27]</sup> were the presenting symptoms. In most cases, an MRI spine with or without contrast was done to confirm the diagnosis.<sup>[5,6,11,15,23,27,28]</sup> For cases

from the pre-MRI era, myelogram and CT were used as investigative modalities.<sup>[13,14,20,25]</sup> T1-T2 IVDP is managed either surgically or conservatively.<sup>[27]</sup> A small percentage of patients improve with conservative management<sup>[11,27]</sup> while most require surgical treatment.<sup>[5,6,13-15,20,23,25,28]</sup> Surgically, T1-T2 IVDP was approached either through an anterior<sup>[6]</sup> or a posterior<sup>[5,13-15,20,23,25]</sup> approach. Posterior approach to T1-T2 IVDP was done through a laminectomy,<sup>[25,28]</sup> facetectomy,<sup>[5,28]</sup> hemilaminectomy,<sup>[5,14]</sup> or foraminotomy.<sup>[15,23]</sup> Only two cases were reported where the patients were managed conservatively.<sup>[11,27]</sup> All patients showed improvement in their symptoms and they had good outcomes.

## CONCLUSION

T1-T2 IVDP should be considered in the differential diagnosis when a patient presents with C8 T1 radiculopathy and ipsilateral Horner's syndrome. A careful neurological examination needs to be done to look for Horner's syndrome in these patients. A contrast-enhanced MRI spine should be the investigation of choice in these patients as it helps to rule out inflammatory and neoplastic causes of C8 T1 radiculopathy. The MRI should always extend to the upper thoracic vertebral levels in these cases. The majority of these patients require a discectomy. A small subgroup of patients with T1-T2 IVDP improves with conservative treatment. These patients generally have good outcomes.

## Declaration of patient consent

The authors certify that they have obtained all appropriate patient consent.

## Financial support and sponsorship

Nil.

## Conflicts of interest

There are no conflicts of interest.

## REFERENCES

1. Alstadhaug K. Ervervet Horners syndrom. Tidsskr Nor Legeforen 2011;131:950-4.
2. Amonoo-Kuofi HS. Horner's syndrome revisited: With an update of the central pathway. Clin Anat 1999;12:345-61.
3. Araki Y, Ootani M, Furukawa T, Yamamoto T, Tsukaguchi I, Mitomo M. Pseudoenhancement of intervertebral disc herniation. Neuroradiology 1992;34:271-2.
4. Barrero MC, Perras N, Martín E, Marsal C, Carbonell MA, Pinto JM. Horner's syndrome and brachial radiculopathy related to vertebral metastases. Rev Neurol 1999;29:614-6.
5. Bhandutia AK, Zuzek Z, Schessler MJ, Tomycz ND, Altman DT. High thoracic disc herniation causing horner

- syndrome with the intraoperative finding of conjoined nerve root compression: A case report. *JBJS Case Connect* 2017;7:e4.
6. Caner H, Kiliçoğlu BF, Benli S, Altınör N, Bavbek M. Magnetic resonance image findings and surgical considerations in T1-2 disc herniation. *Can J Neurol Sci J Can Sci Neurol* 2001;30:152-4.
  7. Carlstedt T, Hultgren T, Nyman T, Hansson T. Cortical activity and hand function restoration in a patient after spinal cord surgery. *Nat Rev Neurol* 2009;5:571-4.
  8. Carson J, Gumpert J, Jefferson A. Diagnosis and treatment of thoracic intervertebral disc protrusions. *J Neurol Neurosurg Psychiatry* 1971;34:68-77.
  9. Davies PR, Kaar G. High thoracic disc prolapse in a rugby player: The first reported case. *Br J Sports Med* 1993;27:177-8.
  10. Ellenberg M, Ilchukwu I. Gadolinium-enhanced disc lesion. *Am J Phys Med Rehabil* 2004;83:550.
  11. Foss-Skiftesvik J, Hougaard MG, Larsen VA, Hansen K. Clinical reasoning: Partial horner syndrome and upper right limb symptoms following chiropractic manipulation. *Neurology* 2015;84:e175-80.
  12. Ganau M, Syrmos N, Martin AR, Jiang F, Fehlings MG. Intraoperative ultrasound in spine surgery: History, current applications, future developments. *Quant Imaging Med Surg* 2018;8:261-7.
  13. Gelch MM. Herniated thoracic disc at T1-2 level associated with Horner's syndrome. Case report. *J Neurosurg* 1978;48:128-30.
  14. Hammon WM. Extruded upper thoracic disc causing Horner's syndrome: Report of a case. *Med Ann Dist Columbia* 1968;37:541-2.
  15. Heckmann JG, Pauli S. Horner syndrome and thoracic disc herniation. *Neurohospitalist* 2016;6:42.
  16. Kahraman A, Yildirim I, Kiliç MA, Okur E, Demirpolat G. Horner's syndrome from giant schwannoma of the cervical sympathetic chain: Case report. *B ENT* 2009;5:111-4.
  17. Kumar R, Buckley TF. First thoracic disc protrusion. *Spine* 1986;11:499-501.
  18. Larkin SS, Gray AJ. An unusual cause of Horner syndrome. *J Gen Intern Med* 2018;33:774-5.
  19. Lee JH, Jeon YM, Kang SG, Tark MS, Kim CH. Horner syndrome in neurofibromatosis Type 1. *J Craniofac Surg* 2015;26:165-6.
  20. Lloyd T, Johnson J, Paul D, Hunt W. Horner's syndrome secondary to herniated disc at T1--T2. *Am J Roentgenol* 1980;134:184-5.
  21. Ma H, Kim I. Horner syndrome associated with a herniated cervical disc: A case report. *Korean J Spine* 2012;9:108-10.
  22. Nehete LS, Konar SK, Nandeesh BN, Shukla D, Devi BI. Atypical presentation of extraspinal neurofibroma presenting with acute-onset monoparesis and Horner's syndrome: Case report and review of literature. *J Craniovertebral Junction Spine* 2019;10:188-91.
  23. Possley D, Luczak SB, Angus A, Montgomery D. T1-T2 disk herniation presenting with Horner syndrome: A case report with literary review. *J Am Acad Orthop Surg Glob Res Rev* 2018;2:e016.
  24. Rahimizadeh A, Zohrevand AH, Kabir NM, Asgari N. T1-T2 disc herniation: Report of four cases and review of the literature. *Surg Neurol Int* 2019;10:56.
  25. Simper LB, Jørgensen AK. Intervertebral disk prolapse as an unusual cause of Horner's syndrome. *Ugeskr Laeger* 1989;151:949-50.
  26. Son ES, Lee SH, Park SY, Kim KT, Kang CH, Cho SW. Surgical treatment of t1-2 disc herniation with t1 radiculopathy: A case report with review of the literature. *Asian Spine J* 2012;6:199-202.
  27. Spacey K, Dannawi Z, Khazim R, Dannawi Z. Horner's syndrome secondary to intervertebral disc herniation at the level of T1-2. *Case Rep* 2014;2014:204820.
  28. Teixeira JC, Santos MM, Melancia JL. T1-T2 Herniated disk presenting with Horner syndrome. *World Neurosurg* 2017;107:1050.e13-5.
  29. Whittaker CK, Bernhardt M. Magnetic resonance imaging shows gadolinium enhancement of intradural herniated disc. *Spine (Phila Pa 1976)* 1994;19:1505-7.
  30. Yokota H, Yokoyama K, Noguchi H, Uchiyama Y. Spinal cord herniation into associated pseudomeningocele after brachial plexus avulsion injury: Case report. *Neurosurgery* 2007;60:E205; discussion E205.

**How to cite this article:** Anto M, Manuel A, Jayachandran A, Thomas SG, Joseph A, Thankachan A, *et al.* Horner's syndrome secondary to T1-T2 intervertebral disc prolapse. *Surg Neurol Int* 2022;13:412.