

## Case Report

# Case report: Radiofrequency thalamotomy as palliative care for Holmes tremor in a patient with terminal cancer and cardiac pacemaker

Kazunori Oda, Takashi Morishita, Hideaki Tanaka, Hiromasa Kobayashi, Hiroshi Abe

Department of Neurosurgery, Fukuoka University, Fukuoka, Japan.

E-mail: Kazunori Oda - k.oda@fukuoka-u.ac.jp; \*Takashi Morishita - tmorishita@fukuoka-u.ac.jp; Hideaki Tanaka - hideaki08seven@gmail.com; Hiromasa Kobayashi - hiromasa0530@gmail.com; Hiroshi Abe - neuroabe1972@gmail.com



### \*Corresponding author:

Takashi Morishita,  
Department of Neurosurgery,  
Fukuoka University, Fukuoka,  
Japan.

[tmorishita@fukuoka-u.ac.jp](mailto:tmorishita@fukuoka-u.ac.jp)

Received : 11 July 2022

Accepted : 27 September 2022

Published : 21 October 2022

### DOI

10.25259/SNI\_618\_2022

### Quick Response Code:



## ABSTRACT

**Background:** Herein, we present a case report of a patient with Holmes tremor due to thalamic infarction with end-stage pancreatic cancer who underwent successful computed tomography (CT)-guided ventralis intermedialis nucleus (Vim) thalamotomy as palliative care.

**Case Description:** A 78-year-old man with gradually worsening involuntary movements on the left side of his body 2 years after a right thalamic infarction was referred to our institute. He had a history of chronic atrial fibrillation for which he was implanted with a cardiac pacemaker not compatible with magnetic resonance imaging. He also received adjuvant therapy for pancreatic cancer. As the involuntary movements interfered with his daily life, the patient elected for neurosurgical treatment despite having terminal cancer. Although the prognosis for pancreatic cancer was considered to be more than 6 months at the time of surgery, we performed CT-guided Vim thalamotomy under local anesthesia without pulse generator implantation considering the patient's general condition. The involuntary movements of the left side of the body reduced following surgery, thus improving his quality of life (QOL). However, 6 months after thalamotomy, the patient died of pancreatic cancer.

**Conclusion:** Thalamotomy significantly reduced the involuntary movements immediately after the procedure. Therefore, thalamotomy can be performed under local anesthesia without the use of any device and may contribute to the improvement of QOL in terminal patients.

**Keywords:** Functional neurosurgery, Holmes tremor, Palliative care, Radiofrequency, Thalamotomy

## INTRODUCTION

Holmes tremor (HT) is generally associated with cerebellum lesions, the midbrain, or the thalamus.<sup>[4,7]</sup> Due to the paucity of effective treatment options,<sup>[1,10]</sup> some patients are referred for surgery.<sup>[18]</sup> Although thalamotomy has been reported as a type of lesion therapy for pain relief in late-stage cancer,<sup>[5]</sup> HT tends to recur after the procedure and there are limited reports on surgical procedures to improve daily activity. Furthermore, the number of computed tomography (CT)-guided thalamotomies is limited because they are classical and currently, magnetic resonance imaging (MRI)-guided thalamotomies are mainstream. Here, we present a case report of a patient with HT due to thalamic infarction with end-stage pancreatic cancer and a cardiac pacemaker

This is an open-access article distributed under the terms of the Creative Commons Attribution-Non Commercial-Share Alike 4.0 License, which allows others to remix, transform, and build upon the work non-commercially, as long as the author is credited and the new creations are licensed under the identical terms.

©2022 Published by Scientific Scholar on behalf of Surgical Neurology International

who underwent a rare but successful CT-guided ventralis intermedius nucleus (Vim) thalamotomy as palliative care.

## CASE REPORT

A 78-year-old man with a history of a pacemaker implantation for chronic atrial fibrillation not compatible with MRI and in the process of chemotherapy for pancreatic cancer visited our department complaining of severe left-sided tremors. He had a right thalamic infarction 2 years before his visit and developed involuntary movements and dysesthesia on the left side of his body a few months later. As involuntary movements gradually aggravated and started interfering with his daily life, the patient was referred to our department for treatment. At the patient's request, surgical treatment for symptom relief was considered. Although the prognosis for pancreatic cancer was considered to be more than 6 months at the time of surgery, we performed CT-guided Vim thalamotomy under local anesthesia without pulse generator implantation considering the patient's general condition.

Stereotactic CT scan with contrast was preoperatively used to identify the target and plan a safe trajectory to avoid blood vessels on the brain surface and around the ventricles. We targeted the area near the middle frontal gyrus that is at the lower end of the convergence range. The boundary between the posterior internal capsule and thalamus was aimed and targets were determined based on the site of infarction within the thalamus.

The preoperative stereotactic targeting (tip of the electrode) coordinates relative to the mid-commissural point and trajectory angles were as follows: 10.5 mm to the right, 5.5 mm posterior, 1.0 mm superior, anterior commissure-posterior commissure angle of 67.3°, and coronal plane angle of 28.5° to the right. Since the CT scan has difficulty showing a high-resolution structural image, we used the previous thalamic infarction as a landmark of the ventralis caudalis (Vc) nucleus and the border between the thalamus and the internal capsule. The tentative trajectory was aimed at the Vc/Vim border.<sup>[12]</sup>

On the morning of surgery, a Leksell G frame (Elekta, Stockholm, Sweden) was attached to the patient's head under local anesthesia, and subsequently stereotactic CT scan was performed. After a 4-cm straight skin incision, a burr hole was fashioned along the trajectory. Following dural opening, a thermocoagulation electrode was inserted to the target. Subsequently, macrostimulation was performed using 1-mm diameter, 4-mm length electrodes at 100  $\mu$ s, 133 Hz up to 5 mA to confirm that no adverse effects occurred followed by radiofrequency coagulation at 70°C for 60 s. Another radiofrequency lesion was made along the trajectory, 2 mm anterior and 1 mm medial to the

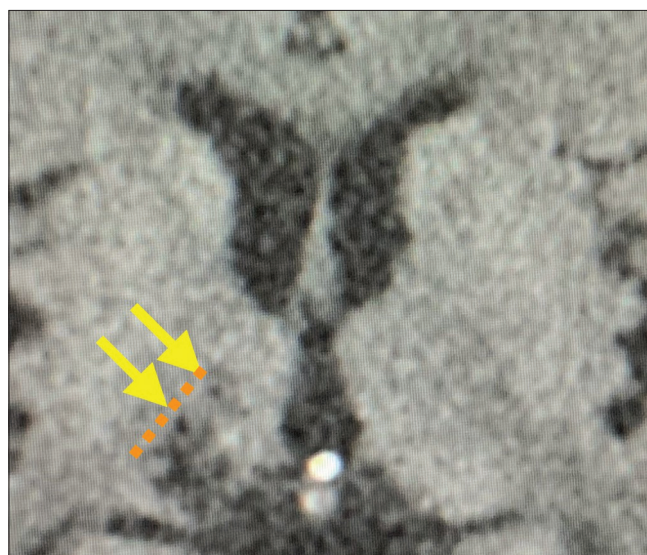
first lesion aiming at the border between the Vim and the ventralis oralis nucleus.

Following the surgery, the involuntary movements of the left side of the body reduced although ataxia remained. Postoperative CT showed an appropriate lesion in the right thalamus [Figure 1]. However, 6 months after surgery, the patient died of pancreatic cancer.

## DISCUSSION

Although long-term follow-up was not performed, stereotactic thalamotomy was considered to be successful in the reported patient. Based on the previous papers, it is suggested that a larger lesion of the thalamotomy was more effective than a smaller lesion.<sup>[6,13]</sup> We attempted to coagulate the wide areas of ventrolateral nucleus with two lesions without significant adverse events such as paresthesia or motor weakness.

We conducted a literature search for all previous case reports and clinical research published in English on HT treated with thalamotomy since the Consensus Statement of the Movement Disorder Society coined the current definition of HT in 1998. PubMed, MEDLINE, and other databases such as OvidSP were searched using the following keywords: "radiofrequency thalamotomy" and "HT," "rubral or midbrain tremor," or "cerebellar outflow tremor." Four reports and six cases of HT treated with radiofrequency thalamotomy have been reported [Table 1].<sup>[8,11,15,16]</sup> These six cases included three men and three women, with a mean age of 40.1 years. The most common etiology was stroke



**Figure 1:** Postoperative image showing two lesions in the thalamus (yellow arrows) anterior to the previous infarction area. Orange dotted line indicates the border between the internal capsule and the thalamus.

**Table 1:** Summary of radiofrequency thalamotomy for Holmes tremor as reported in the literature.

Authors and Year	No. of Patients	Sex	Age at CNS lesion	HT Etiology	Clinical Outcome Scale	Target	Preoperative stereotactic coordinate* (X/Y/Z)	Outcome	Follow-up period
Kim <i>et al.</i> , 2002	1	M	26	Midbrain Germinoma	None	Rt. Vim	(15.0/-5.0/0)	resting and postural tremors markedly improved, a mild kinetic tremor remained	14 months
Maki <i>et al.</i> , 2015	1	F	57	Pontine hemorrhage	CRST	Lt. Vim	(15.5/-5.5/3.0)	resting tremor stopped, kinetic tremor recurred 6 months following surgery	6 months
Raina <i>et al.</i> , 2016	3	M	50	Cerebellar MS	None	Lt. Vim	Not mentioned	tremor markedly improvement	Not mentioned
		M	18	Midbrain stroke	None	Lt. Vim	Not mentioned	tremor markedly improvement	Not mentioned
		F	9	Thalamus stroke	None	Lt. Vim	Not mentioned	tremor markedly improvement, not improved in the dystonic posture of the right hand	Not mentioned
Oliveira <i>et al.</i> , 2017	1	F	43	HIV-associated midbrain lesion	None	Rt. Vim	Not mentioned	immediate complete resolution of tremor	6 months
Present Case	1	M	78	Thalamus stroke	None	Lt. Vim	(10.5/-5.5/-1.0)	Involuntary movements reduced following surgery	6 months

CNS: Central nervous system, HT: Holmes tremor, Vim: Ventralis intermedius nucleus, CRST: Clinical rating scale for tremor, MS: Multiple sclerosis, HIV: Human immunodeficiency virus. \*The preoperative stereotactic targeting (tip of the electrode) coordinates relative to the mid-commissural point.

(one in the midbrain and one in the thalamus). In all the reports, Vim thalamotomy was performed, which included four on the left and two on the right side of the brain. The postoperative follow-up period ranged from 6 to 14 months. The clinical course of each case showed that in all cases, the tremor improved after surgery, and only one case showed recurrence of tremor 6-month postoperatively.<sup>[11]</sup> Long-term outcomes of thalamotomy in HT have not been reported; however, Bargiotas *et al.* reported long-term outcomes of deep brain stimulation (DBS) in HT, which showed that in three of four patients, the improvement of tremor did not sustain longer than 2–3 years and only one patient remained

tremor free for up to 9 years.<sup>[2]</sup> In addition, at the 3-year follow-up after DBS, activities of daily living (ADL) scale scores in three of four patients worsened compared to those at baseline. Considering our literature review and the results of this study, thalamotomy can be considered as the surgical treatment of choice for HT instead of DBS. However, such cases are rare, and further investigations are needed to reveal the long-term outcomes of thalamotomy in HT and its comparison with DBS.

As the previous literature indicated, lesion therapy is considered to be a reasonable option in terminal cases. Keep *et al.* reported thalamotomy with gamma-knife surgery

for the palliative management of thalamic pain.<sup>[9]</sup> They concluded that thalamotomy is a safe and effective treatment that provides durable symptom control and improved the quality of life (QOL). Radiofrequency thalamotomy and gamma-knife thalamotomy cannot be considered the same because they differ in invasiveness and time to effect; in general, gamma-knife thalamotomy takes longer to show its effect.<sup>[14,17]</sup> In contrast, focused ultrasound thalamotomy is a new modality of tremor treatment that has potential in transcranial therapeutic manipulation, immediate efficacy, and procedural targeting. Since the simplicity and efficacy of focused ultrasound thalamotomy have been reported, it has the potential to be an alternative treatment to radiofrequency thalamotomy in cases such as the present one.<sup>[3]</sup> If the goal is palliative care, such as symptom control and QOL maintenance, radiofrequency thalamotomy may be useful because it excludes the risk of infection due to the insertion of a foreign body and decrease in QOL caused by the implantation of a pulse generator. In our case, the patient was in the late stage of pancreatic cancer, and the tremors of the left side of the body due to HT was the cause of the decline in his ADLs; therefore, Vim thalamotomy was performed at the patient's request. As MRI was impossible due to the pacemaker implanted in the patient, CT-guided Vim thalamotomy under local anesthesia was performed, following which the postoperative ADL improved, contributing greatly to the improvement of the patient's QOL in the terminal stage.

## CONCLUSION

We report a case of Vim thalamotomy for thalamic infarction-induced HT that showed significant improvement in tremors immediately after the procedure. According to the literature, the Vim thalamotomy outcome is acceptably favorable. The procedure can be safely performed under local anesthesia without the use of any device; hence, thalamotomy may contribute to the improvement of QOL in terminal patients.

## Acknowledgment

Consent to publish statement: Additional informed consent was obtained from the patient for whom identifying information was included in this study.

## Declaration of patient consent

The authors certify that they have obtained all appropriate patient consent.

## Financial support and sponsorship

This study was partly supported by Japan Society for the Promotion of Science (JSPS) Grant-in-Aid for Scientific Research (C) (Grant number: 18K08956).

## Conflicts of interest

There are no conflicts of interest.

## REFERENCES

1. Akkus DE, Diramali AB. Postischemic delayed Holmes' tremor responding to low-dose cabergoline. *Mov Disord* 2006;21:733-4.
2. Bargiotas P, Nguyen TA, Bracht T, Mürset M, Nowacki A, Debove I, *et al.* Long-term outcome and neuroimaging of deep brain stimulation in Holmes tremor: A case series. *Neuromodulation* 2021;24:392-9.
3. Dallapiazza RF, Lee DJ, De Vloot P, Fomenko A, Hamani C, Hodaie M, *et al.* Outcomes from stereotactic surgery for essential tremor. *J Neurol Neurosurg Psychiatry* 2019;90:474-82.
4. Deuschl G, Bain P, Brin M. Consensus statement of the movement disorder society on tremor. *Mov Disord* 1998;13:2-23.
5. Haddad AR, Hayley J, Mostofi A, Brown M, Pereira E. Stereotactic radiofrequency thalamotomy for cancer pain: A systematic review. *World Neurosurg* 2021;151:225-34.
6. Hirai T, Miyazaki M, Nakajima H, Shibasaki T, Ohye C. The correlation between tremor characteristics and the predicted volume of effective lesions in stereotaxic nucleus ventralis intermedialis thalamotomy. *Brain* 1983;106:1001-18.
7. Holmes G. On certain tremors in organic cerebral lesions. *Brain* 1904;27:327-75.
8. Kim MC, Son BC, Miyagi Y, Kang JK. Vim thalamotomy for Holmes' tremor secondary to midbrain tumour. *J Neurol Neurosurg Psychiatry* 2002;73:453-5.
9. Keep MF, Mastrofrancesco L, Craig AD, Ashby LS. Gamma knife surgery targeting the centromedian nucleus of the thalamus for the palliative management of thalamic pain: Durable response in stroke-induced thalamic pain syndrome. *J Neurosurg* 2006;105:222-8.
10. Liou LM, Shih PY. Successful treatment of rubral tremor by high-dose trihexyphenidyl: A case report. *Kaohsiung J Med Sci* 2006;22:149-53.
11. Maki F, Sato S, Watanabe K, Yanagisawa T, Hagiwara Y, Shimizu T, *et al.* Vim thalamotomy in a patient with Holmes' tremor and palatal tremor-pathophysiological considerations. *BMC Neurol* 2015;15:26.
12. Morishita T, Higuchi MA, Kobayashi H, Abe H, Higashi T, Inoue T. A retrospective evaluation of thalamic targeting for tremor deep brain stimulation using high-resolution anatomical imaging with supplementary fiber tractography. *J Neurol Sci* 2019;398:148-56.
13. Morishita T, Tsuboi Y, Higuchi MA, Inoue T. Is one large target better than two? *J Neurosurg* 2015;123:1349-50.
14. Niranjana A, Jawahar A, Kondziolka D, Lunsford LD. A comparison of surgical approaches for the management of tremor: Radiofrequency thalamotomy, gamma knife thalamotomy and thalamic stimulation. *Stereotact Funct Neurosurg* 1999;72:178-84.
15. Oliveira JO Jr., Cecilio SA, Oliveira M, Takahashi LR, Galassi AR, Holanda VM, *et al.* VIM thalamotomy in the treatment of Holmes' tremor secondary to HIV-

- associated midbrain lesion: A case report. *J Neurosurg Sci* 2017;61:544-6.
16. Raina GB, Cersosimo MG, Folgar SS, Giugni JC, Calandra C, Paviolo JP, *et al.* Holmes tremor: Clinical description, lesion localization, and treatment in a series of 29 cases. *Neurology* 2016;86:931-8.
17. Tripathi M, Mehta S, Singla R, Ahuja CK, Tandalya N, Tuleasca C, *et al.* Vim stereotactic radiosurgical thalamotomy for drug-resistant idiopathic Holmes tremor: A case report. *Acta Neurochi (Wien)* 2021;163:1867-1.
18. Wang KL, Wong JK, Eisinger RS, Carbutaru S, Smith C, Hu W, *et al.* Therapeutic advances in the treatment of Holmes tremor: Systematic review. *Neuromodulation* 2022;25:796-803.

**How to cite this article:** Oda K, Morishita T, Tanaka H, Kobayashi H, Abe H. Case report: Radiofrequency thalamotomy as palliative care for Holmes tremor in a patient with terminal cancer and cardiac pacemaker. *Surg Neurol Int* 2022;13:484.

## Commentary

The authors of this report went an extra mile to help the patient with disabling post-stroke tremor. Although there were many possible reasons to deny surgery (the advanced age, terminal disease, inability to have MRI), they decided to give the patient a chance for living the rest of his life (ended up being 6 months) with significant improvement in symptoms through a very elegant intervention performed under local anesthesia. The approach and the modality they used has been described in the past, but since the relative rarity of this condition precludes one from putting together a large clinical series, it would be worthwhile to review this case as it describes something that was probably the only reasonable way to manage this particular individual case. Instead of finding many excuses not to help this patient, the authors used a time-tested intervention (radiofrequency thalamotomy for tremor by far precedes currently used deep brain stimulation and MR-guided focused ultrasound thalamotomy) that is remarkably safe if performed by an experienced team.

Konstantin Slavin, Chicago, Illinois  
University of Illinois at Chicago; Chicago, IL, USA  
kslavin@uic.edu

## Disclaimer

The views and opinions expressed in this article are those of the authors and do not necessarily reflect the official policy or position of the Journal or its management. The information contained in this article should not be considered to be medical advice; patients should consult their own physicians for advice as to their specific medical needs.