ScientificScholar®
Knowledge is power
Publisher of Scientific Journals

www.surgicalneurologyint.com

Surgical Neurology International

Editor-in-Chief: Nancy E. Epstein, MD, Clinical Professor of Neurological Surgery, School of Medicine, State U. of NY at Stony Brook.

SNI: Skull Base

Editor
Mitsutoshi Nakada, MD
Kanazawa University, Ishikawa, Japan

SNI
Open Access

*Case Report*

# Stereotactic radiosurgery for skull base adenoid cystic carcinoma: A report of two cases

Yuki Nakamura[1], Motoyuki Umekawa[1], Yuki Shinya[1], Hirotaka Hasegawa[1], Masahiro Shin[2], Atsuto Katano[3], Aya Shinozaki-Ushiku[4], Kenji Kondo[5], Nobuhito Saito[1]

[1]Department of Neurosurgery, The University of Tokyo Hospital, [2]Department of Neurosurgery, Teikyo University Hospital, Departments of [3]Radiology, [4]Pathology and [5]Otorhinolaryngology, The University of Tokyo Hospital, Tokyo, Japan.

E-mail: Yuki Nakamura - tomason0111@gmail.com; *Motoyuki Umekawa - moto.umekawa@gmail.com; Yuki Shinya - yukishinya6155@gmail.com; Hirotaka Hasegawa - hirotaka.hasegawa@ymail.ne.jp; Masahiro Shin - shin.masahiro.rk@teikyo-u.ac.jp; Atsuto Katano - djdcc558@ybb.ne.jp; Aya Shinozaki-Ushiku - aya0619@gmail.com; Kenji Kondo - kondok-tky@umin.ac.jp; Nobuhito Saito - nsaito-nsu@m.u-tokyo.ac.jp

***Corresponding author:**
Motoyuki Umekawa,
Department of Neurosurgery,
The University of Tokyo
Hospital, Tokyo, Japan.

moto.umekawa@gmail.com

Received : 27 July 2022
Accepted : 19 October 2022
Published : 04 November 2022

**DOI**
10.25259/SNI_675_2022

**Quick Response Code:**

## ABSTRACT

**Background:** Adenoid cystic carcinoma (ACC) is an uncommon salivary gland tumor with a relatively favorable prognosis. However, treating ACC is potentially challenging because radical resection is usually difficult once the skull base is involved due to the adjacent critical structures. Stereotactic radiosurgery (SRS) is a less invasive alternative for surgically recalcitrant lesions.

**Case Description:** We report two patients with three metastatic skull base ACCs who underwent SRS using the Gamma Knife with a marginal dose of 20 Gy to a 50% isodose line. All tumors were effectively controlled without any adverse events.

**Conclusion:** This case report and our review of the literature suggest that SRS can be considered for local control of ACC invading the skull base when surgical resection is unsuitable or a postoperative residual lesion is suspected. Further, investigations on the accumulated subjects are warranted to confirm the role of SRS for the treatment of ACCs.

**Keywords:** Adenoid cystic carcinoma, Case report, Recurrence, Skull base, Stereotactic radiosurgery

## INTRODUCTION

Adenoid cystic carcinoma (ACC) accounts for only ~1% of head and neck malignancies; it typically arises from salivary glands.[4] The 5-year overall survival rate is approximately 90%; however, the cumulative risks of local recurrence and metastases are 40% and 40–60%, respectively.[3,4,6,7,9,11,20,21] Although, surgical resection is the mainstay primary treatment for ACC,[2,3,6,21] the main approach for ACC undergoing subtotal or partial resection is postoperative fractionated radiotherapy as a radical intent almost regardless of location.[1,2,16,22] Same applies to recurrent lesions, radiotherapy is the main approach with systemic treatment (chemo and targeted therapy) having a limited role. Radiotherapy has been suggested not only as a radical treatment for patients who undergo subtotal resection but also as a palliative treatment for patients who cannot undergo surgery.[2,3,22] Metastatic ACC rarely occurs in the skull base; however, as the main tumor often extends alongside critical neurovascular structures,

gross total resection with neurological preservation is challenging.[17,20]

Stereotactic radiosurgery (SRS) comprises focused high-dose irradiation at a single session. It yields 1-year local control of 60–90% of malignant metastatic brain tumors and is efficacious in the treatment of brain metastases and skull base tumors.[14,19,23] However, evidence regarding SRS for skull base ACC is lacking. Herein, we report on successful SRS of two patients with metastatic skull base ACCs.

## CASE PRESENTATIONS

### Case 1

A 50-year-old man with a nosebleed was referred to our hospital. He had a medical history of pituitary adenoma which was totally resected at the age of 17 without recurrence, myocardial infarction, hypertension, and dyslipidemia. Magnetic resonance imaging (MRI) revealed a heterogeneously enhanced tumor extending from the nasal cavity to the suprasellar region [Figure 1a]. Since, computed tomography (CT) scan for the investigation of the neck, chest, and abdomen showed no evidence of the tumor, we considered the skull base lesion as the primary. The tumor was pathologically confirmed as ACC through transnasal biopsy [Figure 1b], and an endoscopic endonasal approach was used for gross total resection. However, 2 years after the surgery, MRI revealed tumor recurrence in the right pterygopalatine fossa, and a second resection was performed. Four years later, local recurrence was observed in the right superior orbital fissure [Figure 1c]. Therefore, we performed SRS with a prescription dose of 20 Gy to a 50% isodose line using the Gamma Knife ICON with Leksell frame head-fixation (Elekta AB, Stockholm, Sweden; [Figures 1c-e]). Since the patient was blind in the right eye after surgery for a pituitary adenoma at age 20, we were not concerned about radiation injury to the optic nerve; the mean and maximal radiation exposures to the optic chiasm were 2.0 and 3.3 Gy, respectively. One year later, local tumor remission was confirmed through serial MRI; however, remote metastasis was detected in the parapharyngeal space. Although the metastasis was resected through an endoscopic endonasal approach, marginal tumor recurrence was observed in the parapharyngeal space [Figure 1f]. We performed a second SRS with the same marginal dose, isodose line, and procedure as for the first SRS [Figures 1f-h]. At 36 months after the first SRS and 9 months after the second SRS, complete local remission was maintained for both tumors, and no radiation necrosis was observed [Figures 1i-k].

### Case 2

A 56-year-old woman with the right facial numbness and trigeminal neuralgia was referred to our hospital. She had a medical history of gastric cancer which was treated with surgery 7 years before her visit and showed no recurrence. MRI revealed a large tumor extending from the orbit to the cavernous sinus. We considered this skull base lesion as the primary site, because the initial whole body-CT scan revealed no evidence of any tumor. It was resected and pathologically confirmed as ACC arising from the lacrimal gland [Figure 2a]. Despite upfront adjuvant radiotherapy (70 Gy in 35 fractions) to the surgical cavity in conjunction with systemic chemotherapy with cisplatin, local recurrence with multiple lung metastases was confirmed in 2 years, causing right visual loss. The tumors in the right cavernous sinus were resected repeatedly along with subsequent systemic chemotherapy (using docetaxel), but further recurrence was confirmed in the right anterior skull base [Figure 2b]. Eventually, we decided to continue chemotherapy for control of the lung lesions and to attempt SRS for maximum control of the skull base lesions since they were already irradiated. SRS with a prescription dose of 20 Gy to a 50% isodose line was performed using the Gamma Knife 4C (Elekta) with frame head fixation [Figures 2b-d]. Although remarkable tumor shrinkage was achieved without any radiation necrosis in 5 months [Figure 2e], the patient died of multiple organ failure due to the systemic spread of ACC. A summary of the two cases is provided in Table 1.

## DISCUSSION

We reported on two cases of skull base metastatic ACCs that were successfully controlled with SRS without significant adverse radiation effects. Patients with ACCs have a relatively favorable prognosis even with metastatic tumors; the 5-, 10-, and 15-year survival rates for all stages of ACCs are 90%, 80%, and 69%, respectively.[9,11,21] Therefore, tumor control and preservation of neurological function should be balanced when treating patients with metastatic ACC. Due to the rarity of ACC, available evidence on SRS for skull base metastases of ACCs is quite limited [Table 2]. Mori *et al.*[12] treated 12 patients with skull base ACCs with a Gamma Knife. Among the 15 lesions, the crude local tumor control rate was 87%, with no adverse radiation effects in any of the cases. Although six patients died of other metastases at the end of the follow-up period, only one died of skull base tumor progression after SRS. Phan *et al.*[15] achieved local tumor control with a Gamma Knife boost at a prescription dose of 10 Gy in conjunction with fractionated radiotherapy in a patient with recurrent parotid gland ACC invading the fallopian canal. For all three lesions in this study, SRS yielded excellent local control without significant complications, which is consistent with the previous studies. Hence, SRS may be suitable for the purpose of local tumor control. Considering ACC's malignant nature and potential

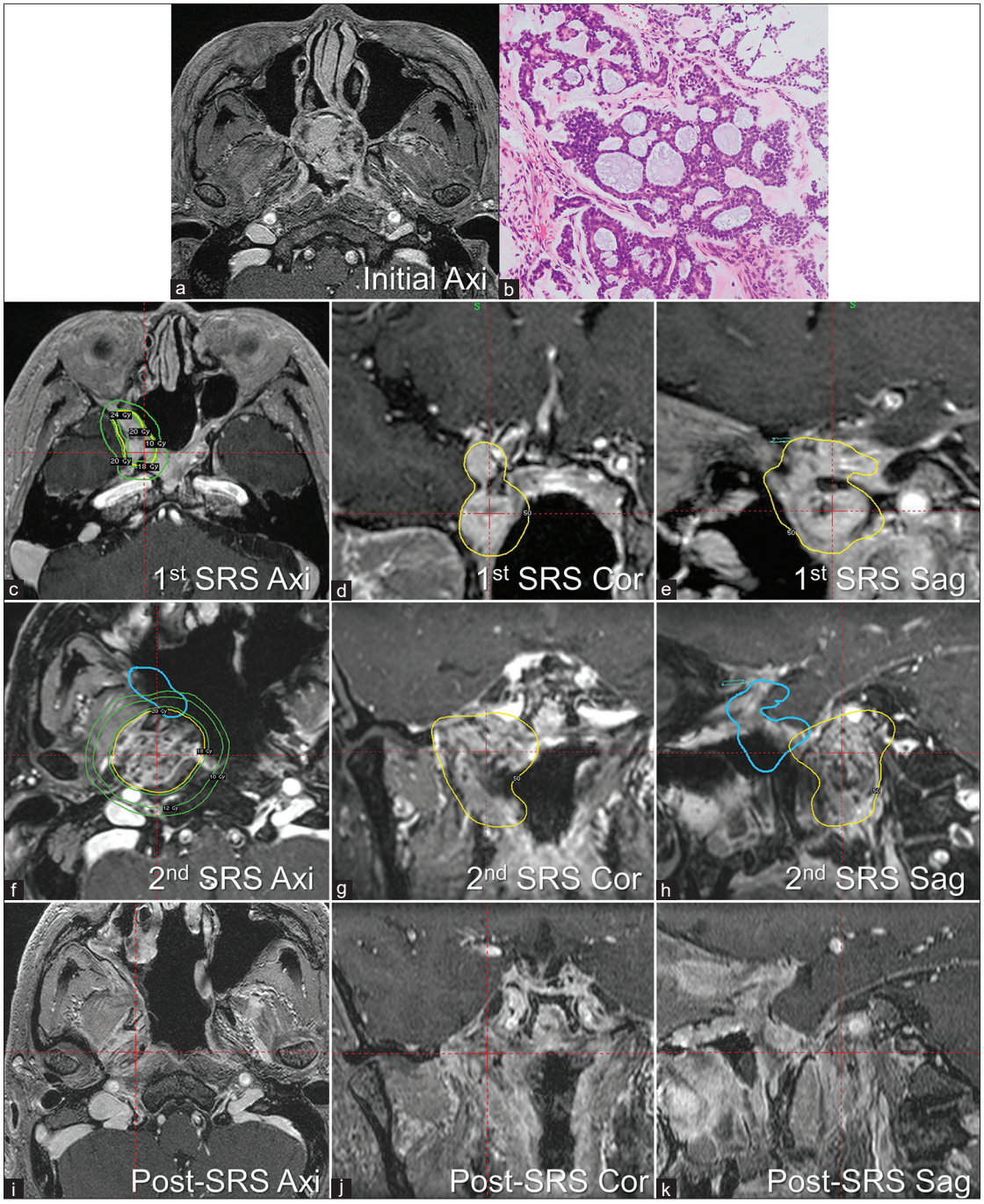


**Figure 1:** Adenoid cystic carcinoma (ACC) in a 50-year-old man (Case 1). Gadolinium-enhanced, T1-weighted magnetic resonance, imaging revealed an enhanced tumor extending from the nasal cavity to the suprasellar region (a). The tumor was pathologically confirmed as ACC, exhibiting cribriform growth with myoepithelial differentiation (b). After two resections, he experienced recurrence in the superior orbital fissure, at age 56, and stereotactic radiosurgery (SRS) was performed with a marginal dose of 20 Gy to a 50% isodose line (yellow line) in axial (c), coronal (d), and sagittal plane (e) Green lines indicated marginal dose line of 10 Gy, 18 Gy, and 24 Gy. A remote metastasis was detected in the parapharyngeal space, with marginal recurrence after its resection. We performed the second SRS for the parapharyngeal metastasis with the same parameters and the planning was shown in axial (f), coronal (g), and sagittal plane (h) with the previous planning in blue line. Yellow line indicated 20 Gy to a 50% isodose line, and green lines indicated marginal dose line of 10 Gy, 12 Gy, and 18 Gy. Both lesions were in remission at the last follow-up: 36 months after the first SRS for recurrence in the superior orbital fissure and 9 months after the second SRS for recurrence in the parapharyngeal space (i-k).

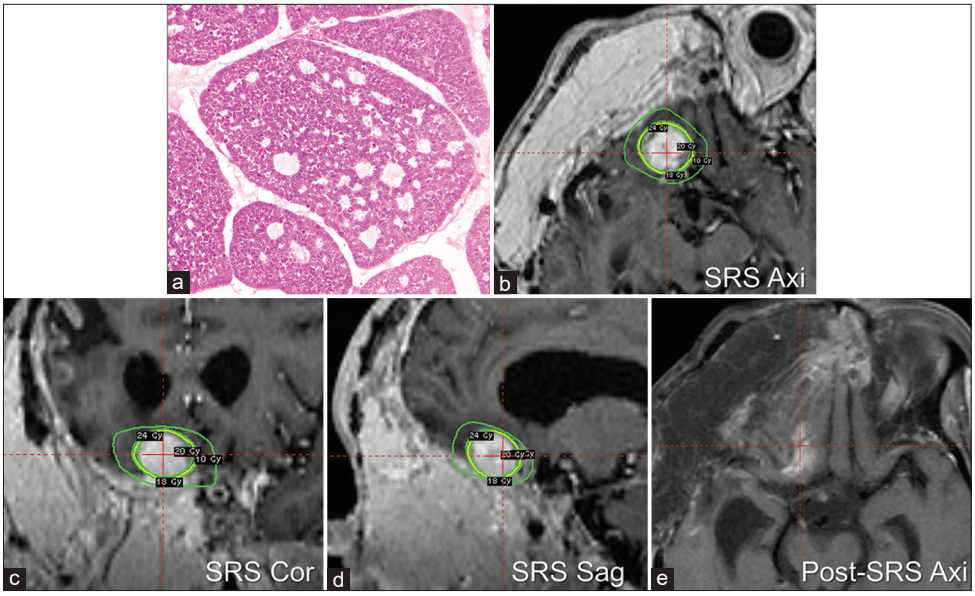


**Figure 2:** A 56-year-old woman underwent resection for a tumor growing next to the right orbit and the anterior skull base (Case 2). The tumor was pathologically diagnosed as adenoid cystic carcinoma arising from the lacrimal gland (a). Despite repeated resection, she experienced recurrence around the right cavernous sinus and orbit. We performed stereotactic radiosurgery for the anterior skull base metastasis, with a marginal dose of 20 Gy to a 50% isodose line (yellow line) in axial (b), coronal (c), and sagittal plane (d) Green lines indicated marginal dose line of 10 Gy, 18 Gy, and 24 Gy. The tumor shrank considerably in the next 5 months (e).

**Table 1:** Summary of SRS for skull base metastases of ACCs.

| Case | Age | Sex | Location of skull base metastasis | Other metastases | Symptoms | Maximum tumour size | Prescription dose (isodose line) | Systemic treatment | Tumor response | Survival after SRS |
|---|---|---|---|---|---|---|---|---|---|---|
| 1 | 56 | M | Superior orbital fissure | None | Facial dysesthesia | 38 mm | 20 Gy (50%) | None | CR | 36 months |
| 1 | 58 | M | Parapharyngeal space | None | Facial dysesthesia, visual impairment | 35 mm | 20 Gy (50%) | None | PR | 9 months |
| 2 | 59 | F | Anterior skull base | Lungs | Visual loss | 18 mm | 20 Gy (50%) | Cisplatin, docetaxel | PR | Death at 5 months[a] |

ACC: Adenoid cystic carcinoma, CR: Complete response, F: Female, M: Male, PR: Partial response, SRS: Stereotactic radiosurgery. [a]The patient died of multiple organ failure; the skull base lesion was controlled after SRS

invasiveness to the surrounding anatomical structure, we used the prescription dose of 20 Gy with an additional 1-mm margin to the tumor (i.e., planning target volume equals gross tumor volume plus 1 mm), although the Leksell frames were used for head fixation. Based on the result from Mori *et al.*,[12] we might achieve favorable tumor control with a prescription dose lower than 20 Gy, especially in case, the tumor is large or close to critical structures.

The minimally invasive nature and low rate of treatment-associated complications of SRS can be a major benefit for ACC, in which frequent local recurrence is a major issue. Although surgical removal is the standard treatment for the primary tumors, the optimal strategy for recurrent ACC remains to be determined. Given the possibility of various perioperative complications,[5,10,13,18] SRS can be a good alternative, leading to a reduction of repeat surgeries. Due to the nature of localized, highly focused radiation, SRS can also be used in patients who underwent high-dose fractionated radiotherapy.[8] In some instances, this feature may lead to post-SRS out-of-field recurrences, but such relapses can be treated with repeat SRS as in Case 1, taking advantage of the minimally invasive nature. However, further studies with long-term follow-up are required to monitor late recurrence as well as late adverse events.

**Table 2:** Review of the previous studies on SRS for skull base metastases of ACCs.

| Authors (year) | Modality | Patients (lesions) | Age, median (range) | Location (N) | Prescription dose, median (range) | Tumor volume, median (range) | F/U median (range) | LCR (crude rate) | AREs (crude rate) | Overall survival (crude rate) |
|---|---|---|---|---|---|---|---|---|---|---|
| Mori *et al.* (2005)[12] | GK | 12 (15) | 56 (17–79) | CP angle (2)<br>Orbit (2)<br>Parasellar (4)<br>Others (7) | 13 Gy (10–18) | 15 mL (2–103) | 18 months (3–55) | 87% | 0% | 50% |
| Phan *et al.* (2018)[15] | GK | 1 (1) | 44 | Geniculate ganglion, stylomastoid foramen | 10 Gy boost with EBRT (10) | 1 mL | 12 months | 100% | Hearing loss (100%) | 100% |
| Our study (2022) | GK | 2 (3) | 58 (56–59) | Anterior skull base (1)<br>Parapharyngeal fossa (1)<br>Superior orbital fissure (1) | 20 Gy (20–20) | 17 mL (7–21) | 9 months (5–36) | 100% | 0% | 50% |

ACC: Adenoid cystic carcinoma, AREs: Adverse radiation effects, EBRT: External beam radiation therapy, F/U: Follow-up period, GK: Gamma knife radiosurgery, LCR: Local tumor control rate, N: Number, SRS: Stereotactic radiosurgery

## CONCLUSION

We described two cases with three skull base metastases of ACC, for which we achieved successful local control with Gamma Knife-based SRS. SRS is a promising treatment option for skull base ACCs, both in terms of local control and functional preservation. Further, observations in more cases are required.

### Declaration of patient consent

The authors certify that they have obtained all appropriate patient consent.

### Financial support and sponsorship

JSPS KAKENHI (grant number: 20K17919).

### Conflicts of interest

There are no conflicts of interest.

## REFERENCES

1. Atallah S, Marc M, Schernberg A, Huguet F, Wagner I, Makitie A, *et al*. Beyond surgical treatment in adenoid cystic carcinoma of the head and neck: A literature review. Cancer Manag Res 2022;14:1879-90.
2. Cantu G. Adenoid cystic carcinoma. An indolent but aggressive tumour. Part B: Treatment and prognosis. Acta Otorhinolaryngol Ital 2021;41:296-307.
3. Coca-Pelaz A, Rodrigo JP, Bradley PJ, Vander Poorten V, Triantafyllou A, Hunt JL, *et al*. Adenoid cystic carcinoma of the head and neck--An update. Oral Oncol 2015;51:652-61.
4. Cohen AN, Damrose EJ, Huang RY, Nelson SD, Blackwell KE, Calcaterra TC. Adenoid cystic carcinoma of the submandibular gland: A 35-year review. Otolaryngol Head Neck Surg 2004;131:994-1000.
5. Dias FL, Sa GM, Kligerman J, Lopes HF, Wance JR, Paiva FP, *et al*. Complications of anterior craniofacial resection. Head Neck 1999;21:12-20.
6. Diaz EM Jr., Kies MS. Chemotherapy for skull base cancers. Otolaryngol Clin North Am 2001;34:1079-85, viii.
7. Ellington CL, Goodman M, Kono SA, Grist W, Wadsworth T, Chen AY, *et al*. Adenoid cystic carcinoma of the head and neck: Incidence and survival trends based on 1973-2007 surveillance, epidemiology, and end results data. Cancer 2012;118:4444-51.
8. Harris S, Chan MD, Lovato JF, Ellis TL, Tatter SB, Bourland JD, *et al*. Gamma knife stereotactic radiosurgery as salvage therapy after failure of whole-brain radiotherapy in patients with small-cell lung cancer. Int J Radiat Oncol Biol Phys 2012;83:e53-9.
9. Koka VN, Tiwari RM, van der Waal I, Snow GB, Nauta J, Karim AB, *et al*. Adenoid cystic carcinoma of the salivary glands: Clinicopathological survey of 51 patients. J Laryngol Otol 1989;103:675-9.
10. Kryzanski JT, Annino DJ, Gopal H, Heilman CB. Low complication rates of cranial and craniofacial approaches to midline anterior skull base lesions. Skull Base 2008;18:229-41.
11. Lorini L, Ardighieri L, Bozzola A, Romani C, Bignotti E, Buglione M, *et al*. Prognosis and management of recurrent and/or metastatic head and neck adenoid cystic carcinoma. Oral Oncol 2021;115:105213.
12. Mori Y, Kobayashi T, Kida Y, Oda K, Shibamoto Y, Yoshida J. Stereotactic radiosurgery as a salvage treatment for recurrent skull base adenoid cystic carcinoma. Stereotact Funct Neurosurg 2005;83:202-7.
13. Naunheim MR, Sedaghat AR, Lin DT, Bleier BS, Holbrook EH,

Curry WT, *et al.* Immediate and delayed complications following endoscopic skull base surgery. J Neurol Surg B Skull Base 2015;76:390-6.
14. Nieder C, Grosu AL, Gaspar LE. Stereotactic radiosurgery (SRS) for brain metastases: A systematic review. Radiat Oncol 2014;9:155.
15. Phan JL, Pollard C 3rd, Wang H, Ng SP, Sheu T, Ginsberg LE, *et al*. Dosimetric advantages of stereotactic radiosurgery as a boost to adjuvant conventional radiotherapy in the setting of adenoid cystic carcinoma of the parotid with skull base invasion. Clin Case Rep 2018;6:2126-30.
16. Sahara S, Herzog AE, Nor JE. Systemic therapies for salivary gland adenoid cystic carcinoma. Am J Cancer Res 2021;11:4092-110.
17. Shigematsu H, Magoshi S, Suzuki S, Kusama K, Sakashita H. An apparent radiation-induced carcinoma of the parotid gland following treatment for adenoid cystic carcinoma of the sublingual gland: A case report. J Oral Maxillofac Surg 2004;62:1169-74.
18. Sokoya M, Mourad M, Ducic Y. Complications of skull base surgery. Semin Plast Surg 2017;31:227-30.
19. Vogelbaum MA, Brown PD, Messersmith H, Brastianos PK, Burri S, Cahill D, *et al*. Treatment for brain metastases: ASCO-SNO-ASTRO guideline. J Clin Oncol 2022;40:492-516.
20. Wakisaka S, Nonaka A, Morita Y, Fukui M, Kinoshita K. Adenoid cystic carcinoma with intracranial extension: Report of three cases. Neurosurgery 1990;26:1060-5.
21. Wang L, Jia T, Zhao R, Zhu L, Zhang H. I 125 brachytherapy for central adenoid cystic carcinoma of the mandible. Oral and Maxillofac Surg Cases 2018;4:53-7.
22. Webb PS, Zhang YZ, Burrell K, Sinclair G. Adenoid cystic carcinoma and chronic lymphocytic leukaemia: Synchronous presentations in the lung. BMJ Case Rep 2021;14:e236074.
23. Yamamoto M, Serizawa T, Shuto T, Akabane A, Higuchi Y, Kawagishi J, *et al*. Stereotactic radiosurgery for patients with multiple brain metastases (JLGK0901): A multi-institutional prospective observational study. Lancet Oncol 2014;15:387-95.

**How to cite this article:** Nakamura Y, Umekawa M, Shinya Y, Hasegawa H, Shin M, Katano A, *et al*. Stereotactic radiosurgery for skull base adenoid cystic carcinoma: A report of two cases. Surg Neurol Int 2022;13:509.