



Original Article

Endoscopic endonasal transsphenoidal approach during COVID-19 pandemic in Brazil

Louise Ferreira Nascimento Pestana da Costa¹, Pedro Henrique Costa Ferreira-Pinto², Julia Pereira Muniz Pontes³, Ana Carolina Gonçalves Brito⁴, Bernardo Martins Rodrigues Martha¹, Wellerson Novaes da Silva¹, Victor Hugo Corrêa Rodrigues¹, Ana Beatriz Winter Tavares⁵, Elington Lannes Simões¹, Felipe Gonçalves de Carvalho¹, Flavio Nigri¹

¹Department of Neurosurgery, Universidade do Estado do Rio de Janeiro, ²Department of Neurosurgery, Pedro Ernesto University Hospital, ³Department of Surgical Specialties Neurosurgery Teaching and Assistance Unit, Universidade do Estado do Rio de Janeiro, ⁴Department of Anatomical Pathology, Pedro Ernesto University Hospital, ⁵Department of Internal Medicine - Endocrine Service, Pedro Ernesto University Hospital, Rio de Janeiro, Brazil.

E-mail: *Louise Ferreira Nascimento Pestana da Costa - lousepestanda31@gmail.com; Pedro Henrique Costa Ferreira-Pinto - pedrohcfp@gmail.com; Julia Pereira Muniz Pontes - juliamunizpontes@hotmail.com; Ana Carolina Gonçalves Brito - anacarolgbrito@gmail.com; Bernardo Martins Rodrigues Martha - bernardomrmartha@gmail.com; Wellerson Novaes da Silva - wellersonnovaess@gmail.com; Victor Hugo Corrêa Rodrigues - victor.c.rodrigues.med@gmail.com; Ana Beatriz Winter Tavares - anabeatrizwinter@yahoo.com.br; Elington Lannes Simões - elington.lannes@gmail.com; Felipe Gonçalves de Carvalho - felipegcarvalho@gmail.com; Flavio Nigri - flavionigri@gmail.com



***Corresponding author:**

Louise Ferreira Nascimento Pestana da Costa,
Department of Neurosurgery,
Universidade do Estado do Rio de Janeiro, Rio de Janeiro, Brazil.

lousepestanda31@gmail.com

Received : 27 August 2022
Accepted : 29 September 2022
Published : 04 November 2022

DOI
10.25259/SNI_786_2022

Quick Response Code:



ABSTRACT

Background: Endoscopic endonasal transsphenoidal approach (EETA) is a well-established technique for sellar tumor resection. However, this route causes aerosol dispersion from the nasal cavity. In the context of the coronavirus (COVID-19) pandemic, new measures were taken aiming at the safety and protection of patients and health-care professionals. Herein, we present a Brazilian experience with EETA during COVID-19 pandemic.

Methods: This study was based on the review of medical records and observation in the operating room of the patients undergoing endoscopic surgery in the period from May 2020 to July 2022. All patients were tested by real-time polymerase chain reaction (RT-PCR) COVID-19 before and after surgery. Since September 2021, it has been mandatory to present vaccination cards for adults (over 18 years old).

Results: This case series included 28 patients and 35 surgical procedures using the EETA, who presented of nonfunctioning macroadenomas (19 cases – 67.8%), GH-secreting tumor (three cases – 10.8%), ACTH-secreting tumor (three cases – 10.8%), meningiomas (two cases – 7.1%), and Rathke's cleft cyst (one case – 3.5%). There were eight cases of diabetes insipidus (28.5%), five cases of cerebrospinal fluid leak (17.8%), and one case of meningitis (3.5%). Three patients died due to meningitis (one case), carotid occlusion (one case), and COVID-19 complications (one case).

Conclusion: A simple protocol was established to perform EETA during the COVID-19 pandemic. The pituitary surgeries were maintained to treat critical cases. To date, the protocol should be continually updated to improve the procedure's safety.

Keywords: COVID-19, Pandemic, Pituitary, Transsphenoidal

INTRODUCTION

Endoscopic endonasal transsphenoidal technique is the main surgical approach for most types of sellar and suprasellar lesions. It is a less invasive procedure with less complications,

This is an open-access article distributed under the terms of the Creative Commons Attribution-Non Commercial-Share Alike 4.0 License, which allows others to remix, transform, and build upon the work non-commercially, as long as the author is credited and the new creations are licensed under the identical terms.

©2022 Published by Scientific Scholar on behalf of Surgical Neurology International

when compared to other approaches.^[21] Unfortunately, due to coronavirus (COVID-19) pandemic, there is a high risk of patient contamination with the virus and also staff contamination during airway manipulation procedures. Hence, the neurosurgery and skull base societies considered the open approach as an alternative solution.^[9] Due to the severity of the complications and limitations of open approach, it is important to weigh the risks and benefits of endoscopic endonasal transsphenoidal approach (EETA).^[13] Therefore, this article aims to describe the Brazilian experience with EETA during the COVID-19 pandemic.

MATERIALS AND METHODS

This case series described patients with pituitary lesions who underwent EETA from May 2020 to July 2022 in Pedro Ernesto University Hospital, Rio de Janeiro, Brazil. Because of the pandemic, only patients with a high risk of visual loss, severe hormonal dysfunction, apoplexy, or refractory headache were selected for surgery. The information used in this study was collected from the medical and surgical records, operating room (OR) observations, and pathology results.

A general safety protocol was established. The mandatory use of N95 for the professionals/patients inside the neurosurgery unit and the OR was implemented. In periods with increased COVID-19 cases, visits to hospitalized patients were suspended and all information were provided by video calls. Exceptions were made for hospital companions of patients under 18 s and over 65 s – with mandatory negative reverse transcriptase polymerase chain reaction (RT-PCR) for the COVID-19 test. The symptomatic or positive RT-PCR cases were isolated and transferred to internal COVID-19 units. Since September 2021, it has been mandatory to present vaccination cards for adults (over 18 years old). During the pandemic period, the staff and patients who presented respiratory symptoms or positive RT-PCR were submitted to a 10–14-day quarantine. It was possible to perform RT-PCR screening and avoid chest computed tomography (CT).

The surgical protocol was based on: (a) preoperative period: patient's screening with RT-PCR at least 3 days before hospital admission for all patients. The surgical procedure was performed on the following day, (b) intraoperative period: preparation used a different anesthetic induction that was based on the rapid sequence intubation. It was constituted in a reduced dose of opioids (fentanyl or remifentanyl) in the induction period, in addition to the lower doses of hypnotics (propofol and ketamine) and neuromuscular blockers (succinylcholine and rocuronium). Only the anesthesiologist was present in the OR during the intubation procedure. It was mandatory to use individual protection equipment, for example, gloves and cloak. A nasal drape (Steri-Drape, 3M,

Minnesota, United States) was used to reduce the nostril entry area [Figures 1a-d], and (c) postoperative period: due to the risk of nasopharynx swab after skull base procedures, the suspected cases were tested with oropharynx swabs. All other patients in the intensive care unit were regularly tested with RT-PCR.

RESULTS

This study described 28 patients and 35 surgical procedures using the EETA between May 2020 and July 2022. Data are resumed in Table 1. The age varied from 15 to 75 years old – average (56 years old)); 15 were male and 13 were female. The procedures included resection of (a) pituitary adenomas: nonfunctioning macroadenomas (19 cases – 67.8%), growth hormone-secreting tumor (three cases – 10.8%), ACTH hormone-secreting tumor (three cases – 10.8%); (b) meningiomas (two cases – 7.1%); and (c) Rathke's cleft cyst (one case – 3.5%). Nonetheless, 5 patients (17.8%) had to be submitted to a second procedure due to cerebrospinal fluid (CSF) fistula: one patient developed fatal meningitis despite CSF leak closure and the other four were successfully treated after antibiotic therapy and skull base surgery reconstruction. One patient (3.5%) died due to a right internal carotid artery infarct. Furthermore, 8 patients (28.5%) presented diabetes insipidus in the postoperative period requiring desmopressin. Fifteen patients (53.5%) had no complications.

There was one case of COVID-19-related complication: a 15-year-old boy diagnosed with Cushing disease (preoperative cortisol 63.4 µg/dL) was admitted and the magnetic resonance imaging of sella turcica exhibited a right

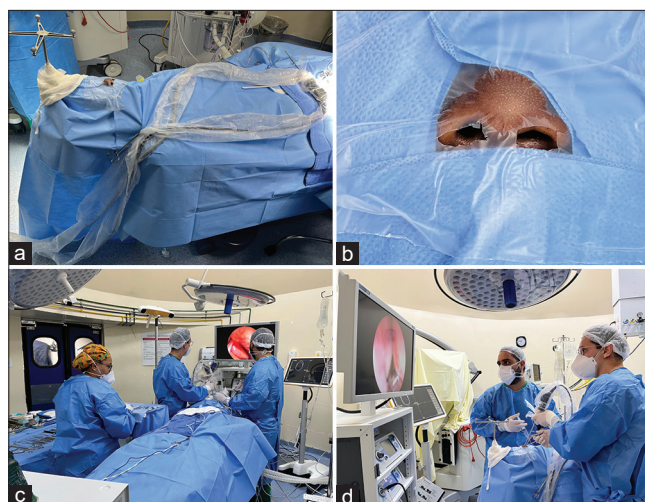

Figure 1: (a) Overview of patient preparation. During the perioperative period, the patient was covered by the nasal and surgical drapes. (b) Nasal drape was used to reduce the nostril. (c) All team members used N95 and surgical cloak. (d) The instruments were inserted through the reduced nostril.

Table 1: Detailed data of 28 patients that had endoscopic endonasal transsphenoidal approach during COVID-19 pandemic in Brazil.

Case number	Age-years / Gender	Manifestations	Hormonal secretion	Type of Tumor	Comorbidities	Resection	Complications	Reoperated	Outcome
1	67/M	Headache, nausea and reduced visual field	Non-functioning	Macroadenoma	-	Total	-	-	Complete recovery
2	38/F	Headache, nausea and reduced visual field	ACTH	Microadenoma	Diabetes	Total	Diabetes insipidus	-	Complete recovery
3	56/M	Bilateral hemianopia	Non-functioning	Macroadenomas	-	Total	-	-	Complete recovery
4	72/F	Unilateral Hemianopia	Non-functioning	Meningioma	-	Total	-	-	Complete recovery
5	75/F	Bilateral hemianopia	Non-functioning	Rathke's cleft cyst	Hipertension	Marsupialization	-	-	Complete recovery
6	66/F	Headache and Bilateral hemianopia	Non-functioning	Meningioma	Migrane	Total	CSF fistula / Diabetes insipidus	Once	Complete recovery
7	27/M	Symptoms of hypercortisolism	ACTH	Macroadenoma	Hipertension / Diabetes / Obesity	Total	-	-	Complete recovery
8	42/F	Early changes in the visual field	Non-functioning	Macroadenoma	Obesity	Total	-	-	Complete recovery
9	47/M	Growth of the hand (acromegaly)	GH	Macroadenoma	-	Total	Diabetes insipidus	-	Complete recovery
10	27/M	Bilateral hemianopia	Non-functioning	Macroadenoma	-	Total	Diabetes insipidus	-	Complete recovery
11	58/M	Bilateral hemianopia	Non-functioning	Macroadenoma	Hypothyroidism / Diabetes insipidus	Total	-	-	Complete recovery
12	15/M	Symptoms of Cushing	ACTH	Microadenoma	-	Partial	COVID-19	-	Death
13	22/M	Headache and hemianopia	Non-functioning	Macroadenoma	-	Total	CSF fistula	Once	Complete recovery
14	26/M	Amaurosis and mydriasis	Non-functioning	Macroadenoma	-	Total	Diabetes insipidus	-	Complete recovery
15	56/F	Early changes in the visual field	Non-functioning	Macroadenoma	Diabetes/ Glaucoma	Total	CSF fistula	-	Complete recovery
16	63/M	Peripheral visual loss	Non-functioning	Macroadenoma	-	Total	-	-	Complete recovery
17	56/F	Early changes in the visual field	Non-functioning	Macroadenoma	Deep vein thrombosis	Total	Diabetes insipidus	-	Complete recovery
18	65/M	Headache, reduced visual field and disorientation	Non-functioning	Macroadenoma	Hipertension / Diabetes / Obesity	Partial	Internal carotid artery injury - Ischemia	-	Death
19	72/F	Early changes in the visual field	Non-functioning	Macroadenoma	Hipertension / Diabetes / Colelitiasis	Total	CSF fistula / Meningitis	Once	Death

(Contd...)

Table 1: (Continued).

Case number	Age-years / Gender	Manifestations	Hormonal secretion	Type of Tumor	Comorbidities	Resection	Complications	Reoperated	Outcome
20	57/M	Headache, reduced visual field	Non-functioning	Macroadenoma	Hypothyroidism	Total	CSF fistula / Diabetes insipidus	Twice	Complete recovery
21	59/F	Headache, reduced visual field	Non-functioning	Macroadenoma	Hypothyroidism	Total	Diabetes insipidus	Once	Complete recovery
22	29/F	Headache, reduced visual field	Non-functioning	Macroadenoma	Polycystic ovary syndrome	Total	-	Once	Complete recovery
23	65/F	Bilateral hemianopia	GH	Microadenoma	-	Total	-	-	Complete recovery
24	54/F	-	GH	Macroadenoma	Hypertension	Total	-	-	Complete recovery
25	52/M	Headache, hypotension and eyelid ptosis	Non-functioning	Macroadenoma	-	Partial	-	-	Complete recovery
26	75/M	Reduced visual field	Non-functioning	Macroadenoma	Inguinal hernia / hypertension	Total	-	-	Complete recovery
27	65/M	Reduced visual field	Non-functioning	Macroadenoma	Diabetes mellitus / pancreatitis / gastric ulcer	Total	-	-	Complete recovery
28	46/F	Headache and reduced visual field	Non-functioning	Macroadenoma	Diabetes mellitus / migraine	Total	-	-	Complete recovery

nodular pituitary lesion, measuring 2.0×1.5 mm [Figure 2a]. His preoperative RT-PCR was negative. The patient underwent EETA and the postoperative basal serum cortisol was $9.0 \mu\text{g/dL}$. On the 4th postoperative day, he presented rhinorrhea, nasal congestion, and cough and his second RT-PCR was positive. The patient progressed with acute respiratory failure on the 10th postoperative day requiring orotracheal intubation. He developed bacterial pneumonia, septic shock, and renal failure. After 1 month, the patient was with a coma and the absence of brain reflexes. The cranial CT exhibited a large right frontal intraparenchymal hemorrhage with subfalcine herniation [Figure 2b]. Cardiorespiratory arrest occurred on the 57th postoperative day.

DISCUSSION

Some reference centers worldwide during the COVID-19 pandemic developed local protocols to perform ETTA safely. Most patients underwent urgent pituitary surgery due to chiasm compression, severe hormonal dysfunction, pituitary apoplexy, or refractory headache.^[7] The centers used the clinical history and the following strategies to investigate COVID-19 in the preoperative period: (a) RT-PCR alone,^[3,17,20] (b) blood test (IgM/IgG) and RT-PCR,^[14,24] (c) only chest CT,^[2,22] and (d) RT-PCR and chest.^[1] To reduce contamination in the OR, most groups used one surgical mask plus N95, face shields, eye protection, surgical gown, double surgical glove, and limited staff members presence.^[6] The literature collected data is summarized in Table 2.

Different surgical strategies were implemented in COVID-19-negative patients. Arnaout *et al.* (Egypt)^[2] prevented the dissemination of vapor or surgical debris using an extra suction tube inside the nostril. Barbosa *et al.* (Brazil)^[3] sealed the patient's head and trunk with a surgical microscope bag, leaving a small hole to insert the endoscopic instruments. Other groups used a negative pressure room (India and Japan)^[16,1] and a flexible suction catheter in the nasopharynx for passive smoke evacuation (India).^[16] The cranial consortium (United Kingdom and Ireland)^[5] reported the following protocol: the patients were wrapped in a plastic cover and instruments sealed with plastic drapes. Solari *et al.* (Italy)^[18] described the use of a latex endonasal surgery facial mask (namely, a nose lid) to seal the nostrils.

There were different protocols for COVID-19-positive patients: (a) simulation trainees before the skull base surgery;^[14] (b) negative pressure rooms or exclusive OR;^[23] (c) restricted personnel in the OR;^[15] (d) powered air-purifying respirators (PAPRs) during the procedures;^[11,4] (e) drapes on the patients head and face with an additional layer of transparent Steri-Drape;^[23] and (f) tracheal suction in the nasopharynx throughout surgery with additional standard suction tips used during drilling to reduce contamination.^[23]

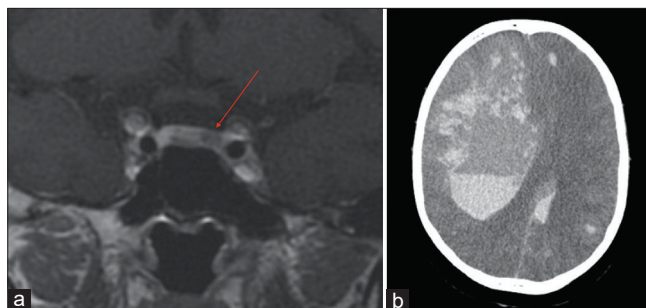


Figure 2: (a) Coronal sellar MRI - red arrow shows a left microadenoma. (b) Postoperative cranial computed tomography exhibiting a large intracranial hemorrhage - right frontal lobe. There are multiple other frontoparietal hemorrhagic foci and signs of subfalcine herniation.

Our surgical protocol was based on the previous data.^[3,5,6] There were applied different strategies for surgical procedures in the pre, peri, and postoperative period following previous guidelines.^[3,5,6,9] The RT-PCR before admission, anesthetic procedures, use of personal protective equipment, and reduction of nostril size with plastic cover were some of the measures implemented. Unfortunately, due to institutional resources limitations, it was not possible to add some devices as negative pressure rooms and PAPR.

Regarding surgical complications^[12,19] of endoscopic skull base surgery, we presented a higher rate of general complications compared to a pre-pandemic meta-analysis including 779 patients of 20 retrospective case series.^[8] The following complications observed in this case series compared to the meta-analysis were as follows: CSF leak (17.8% vs. 11.7%); diabetes insipidus (28.5% vs. 11.5%); and meningitis (3.5% vs. 1.8%), respectively. There was also a higher surgical mortality rate compared to Halvorsen *et al.* series,^[10] including 506 procedures (10.7% vs. 0.6%). Furthermore, there were no cases of postoperative hypopituitarism, increased visual defects, epistaxis, lower extremity deep vein thrombosis, or reoperation for hematoma.

To date, the surgical team implemented a recent aggressive strategy trying to achieve gross total resection. This includes an extended approach with a large sphenoid sinus/sellar floor opening; extensive tumor dissection raising the risk of sellar roof opening; and CSF fistula. To overcome these complications, especially the CSF leak, multiple layers for skull base reconstruction with nasoseptal flap and fat-fascia graft were used. Regarding the COVID-19 pandemic and skull base surgery, there are no definitive data about complications rates.

One patient suffered from COVID-19 4 days after the surgery. It was not possible to identify the infection source; however, as a pediatric patient, there was an obligation to have a companion during hospitalization increasing the patient exposure. To date, the companion admission

Table 2: Review of the literature data about endoscopic endonasal transsphenoidal approach during the COVID-19 pandemic: investigation, reported cases, complications, and staff contamination.

Authors/ Country/Year	Diagnosis	COVID-19 investigation	COVID-19-positive patients reported?	Complications reported	Staff contamination reported
Zhu <i>et al.</i> ^[24] China/2020	Pituitary adenoma	Blood test, screening for common lung infections, lung, and RT-PCR (postoperative)	Yes (postoperative)	Patient death	14 medical staffs
Mattogno <i>et al.</i> ^[14] Italy/2020	One sinonasal SCC, one recurrence of ethmoid adenocarcinoma, one clivus chordoma, one Rathke's cleft cyst, one expansive lesion of the clivus, and seven pituitary adenomas	Blood test and RT-PCR	No	CSF leak	No
Santos <i>et al.</i> ^[17] USA/2020	Pituitary macroadenoma	RT-PCR	Yes	No	No
Talmor <i>et al.</i> ^[19] USA/2020	Pituitary macroadenoma	Unknown	Yes (postoperative)	Nasoseptal flap necrosis and death from COVID-19	No
Solari <i>et al.</i> ^[18] Italy/2020	Pituitary apoplexy, chondrosarcoma, and pituitary macroadenoma	Temperature, blood test	Yes	No	No
Chan <i>et al.</i> ^[4] USA/2020	Pituitary apoplexy	RT-PCR	Yes (preoperative)	No	No
Arnaout <i>et al.</i> ^[2] Egypt/2020	Nine pituitary adenomas	Chest	No	CSF leak in two cases	No
Barbosa <i>et al.</i> ^[3] Brazil/2020	Nonfunctioning pituitary adenoma	RT-PCR	No	No	No
Akai <i>et al.</i> ^[1] Japan/2020	Prolactinoma	RT-PCR and chest	No	No	No
Cranial Consortium ^[5] UK and Ireland/2021	Pituitary adenomas (71%)	RT-PCR, TMA, or chest (94%)	No	DI, SIADH, and hyponatremia, CSF rhinorrhea, meningitis, sellar abscess, mono-ocular blindness, and residual disease.	No
Young <i>et al.</i> ^[23] USA/2021	One nonfunctioning macroadenoma; 1 sellar/suprasellar mass and 1 cystic pituitary macroadenoma	RT-PCR	Yes (postoperative)	Three patients were hospitalized for COVID-19 and two adrenal insufficiency and hyponatremia	No
Yoneoka <i>et al.</i> ^[22] Japan/2021	Suprasellar tumor	Chest	No	Postoperative panhypopituitarism under hormone replacement therapy	No
Kamel <i>et al.</i> ^[11] Kuwait and Egypt/2021	Pituitary tumor apoplexy	RT-PCR	Yes	Patient death	No
Karia <i>et al.</i> ^[12] UK/2021	Metastatic colonic adenocarcinoma to the pituitary gland	Unknown	Yes (postoperative)	Patient death	No
Taneja <i>et al.</i> ^[20] USA /2022	Pituitary apoplexy with rapidly evolving hemorrhage	RT-PCR	Yes	No	No

CSF: Cerebrospinal fluid

RT-PCR was negative. On the 4th postoperative day, the parent tested positive. The cause of the COVID-19-related death in this case series was not identified. It is possible that the hypercoagulability state of Cushing disease could have influenced the course of COVID-19 infection.

CONCLUSION

Our institutional protocol to perform EETA during COVID-19 pandemic was easy to implement and the pituitary surgeries were maintained during the pandemic only to treat critical cases. Nevertheless, the protocols should be continually updated for greater patient and health-care professional safety.

Declaration of patient consent

The authors certify that they have obtained all appropriate patient consent.

Financial support and sponsorship

The authors received financial support from FAPERJ – Fundação de Amparo à Pesquisa do Estado do Rio de Janeiro and NIPNAC – Center of High Complexity Neurosurgery Intern Patients from Rio de Janeiro State Department of Health.

Conflicts of interest

There are no conflicts of interest.

REFERENCES

- Akai T, Maruyama K, Takakura H, Yamamoto Y, Morinaga Y, Kuroda S. Safety management in urgent endonasal transsphenoidal surgery for pituitary adenoma during the COVID-19 pandemic in Japan-a case report. *Interdiscip Neurosurg* 2020;22:100820.
- Arnaut MM, Bessar AA, Elnashar I, Abaza H, Makia M. Pituitary adenoma surgeries in COVID-19 era: Early local experience from Egypt. *Surg Neurol Int* 2020;11:363.
- Barbosa D, Oberman D, Moreira A, Borges L, Goncalves F. Endonasal endoscopic pituitary adenoma resection in light of the COVID-19 pandemic: A technical report. *Arq Bras Neuroci* 2021;40:82-5.
- Chan JL, Gregory KD, Smithson SS, Naqvi M, Mamelak AN. Pituitary apoplexy associated with acute COVID-19 infection and pregnancy. *Pituitary* 2020;23:716-20.
- Cranial Consortium. CSF rhinorrhea after endonasal intervention to the skull base (CRANIAL)-part 2: Impact of COVID-19. *World Neurosurg* 2021;149:e1090-7.
- Erber J, Kappler V, Haller B, Mijočević H, Galhoz A, Da Costa C, *et al.* Infection control measures and prevalence of SARS-CoV-2 IgG among 4,554 university hospital employees, Munich, Germany. *Emerg Infect Dis* 2022;28:572-81.
- Esposito D, Olsson DS, Ragnarsson O, Buchfelder M, Skoglund T, Johannsson G. Non-functioning pituitary adenomas: Indications for pituitary surgery and post-surgical management. *Pituitary* 2019;22:422-34.
- Fang J, Xie S, Li N, Jiang Z. Postoperative complications of endoscopic versus microscopic transsphenoidal pituitary surgery: A meta-analysis. *J Coll Physicians Surg Pak* 2018;28:554-9.
- Fleseriu M, Buchfelder M, Cetas JS, Fazeli PK, Mallea-Gil SM, Gurnell M, *et al.* Pituitary society guidance: Pituitary disease management and patient care recommendations during the COVID-19 pandemic-an international perspective. *Pituitary* 2020;23:327-37.
- Halvorsen H, Ramm-Petersen J, Josefsen R, Rønning P, Reinlie S, Meling T, *et al.* Surgical complications after transsphenoidal microscopic and endoscopic surgery for pituitary adenoma: A consecutive series of 506 procedures. *Acta Neurochir (Wien)* 2014;156:441-9.
- Kamel WA, Najibullah M, Saleh MS, Azab WA. Coronavirus disease 2019 infection and pituitary apoplexy: A causal relation or just a coincidence? A case report and review of the literature. *Surg Neurol Int* 2021;12:317.
- Karia K, Price SA, Soon WC, Chowdhury YA, Thant KZ, Batra R, *et al.* Metastatic colon cancer in the pituitary: A case report with review of literature. *Asian J Neurosurg* 2021;16:872-5.
- Komotar RJ, Starke RM, Raper DM, Anand VK, Schwartz TH. Endoscopic endonasal compared with microscopic transsphenoidal and open transcranial resection of giant pituitary adenomas. *Pituitary* 2012;15:150-9.
- Mattogno PP, Rigante M, Lauretti L, Parrilla C, D'Alessandris QG, Paludetti G, *et al.* Transnasal endoscopic skull base surgery during COVID-19 pandemic: Algorithm of management in an Italian reference COVID center. *Acta Neurochir (Wien)* 2020;162:1783-5.
- Pandey AS, Ringer AJ, Rai AT, Kan P, Jabbour P, Siddiqui AH, *et al.* Endovascular neurosurgery research group (ENRG). Minimizing SARS-CoV-2 exposure when performing surgical interventions during the COVID-19 pandemic. *J Neurointerv Surg* 2020;12:643-7.
- Quillin JW, Oyesiku NM. Status of pituitary surgery during the COVID-19 pandemic. *Neurol India* 2020;68:S134-6.
- Santos CD, Filho LM, Santos CA, Neill JS, Vale HF, Kurnutala LN. Pituitary tumor resection in a patient with SARS-CoV-2 (COVID-19) infection. A case report and suggested airway management guidelines. *Braz J Anesthesiol* 2020;70:165-70.
- Solari D, Bove I, Esposito F, Cappabianca P, Cavallo LM. The nose lid for the endoscopic endonasal procedures during COVID-19 era: Technical note. *Acta Neurochir (Wien)* 2020;162:2335-9.
- Talmor G, Grube JG, Eloy JA, Liu JK, Hsueh WD. Nasoseptal flap necrosis after endoscopic skull base surgery in the setting of COVID-19 pandemic. *World Neurosurg* 2020;140:374-7.
- Taneja C, Fazeli PK, Gardner PA, Wang EW, Snyderman CH, *et al.* Rapidly progressive pituitary apoplexy in a patient with COVID-19 disease treated with endoscopic endonasal surgery. *J Neurol Surg Rep* 2022;83:e8-e12.
- Van Gerven L, Qian Z, Starovoyt A, Jorissen M, Meulemans J, Van Loon J, *et al.* Endoscopic, endonasal transsphenoidal

- surgery for tumors of the sellar and suprasellar region: A monocentric historical cohort study of 369 patients. *Front Oncol* 2021;11:643550.
22. Yoneoka Y, Seki Y, Akiyama K, Sakurai Y, Ohara N, Hasegawa G. Prolonged postoperative pyrexia and transient nonnephrogenic vasopressin-analogue-resistant polyuria following endoscopic transsphenoidal resection of an infundibular epidermoid cyst. *Case Rep Neurol Med* 2021;2021:6690372.
23. Young JS, Oh T, Arora T, Blevins LS, Aghi MK, El-Sayed IH, *et al.* Letter: COVID conundrum: Postoperative COVID-19 infections following endonasal transsphenoidal pituitary surgery. *Neurosurgery* 2021;88:E571-2.
24. Zhu W, Huang X, Zhao H, Jiang X. A COVID-19 patient who underwent endonasal endoscopic pituitary. Adenoma resection: A case report. *Neurosurgery* 2020;87:E140-6.

How to cite this article: Pestana-Costa LF, Ferreira-Pinto PH, Pontes JB, Brito AC, Martha BM, Da Silva WN, *et al.* Endoscopic endonasal transsphenoidal approach during COVID-19 pandemic in Brazil. *Surg Neurol Int* 2022;13:504.

Disclaimer

The views and opinions expressed in this article are those of the authors and do not necessarily reflect the official policy or position of the Journal or its management. The information contained in this article should not be considered to be medical advice; patients should consult their own physicians for advice as to their specific medical needs.