




Case Report

# Mechanical thrombectomy for acute paradoxical cerebral embolism due to pulmonary arteriovenous malformation: A case report and review of literature

Satoshi Inoue<sup>1</sup>, Atsushi Fujita<sup>2</sup>, Eiji Kurihara<sup>1</sup>, Takashi Sasayama<sup>2</sup>

<sup>1</sup>Department of Neurosurgery, Junshin Hospital, Kakogawa, <sup>2</sup>Department of Neurosurgery, Kobe University Graduate School of Medicine, Kobe, Japan.

E-mail: \*Satoshi Inoue - nsurg2000@yahoo.co.jp; Atsushi Fujita - afujita@med.kobe-u.ac.jp; Eiji Kurihara - kurihara@junshin.or.jp; Takashi Sasayama - takasasa@med.kobe-u.ac.jp



\*Corresponding author:

Satoshi Inoue,  
Department of Neurosurgery,  
Junshin Hospital, Kakogawa,  
Japan.

nsurg2000@yahoo.co.jp

Received : 27 October 2022  
Accepted : 23 December 2022  
Published : 13 January 2023

DOI  
10.25259/SNI\_987\_2022

Quick Response Code:



## ABSTRACT

**Background:** We report a case of acute occlusion of the middle cerebral artery (MCA) due to pulmonary arteriovenous malformation (PAVM), for which mechanical thrombectomy was performed and a good outcome was achieved.

**Case Description:** A 59-year-old woman presented with severe right hemiplegia and dysarthria, and a National Institutes of Health Stroke Scale (NIHSS) score of 10. Magnetic resonance imaging (MRI) diffusion-weighted imaging revealed high-signal areas in the left lenticular nucleus to the corona radiata, and right temporal lobe. Magnetic resonance angiography revealed the left MCA occlusion. Chest plain computed tomography (CT) revealed PAVM in the lower lobe of the left lung. Transvenous thrombolytic therapy was started 2 h after onset, and mechanical cerebral thrombectomy was performed with an aspiration catheter and stent retriever. A red thrombus was retrieved in one pass and complete recanalization was achieved. After treatment, her symptoms improved markedly, but a symptomatic intracerebral hematoma was observed in the contralateral right temporal lobe. The patient underwent embolization for PAVM on day 24 and was transferred for rehabilitation (NIHSS score = 2).

**Conclusion:** Although rare, PAVM is a treatable cause of stroke in relatively young adults; thus, it is important to keep in mind the possibility of its presence.

**Keywords:** Acute ischemic stroke, Hereditary hemorrhagic telangiectasia, Paradoxical cerebral embolization, Recombinant tissue plasminogen activator, Stent retriever

## INTRODUCTION

Pulmonary arteriovenous malformation (PAVM), or pulmonary arteriovenous fistula, is a rare vascular anomaly in which dilated abnormal vessels directly connect the pulmonary and systemic circulation without capillaries.<sup>[10,12]</sup> CT studies from Japan show a prevalence of 38/100,000, and its incidence is twice as common in women.<sup>[10]</sup> PAVMs can cause paradoxical cerebral embolisms, brain abscesses, migraine headaches, and occasionally fatal pulmonary hemorrhage due to rupture.<sup>[10]</sup> About 40–80% of PAVM cases are associated with hereditary hemorrhagic telangiectasia (HHT),<sup>[7,10,14]</sup> an autosomal dominant inheritance, in which comorbid epistaxis and gastrointestinal bleeding due to telangiectasia are problematic. The incidence of stroke and brain abscess in PAVM cases is 30% and 10–20%, respectively, with a mortality rate of up to 40%.<sup>[10]</sup> In

This is an open-access article distributed under the terms of the Creative Commons Attribution-Non Commercial-Share Alike 4.0 License, which allows others to remix, transform, and build upon the work non-commercially, as long as the author is credited and the new creations are licensed under the identical terms.

©2023 Published by Scientific Scholar on behalf of Surgical Neurology International

particular, PAVM is an important cause of stroke in young adults, which is associated with stroke onset of 15 years younger, death 13 years younger, and a reduction of 9 years in disability-adjusted life-years compared with stroke from other causes.<sup>[14]</sup>

Although the efficacy of acute recanalization therapy for ischemic stroke is well established, there are few reports for cerebral embolism associated with PAVM.<sup>[14]</sup> In this report, we describe a case of mechanical thrombectomy (MT) for middle cerebral artery (MCA) occlusion due to PAVM, which resulted in a favorable outcome. We also provide an initial review of case reports of acute recanalization therapy of ischemic stroke due to PAVM. Reports of MT are rare.<sup>[1,5]</sup>

## CASE PRESENTATION

A 59-year-old woman with no medical or family history was brought to the emergency room at 7:50 AM with the right hemiplegia that occurred while she was taking a bath. At the time of initial examination, she had Glasgow Coma Scale 14 (E4V4M6), amenable but slow response, and severe right hemiplegia (Manual Muscle Test 1/5) with marked dysarthria. She was diagnosed with a National Institutes of Health Stroke Scale (NIHSS) score of 10. MRI diffusion-weighted imaging (DWI) showed a vague high-signal area in the left lenticular nucleus and corona radiata, and a small clear lesion in the temporal lobe, with a DWI-Alberta Stroke Program Early Computed Tomography (CT) Score of 9/11 [Figure 1a]. MRI fluid-attenuated inversion recovery showed a left hyperintense MCA sign, perfusion-weighted image showed diffuse left hypoperfusion [Figure 1b], and magnetic resonance angiography (MRA) showed occlusion of the distal M1 segment of the left MCA [Figure 1c]; however, neck MRA showed no embolic source in the proximal vessels including the aortic arch. An electrocardiogram showed no evidence of atrial fibrillation. Chest CT showed a PAVM in the S10 inferior lobe of the left lung [Figure 1d]. Thrombolytic therapy with intravenous recombinant tissue plasminogen activator (rtPA) was started (9:50 AM), with concurrent endovascular therapy.

### MT for left MCA occlusion

The right femoral artery was punctured under local anesthesia (10:22 AM), and a 9F Optimo (Tokai Medical Products, Aichi, Japan) was inserted into the left internal carotid artery. Heparin-added saline was used for irrigation of each catheter, but heparin bolus administration was avoided because the patient was receiving rtPA. Angiography showed occlusion of the M2 segment of the left MCA [Figures 2a and b]. React 71 (Medtronic, Minneapolis, MN, USA) and Phenom 21 (Medtronic) were used as coaxial system. Synchro Select Soft (Stryker Neurovascular, Fremont, CA, USA) was guided to

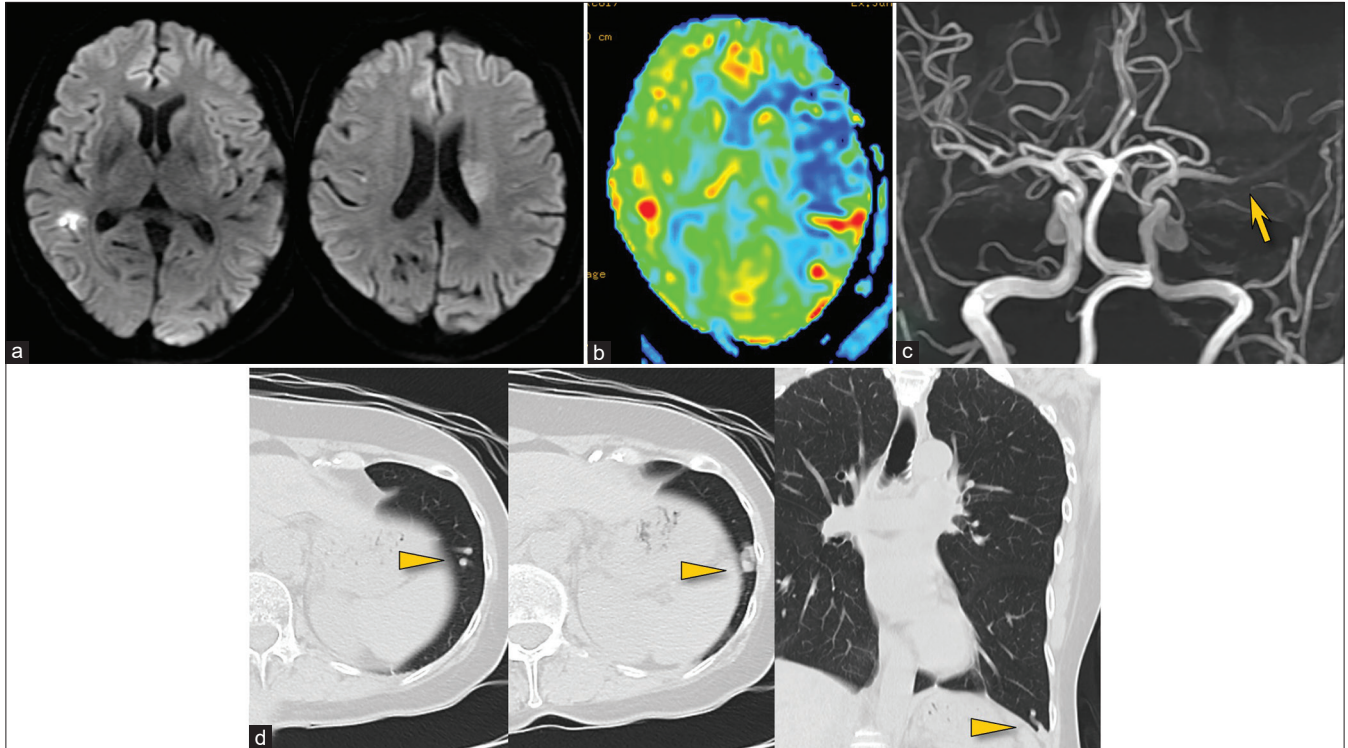
the distal part of the occlusion and followed by Phenom 21. Thrombectomy was performed using a combined technique with a Solitaire 3 × 20 mm (Medtronic), and a 1-cm red thrombus was retrieved in one pass, resulting in complete recanalization (11:26 AM, Thrombolysis in Cerebral Infarction 3, Figures 2c and d). Activated clotting time was 162 before treatment and 166 at the end of treatment.

Immediately after treatment, the patient became conscious, and her severe right hemiplegia improved markedly. Head CT showed an intracerebral hematoma in the contralateral right temporal lobe, but no new abnormal findings were found on the treated side [Figure 2e]. Acute antithrombotic therapy was not given in the acute phase. On the next day of treatment, the left hemispatial neglect and the left homonymous hemianopsia became apparent, but there was no increase in the intracerebral hematoma, and the patient was managed conservatively. Transthoracic echocardiography, Holter electrocardiography, and venous echocardiography of the lower extremities showed no abnormal findings. Blood biochemical tests, coagulation tests, tumor markers, and immunological tests also showed no abnormal findings. Head CT on day 9 showed no worsening of the hematoma, and edoxaban 30 mg was started on day 10. Head MRI and MRA on day 11 showed no evidence of recurrent stroke [Figures 2f and g]. Chest CT angiography on day 10 confirmed the diagnosis of PAVM in the left lung S10 [Figure 3a], and the venous sac was 19 × 12 mm. No embolic source was found in the aortic arch. As it was considered that there was no other lesion except the PAVM that could cause cerebral embolism, endovascular treatment of the PAVM was performed on day 24 to prevent recurrent stroke.

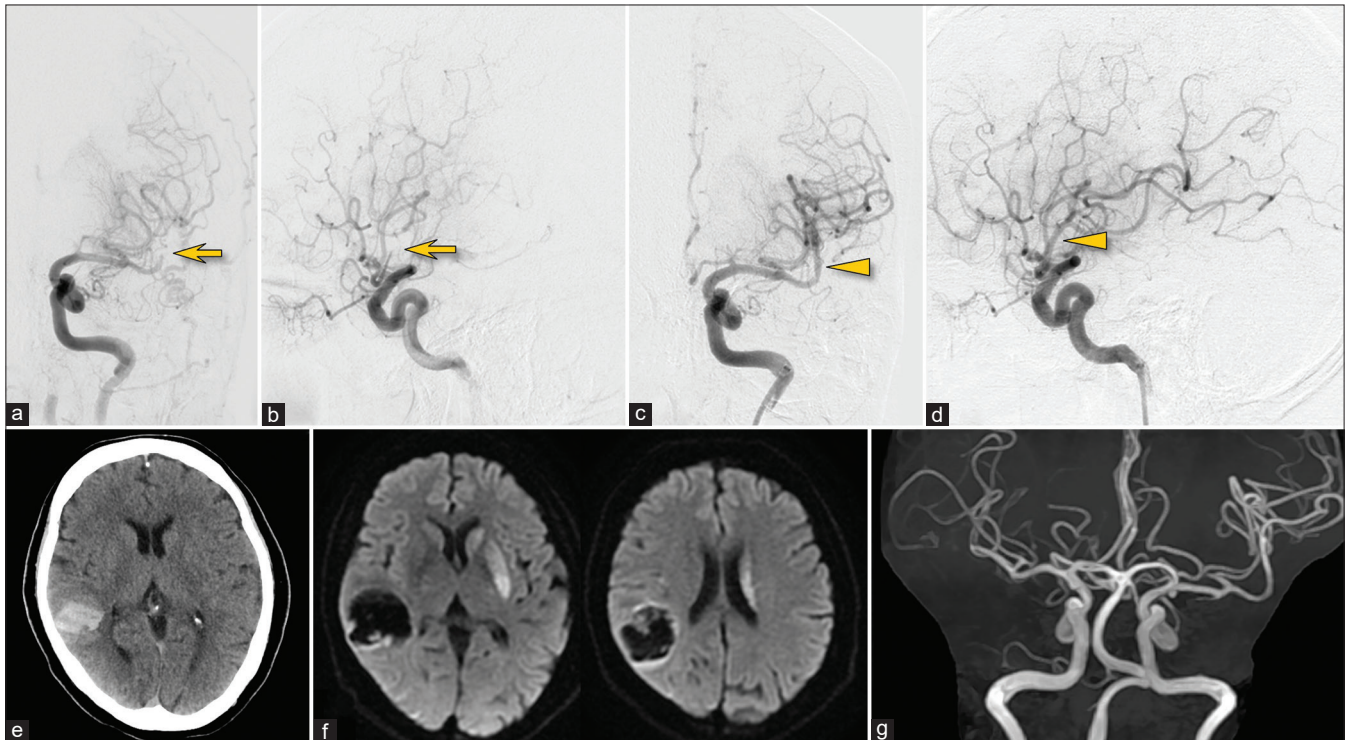
### Coil embolization of the left pulmonary PAVM

Under local anesthesia and systemic heparinization, an 8F Optimo was inserted from the right femoral vein into a branch of the left pulmonary artery, the feeder of the PAVM. The PAVM was a single lesion, simple type with a single feeder (2.6–2.8 mm in diameter), and a single drainer [Figures 3b and c]. Coil embolization was performed by double catheter technique: Excelsior 1018 (Stryker) straight and 45° were guided into the sac of the PAVM using a Meister 45° (Asahi Intec, Aichi, Japan). Through each catheter, Micrus FrameS 18 8 mm × 30 cm (Cerenovus, New Brunswick, NJ, USA) and Target XXL 6 mm × 40 cm (Stryker) were carefully placed in the sac to avoid migration to the venous side. Target XXL was added and packed back into the feeder. Hydrogel-coated coils (AZUR 4 mm × 10 cm, Terumo, Tokyo) were also used in the feeder. A total of 10 coils were used and shunt blood flow disappeared [Figures 3d and e].

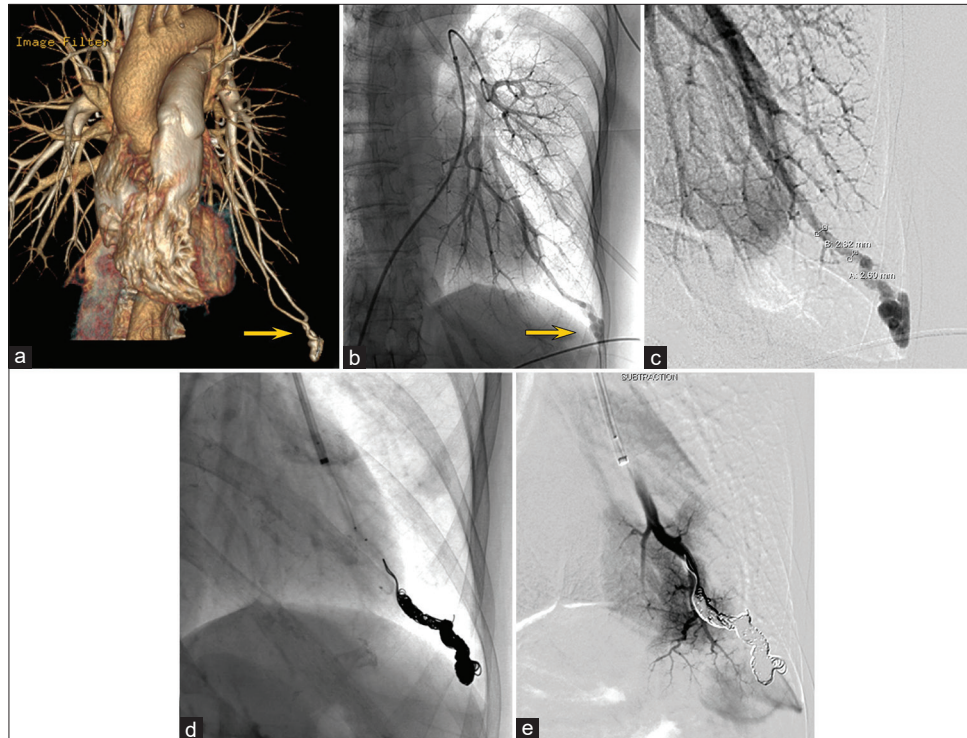
The patient's post-treatment course was uneventful. Her left homonymous hemianopsia and left hemispatial neglect remained but tended to improve. She was transferred for



**Figure 1:** MR diffusion-weighted imaging showing a vague left ischemic lesion and a small right lesion (a), perfusion imaging showing diffuse left hypoperfusion (b), and MR angiography showing left middle cerebral artery occlusion (arrow) (c). Chest CT showing a pulmonary arteriovenous malformation in the left lung (arrowheads) (d).



**Figure 2:** Left internal carotid arteriography before (a and b) and after treatment (c and d). The occlusion of the left middle cerebral artery (arrows) was successfully recanalized (arrowheads). Post-treatment CT showing a contralateral intracerebral hematoma (e). Follow-up MR imaging (f) and MR angiography (g) showing no evidence of recurrent stroke.



**Figure 3:** Chest CT angiography (a) and pretreatment angiography (b and c) showing a pulmonary arteriovenous malformation (PAVM) in the lower lobe of the left lung (arrows). The PAVM was embolized with a total of 10 coils (d) and shunt blood flow disappeared (e).

rehabilitation on day 46 without stroke recurrence (NIHSS 2, modified Rankin Scale 2).

## DISCUSSION

### Literature review of acute recanalization therapy for stroke with PAVM

The prevalence of PAVM in acute ischemic stroke is rare, ranging from 0.02% to 0.5%.<sup>[3,14]</sup> The majority of case reports describe only one case,<sup>[14]</sup> with few reports of multiple cases treated with MT. In the present study, we searched PubMed from January 1, 2012, to August 31, 2022, for reports of acute recanalization for PAVM-related ischemic stroke by thrombolysis with rtPA or endovascular therapy such as MT. To the best of our knowledge, there were 15 cases (including the present study = 17 strokes) [Table 1].<sup>[1-6,8,9,13,15-17]</sup> The mean age was 48.3 (17–84) years, 13 (87%) were female, and NIHSS scores ranged from 0 to 27 (mean 11.6). Cerebral large vessel occlusion was present in 9/16 (56%). Thrombolysis with rtPA was performed in 11 patients (one transarterial), and MT was performed in three patients, including the present case.<sup>[1,5]</sup> No intracranial hemorrhagic complications were reported except for the present case (6.7%). Neurological outcomes varied from favorable to death due to cerebral herniation. Three patients had a history of pulmonary disease at the time of stroke onset and one patient (6.7%) had been diagnosed

with PAVM. Seven patients underwent embolization, and four patients underwent surgical treatment for PAVM.

### Evidence for recanalization therapy for stroke with PAVM

At present, there are no practical guidelines for acute recanalization therapy for PAVM-related paradoxical cerebral embolism. According to the British Thoracic Society Clinical Statement, there is no evidence for the safety and efficacy of thrombolytic therapy.<sup>[10]</sup> Furthermore, there is no mention in the AHA guidelines.<sup>[14]</sup> Case reports of MT are rare, and the treatment strategy is not yet established. In general, the potential for bleeding complications is an issue with thrombolytic therapy, and the risk of fatal pulmonary bleeding in PAVM is particularly high in pregnant women.<sup>[7,10]</sup> In addition, the risk of epistaxis and gastrointestinal bleeding from comorbid telangiectasia should be considered, especially in cases of HHT. Lin *et al.*<sup>[9]</sup> recommend thrombolytic therapy as the treatment of choice for patients with isolated PAVM within a time window, whereas patients with HHT require careful consideration.

There is also no evidence for optimal antithrombotic management after acute recanalization therapy for cerebral embolism due to PAVM. In the present review, antiplatelet agents were administered in five patients and anticoagulants in two patients. However, two patients had early recurrence

Table 1: Summary of reported 14 cases of acute reperfusion therapy for acute ischemic stroke due to PAVM.

S. No.	Author (year), reference	Age (years)/sex	Clinical presentation	NIHSS	Lesion	IVO	Thrombolysis	MT	Medication	Venous thrombosis	HHT	Past history of pulmonary disease	PAVM	Treatment for PAVM	Neurological outcome
1.	Present case (2022)	59/F	Rt. hemiplegia, dysarthria	10	Lt. lenticular nucleus, corona radiata	Lt. MCA (M1)	IV	MT	Edoxaban	(-)	(-)	(-)	Single (feeder 2.8 mm, sac 19 mm)	Coil	Lt. ipsilateral hemianopsia, Lt. hemispatial neglect, NIHSS 2 at 1 months No further event
2.	Tagliapietra et al. (case 1) (2022) <sup>[13]</sup>	44/F	Dysarthria, facial paresis, Rt. hemiplegia	NA	Lt. pontine	(-)	IV	(-)	NA	NA	(-)	Pulmonary malformation on Chest X-rays	Single (sac 35 mm)	Coil, MVP	NA
3.	Tagliapietra et al. (case 2) (2022) <sup>[13]</sup>	45/F	Speech disturbance, Lt. arm weakness	NA	Lt. occipitoparietal	(-)	(-)	(-)	NA	NA	(+)	NA	Two	Coil, micro Amplatzer	NA
4.	Xu et al. (2022) <sup>[6]</sup>	38/F	Rt. hemiplegia, unconsciousness, gaze to the Rt.	NA	Lt. cerebral hemisphere	Lt. ICA	(vascular interventional therapy)	IV	NA	NA	NA	Recurrent pulmonary embolism	NA	(-)	Cerebral herniation, death
5.	Hashmi et al. (2021) <sup>[4]</sup>	58/M	Dizziness, Rt. side weakness, slurred speech	11	Lt. basal ganglia, periventricular white matter	(-)	IV	(-)	NA	NA	NA	(-)	Single	Clipping	Complete recovery
6.	Jiang et al. (2021) <sup>[5]</sup>	17/F	Motor aphasia, Rt. side hemiplegia (level 0)	NA	Lt. external capsule area	Lt. MCA (M1)	(-)	MT	NA	NA	NA	NA	Multiple, diffuse (both lungs)	Spring coil	Recovered well (discharged 3 days later)
7.	Wang et al. (2021) <sup>[15]</sup>	38F	Numbness of Rt. limbs, speech disorder, distorted mouth corner	NA	Lt. cerebral infarction	(-)	IV	(-)	NA	NA	NA	NA	Single	Thoracoscopic partial lower lobe resection	Significant improvement at 1 year
8.	Zhan et al. (2021) <sup>[17]</sup>	54/F	Lt.-sided limb weakness (grade 1/5)	8	Rt. basal ganglia, corona radiata	(-)	IV	(-)	NA	(-)	NA	(-)	Single (1.5cm)	Coil	NIHSS 0 at 15 months
9.	Hasegawa et al. (2019) <sup>[3]</sup>	84/F	Consciousness disturbance, motor aphasia, Rt. tractile extinction, Lt. conjugate gaze, Rt. Hemiplegia	22	Cortical lesion in Lt. MCA territory	Lt. MCA (M1 proximal)	IV	(-)	Edoxaban	(+)	NA	(-)	Single (feeder 4.3mm, nidus 3.8mm)	Coil	NIHSS 13 after thrombolysis
10.	Lin et al. (case 1) (2019) <sup>[9]</sup>	68/F	Hypoalgesia of Rt. extremities, blur speech	3	Cortex of Lt. hemisphere	(-)	IV	(-)	Aspirin	(-)	NA	NA	Single	(-)	No sequela

(Contd...)

Table 1: (Continued).

S. No.	Author (year), reference	Age (years)/sex	Clinical presentation	NIHSS	Lesion	IVO	Thrombolysis	MT	Medication	Venous thrombosis	HHT	Past history of pulmonary disease	PAVM	Treatment for PAVM	Neurological outcome
11.	Lin et al. (case 2) (2019) <sup>[9]</sup>	73F	Rt. hemiplegia, global aphasia, Rt. side gaze palsy, Rt. hemianopsia	27	Multiple infarcts in Rt. frontal lobe and Rt. Cerebellum	(-)	IV	(-)	Aspirin	(-)	(-)	NA	Single	(-)	NIHSS 4 at discharge
12.	Kane et al. (2016) <sup>[6]</sup>	21/M	Dysarthria, mild Lt.-side weakness and ataxia	6	Rt. PCA territory	Rt. PCA	IV	(-)	Clopidogrel	NA	NA	NA	Several	NA	Independent, mild residual problems with Lt. foot
13.	Dubrava et al. (2014) <sup>[2]</sup>	35/F	Severe Rt.-side hemiparesis, global aphasia	NA	Large infarct within Lt. MCA area (83mm)	Proximal Lt MCA	IV	(-)	NA	(-)	(-)	NA	Two (30 mm, 17 mm)	Coil	Moderate Rt.-side hemiparesis, severe expressive aphasia
14.	Akiyama et al. (2013) <sup>[11]</sup>	67/F	(1) Weakness in Rt. upper extremity (2) Lt. hemiparesis, Lt. sensory paralysis, dysarthria	(1) 0 (2) 16	(1) Rt. Cerebellar (2) Rt. MCA region	(1) basilar artery occlusion (2) Rt. ICA and MCA occlusion	(1) (-) (2) (-)	(1) (1) Aspirin, (-) clopidogrel, (2) argatroban MT (2) NA	NA	NA	(+)	NA	Single (feeder larger than 3 mm)	Video-assisted thoracoscopic resection	NIHSS 1 after thrombectomy
15.	Li et al. (2012) <sup>[8]</sup>	24/F	(1) Mild Rt. facial weakness, Rt. hemiplegia, dense Rt.-sided sensory deficit (2) Rt. facial numbness	(1) 13 (2) NA	(1) Lt. corona radiate (2) Lt. cerebral peduncle, Lt. anterior medial thalamus, posterior limb of Lt. internal capsule	(1) thrombus at Lt. MCA bifurcation (2) NA	(1) IA (2) (-)	(1) (1) (-) Enoxaparin, (2) aspirin (-) None after PAVM resection	(1) (1) (-) Enoxaparin, (2) aspirin (-) None after PAVM resection	(-)	(-)	NA	Large (5.5 cm)	Resection (lower lobe segmentectomy)	Mild Rt. facial weakness and slight ataxia, NIHSS 2 at discharge

PAVM: Pulmonary arteriovenous malformation, MT: Mechanical thrombectomy, HHT: Hereditary hemorrhagic telangiectasia, IA: Intraarterial, IC: Internal carotid artery, Lt.: Left, MCA: Middle cerebral artery, LVO: Large vessel occlusion, M1: M1 segment, M2: M2 segment, MVP: Micro vascular plug, NA: Not available, NIHSS: National Institutes of Health Stroke Scale, PCA: posterior cerebral artery, Rt.: Right, (-): No

of ischemic stroke despite receiving antiplatelet therapy.<sup>[1,8]</sup> Early treatment of PAVMs would be desirable if possible.

### Diagnosis of PAVM in the acute phase of stroke

Because PAVM is rare and cerebral infarction is often the initial presentation,<sup>[7]</sup> it is not easy to diagnose PAVM in the clinical setting of acute recanalization therapy for stroke. In the present review, only one case of PAVM was diagnosed at the time of stroke onset. In the present case, PAVM was diagnosed by plain chest CT. PAVMs are characterized by homogenous, well-circumscribed, non-calcified nodules connected with blood vessels, and the use of contrast media is not mandatory for the detection of PAVMs.<sup>[10]</sup> The clinical diagnosis of HHT is based on Curacao criteria.<sup>[7]</sup> The diagnosis of HHT is confirmed when three or more of the following criteria are present and suspected when two of these criteria are present: epistaxis, visceral lesions, telangiectasia, and family history. In this case, only a visceral lesion was present; thus, the possibility of HHT was considered low. In the acute phase of stroke, Kane *et al.* recommend asking “Do you, or does anyone in the family, have nose bleeds?”<sup>[6]</sup> It may also be useful to perform a visual examination, noting capillary dilation of the fingers, lips, and tongue, and to ask about the patient’s and family’s history of gastrointestinal bleeding,<sup>[9]</sup> stroke, brain abscess, and lung lesions.

### MT for stroke with PAVM

In cases of cerebral large vessel occlusion due to PAVM, MT may be less risky than thrombolysis in terms of hemorrhagic complications, especially when HHT is present.<sup>[6]</sup> In the present case, a red thrombus similar to a cardiac embolus was retrieved with the usual technique. A symptomatic intracerebral hemorrhage was observed in the contralateral side, possibly due to thrombolytic therapy. PAVM-related ischemic stroke is considered to be more common in cortical and subcortical lesions, and proximal large vessel occlusion is considered rare.<sup>[14]</sup> However, in the present study, large vessel occlusion was observed in the majority of patients, suggesting that there may be situations in which MT should be considered for PAMV-related ischemic stroke. Most of the reports reviewed here focused mainly on PAVM, with relatively little discussion of stroke management.<sup>[6,9]</sup> Although this is a rare condition, further case studies and research are needed. At present, it is important to carefully determine the risk-benefit of acute recanalization therapy for ischemic stroke with PAVM.

### Treatment of PAVM

Endovascular embolization is the first-line treatment for PAVM.<sup>[10,12]</sup> Previously, treatment was indicated at 3 mm or greater; however, currently, paradoxical embolism is

considered independent of the size of the feeding vessel, and embolization is recommended for all treatable PAVMs.<sup>[10,12]</sup> Hydrogel-coated coils were used in the present case, which may lead to a lower recanalization rate.<sup>[11]</sup>

### CONCLUSION

We report a case of acute recanalization therapy with MT for a cerebral embolism due to PAVM. Although rare, PAVM is a treatable condition that can cause ischemic stroke in young adults; thus, it is important to keep in mind the possibility of its presence.

### Acknowledgments

The authors thank Dr. Hiroaki Nakamura and Dr. Takeshi Hatta for the appropriate management and treatment of PAVM.

### Declaration of patient consent

The authors certify that they have obtained all appropriate patient consent.

### Financial support and sponsorship

Nil.

### Conflicts of interest

There are no conflicts of interest.

### REFERENCES

1. Akiyama S, Hanada S, Uruga H, Takaya H, Miyamoto A, Morokawa N, *et al.* Hereditary hemorrhagic telangiectasia with pulmonary arteriovenous malformation and embolic strokes treated successfully with video-assisted thoracoscopic resection. *Intern Med* 2013;52:1091-4.
2. Dubrava J, Vulev I, Richter D. Isolated pulmonary arteriovenous fistulas with massive right-to-left shunt as a rare cause of cryptogenic stroke in a young woman. *Isr Med Assoc J* 2014;16:320-1.
3. Hasegawa I, Abe T, Mino T, Okamoto K, Takeda A, Itoh Y. Paradoxical brain embolism caused by isolated pulmonary arteriovenous fistula successfully treated with recombinant tissue plasminogen activator. *J Stroke Cerebrovasc Dis* 2019;28:e100-1.
4. Hashmi AT, Batool A, Khalid MO, Raheja H, Sadiq A, Hollander G. Multiple strokes due to pulmonary arteriovenous malformation. *Radiol Case Rep* 2021;16:2362-5.
5. Jiang X, He L, Shen B, Ma H, Zhang B. Pulmonary multifocal arteriovenous malformations lead to ischemic stroke in young adults: A case report and literature review. *Ann Palliat Med* 2021;10:12034-8.
6. Kane I, Ford AP, Lawton K, Poitelea M, Gainsborough N. Ischaemic stroke in a 21-year-old with hereditary haemorrhagic

- telangiectasia. *Pract Neurol* 2016;16:381-4.
7. Kramdhari H, Valakkada J, Ayyappan A. Diagnosis and endovascular management of pulmonary arteriovenous malformations. *Br J Radiol* 2021;94:20200695.
  8. Li Y, Margraf J, Kluck B, Jenny D, Castaldo J. Thrombolytic therapy for ischemic stroke secondary to paradoxical embolism in pregnancy: A case report and literature review. *Neurologist* 2012;18:44-8.
  9. Lin G, Jiang P, Lou M. Thrombolysis in ischemic stroke patients with isolate pulmonary arteriovenous malformations. *J Stroke Cerebrovasc Dis* 2019;28:e68-70.
  10. Müller-Hülsbeck S, Marques L, Maleux G, Osuga K, Pelage JP, Wohlgemuth WA, *et al.* CIRSE standards of practice on diagnosis and treatment of pulmonary arteriovenous malformations. *Cardiovasc Intervent Radiol* 2020;43:353-61.
  11. Shimohira M, Kawai T, Hashizume T, Muto M, Kitase M, Shibamoto Y. Usefulness of hydrogel-coated coils in embolization of pulmonary arteriovenous malformations. *Cardiovasc Intervent Radiol* 2018;41:848-55.
  12. Shovlin CL, Condliffe R, Donaldson JW, Kiely DG, Wort SJ; British Thoracic Society. British thoracic society clinical statement on pulmonary arteriovenous malformations. *Thorax* 2017;72:1154-63.
  13. Tagliapietra M, Turri G, Bortolotti F, Mansueto G, Monaco S. Ischemic stroke due to sporadic and genetic pulmonary arteriovenous malformations: Case report. *Brain Circ* 2022;8:57-60.
  14. Topiwala KK, Patel SD, Saver JL, Streib CD, Shovlin CL. Ischemic stroke and pulmonary arteriovenous malformations: A review. *Neurology* 2022;98:188-98.
  15. Wang J, Zhang J, Wang A, Wang C. Pulmonary arteriovenous fistula diagnosed by transthoracic contrast echocardiography: A case report. *J Clin Ultrasound* 2021;49:298-300.
  16. Xu S, Hong M, Zhou Z. Images of the month 1: Ischaemic stroke due to pulmonary arteriovenous fistula. *Clin Med (Lond)* 2022;22:278-9.
  17. Zhan J, Dong C, Li M, Zhan L, Chen H, Lu L, *et al.* Cryptogenic stroke caused by pulmonary arterial venous malformation with massive right-to-left shunt: A case report. *Neurol Ther* 2021;10:1135-42.

**How to cite this article:** Inoue S, Fujita A, Kurihara E, Sasayama T. Mechanical thrombectomy for acute paradoxical cerebral embolism due to pulmonary arteriovenous malformation: A case report and review of literature. *Surg Neurol Int* 2023;14:13.

## Disclaimer

The views and opinions expressed in this article are those of the authors and do not necessarily reflect the official policy or position of the Journal or its management. The information contained in this article should not be considered to be medical advice; patients should consult their own physicians for advice as to their specific medical needs.