ScientificScholar®
Knowledge is power
Publisher of Scientific Journals

www.surgicalneurologyint.com

Surgical Neurology International

Editor-in-Chief: Nancy E. Epstein, MD, Clinical Professor of Neurological Surgery, School of Medicine, State U. of NY at Stony Brook.

SNI: Neuroanatomy and Neurophysiology

Editor
Seyed Ali Khonsary, MD
University of California at Los Angeles, Los Angeles, CA, USA

SNI
Open Access

Original Article

Nervus intermedius: Microsurgical and anatomic relationships to the cerebellopontine angle neurovascular complex

Ali Tayebi Meybodi[1], Allison S. Liang[2], Pooneh Mokhtari[2], Leandro Borba Moreira[1], Xiaochun Zhao[1], Michael T. Lawton[1], Mark C. Preul[1]

[1]Department of Neurosurgery, Barrow Neurological Institute, St. Joseph's Hospital and Medical Center, Phoenix, Arizona, [2]Department of Neurosurgery, Rutgers New Jersey Medical School, Newark, New Jersey, United States.

E-mail: Ali Tayebi Meybodi - tayebi.a77@gmail.com; Allison S. Liang - allison.liang@hsc.utah.edu; Pooneh Mokhtari - pmokhtarip@gmail.com; Leandro Borba Moreira - lbm.neuro@gmail.com; Xiaochun Zhao - kyle.g0704@gmail.com; Michael T. Lawton - michael.lawton@barrowbrainandspine.com; *Mark C. Preul - neuropub@barrowneuro.org

***Corresponding author:**
Mark C. Preul,
Department of Neurosurgery,
Barrow Neurological Institute,
St. Joseph's Hospital and
Medical Center, Phoenix,
Arizona, United States.

neuropub@barrowneuro.org

Received : 08 December 2022
Accepted : 28 December 2022
Published : 03 February 2023

DOI
10.25259/SNI_1097_2022

Quick Response Code:

ABSTRACT

Background: The nervus intermedius (NI) comprises fibers originating from the trigeminal, superior salivary, and solitary tract nuclei, which join the facial nerve (cranial nerve [CN] VII). Neighboring structures include the vestibulocochlear nerve (CN VIII), the anterior inferior cerebellar artery (AICA), and its branches. Microsurgical procedures at the cerebellopontine angle (CPA) benefit from understanding NI anatomy and relationships, especially for the microsurgical treatment of geniculate neuralgia, where the NI is transected. This study sought to characterize common relationships between the NI rootlets, CN VII, CN VIII, and the meatal loop of AICA at the internal auditory canal (IAC).

Methods: Seventeen cadaveric heads underwent retrosigmoid craniectomy. Following complete unroofing of the IAC, the NI rootlets were individually exposed to identify their origins and insertion points. The AICA and its meatal loop were traced to assess their relationship with the NI rootlets.

Results: Thirty-three NIs were identified. The median number of NI rootlets was 4 per NI (interquartile range, 3–5). The rootlets mainly originated from the proximal premeatal segment of CN VIII (81 of 141, 57%) and inserted onto CN VII at the IAC fundus (89 of 141, 63%). When crossing the acoustic-facial bundle, the AICA most frequently passed between the NI and CN VIII (14 of 33, 42%). Five composite patterns of neurovascular relationships were identified regarding NI.

Conclusion: Although certain anatomical trends can be identified, the NI has a variable relationship with the adjacent neurovascular complex at the IAC. Therefore, anatomical relationships should not be used as the sole method of NI identification during CPA surgery.

Keywords: Anterior inferior cerebellar artery, Geniculate neuralgia, Internal auditory canal, Nervus intermedius, Vestibular schwannoma

INTRODUCTION

The nervus intermedius (NI), first identified by Italian physician Bartolomeo Eustachi in 1563 and described in detail in 1777 by German anatomist Heinrich August Wrisberg,[3] is a sensory and

parasympathetic nerve joining the facial nerve (cranial nerve [CN] VII). Three types of fibers comprise the NI: general sensory afferents from the concha of the ear, special visceral afferents for taste, and general visceral efferents for lacrimation.[22] Rhoton *et al*.[15] described the most frequent origin of the NI to be from the vestibulocochlear nerve (CN VIII). According to these authors, the NI comprises up to 4 rootlets. Alfieri *et al*.[1] reported the NI to be composed of 1–5 rootlets originating from the brainstem, CN VII, and CN VIII. Related neurovascular structures include CN VII, CN VIII, and the anterior inferior cerebellar artery (AICA).

Microsurgical procedures at the cerebellopontine angle (CPA) may require identification of the NI for transection or microvascular decompression (MVD) for geniculate neuralgia (GN), and the NI also serves as an anatomical landmark for vestibular schwannoma resections.[1,14,18] In addition, surgeons should be attentive to the course of the AICA in the vicinity of the internal auditory canal (IAC) to avoid inadvertent vascular injury. A large morphologic diversity in the presentation of NI and its rootlets, along with variations in the relationship of the AICA meatal loop to adjacent nerves, has been appreciated across multiple anatomic studies.[1,4,7,8,13] However, the interrelationships between these NI variations and the AICA course at the IAC have been poorly delineated. Thus, to further aid surgical exploration of the CPA, we aimed to characterize common relationships between NI rootlets and the associated neurovascular complex at the IAC.

MATERIALS AND METHODS

This work did not involve patients; therefore, no institutional review board approval was required.

Cadaveric dissection

Thirty-three sides of 17 embalmed cadaveric heads were prepared for dissection. The arteries and veins were injected with red and blue silicone dye, respectively. The head was placed in a 3-pin head holder in the lateral position with 10° of head rotation to the contralateral side. A retrosigmoid craniectomy was performed. The dura was opened based on the lateral and sigmoid sinuses, and the arachnoid of the CPA was dissected open to explore the microanatomy of the acoustic-facial bundle (AFB) and associated vascular loop of AICA using a Pentero surgical microscope (Zeiss, Oberkochen, Germany). Next, the dura of the posterior aspect of the IAC was opened and incised in a semicircular fashion and reflected based on the posterior lip of the IAC [Figures 1a and b]. The petrous bone of the posterior, superior, and inferior aspects of the IAC was drilled using a high-speed drill up to the fundus of the IAC. Next, the dural lining of the IAC was opened using sharp dissection. This maneuver fully exposed the AFB neurovascular complex from the origin of the AFB at the brainstem to the IAC fundus [Figure 1c].

Assessment of neurovascular relationships

The following anatomic variables were assessed and recorded: (1) origin and (2) insertion of the NI, (3) direction of the AICA approaching the AFB, (4) relationship of the meatal loop of the AICA to the IAC meatus, and (5) relationship between the AICA and NI. Origin of the NI was recorded as "brainstem," "proximal premeatal," "distal premeatal," or "intrameatal." Insertion of the NI onto CN VII was recorded as "proximal premeatal," "distal premeatal," "intrameatal," or "fundal." The AICA approached the AFB either "superiorly" or "inferiorly." The meatal loop of the AICA was either "lateral" or "medial" to the IAC meatus. Finally, the composite neurovascular associations were studied to identify the common patterns.

Statistical analysis

Each variable was cross-tabulated based on the other five variables to generate six groups of distributions. The significance of the difference in distributions of variables in each group was assessed using the Chi-square test using SPSS (IBM, Armonk, New York). $P < 0.05$ was considered significant.

RESULTS

The nervous intermedius was identified in all 33 specimens. One specimen had a duplicate AICA from origin, making the total number of 34 AICAs. A total of 141 rootlets of the NI were identified in 33 CPAs. The median number of rootlets per specimen was 4 (range, 1–11). Most of the NI rootlets (57%, 81 of 141) originated from the proximal premeatal segment of CN VIII. Less commonly, NI rootlets also originated from the brainstem and the distal premeatal and intrameatal segments of CN VIII [Figure 2a]. Most NI rootlets inserted into CN VII near the IAC fundus (63%, 89 of 141), with the remainder joining CN VII at its intrameatal, proximal premeatal, and distal premeatal segments [Figure 2b]. The AICA approached the AFB from an inferior direction in 85% of specimens (29 of 34), with its meatal loop passing through the AFB in 65% of specimens (22 of 34). The meatal loop of the AICA was medial to the IAC meatus in 53% of specimens and lateral to the IAC meatus in 47%. The most common NI relationship between the AICA and AFB was the AICA passing between the NI and CN VIII (15 of 34, 44%). Less frequently, no relationship was found between the AICA and NI (26%, 9 of 34) [Figure 3]. When specimens in which the AICA did not cross the AFB were excluded ($n = 9$), the AICA passed between the NI and CN VIII in 58% of specimens (14 of 24).

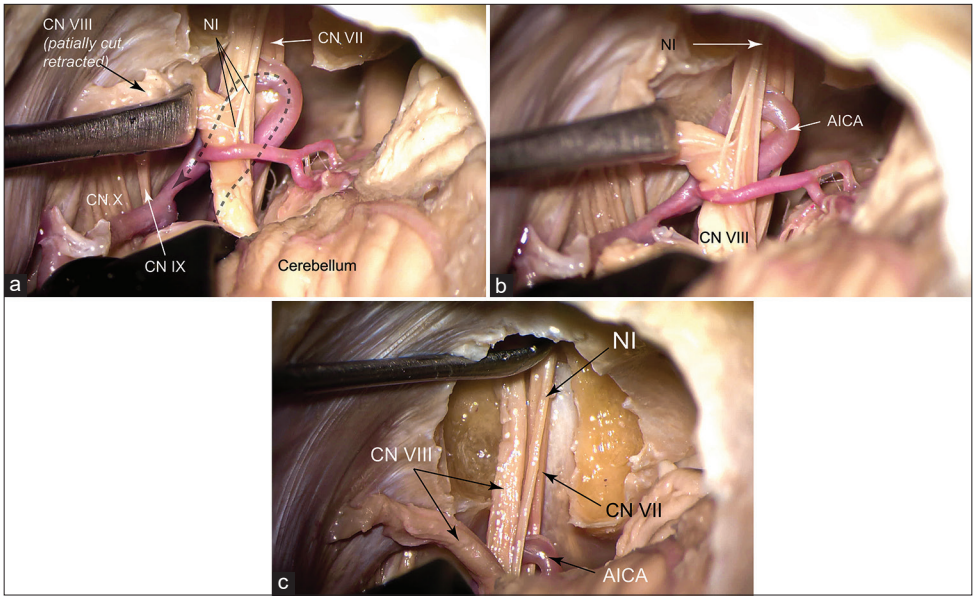

Figure 1: Cadaveric exposure of the nervus intermedius (NI) after performing a left retrosigmoid craniectomy in lateral position and drilling the posterior wall of the internal auditory canal. (a) The vestibular nerves are cut and retracted to expose the NI. The dashed arrow shows the course of the anterior inferior cerebellar artery (AICA). The AICA passes between the NI and cranial nerve (CN) VII in this specimen. (b) Magnified view of (a) showing 4 rootlets composing the NI. (c) Intrameatal course of the NI is shown as it joins the facial nerve at the fundus. *Used with permission from Barrow Neurological Institute, Phoenix, Arizona.*

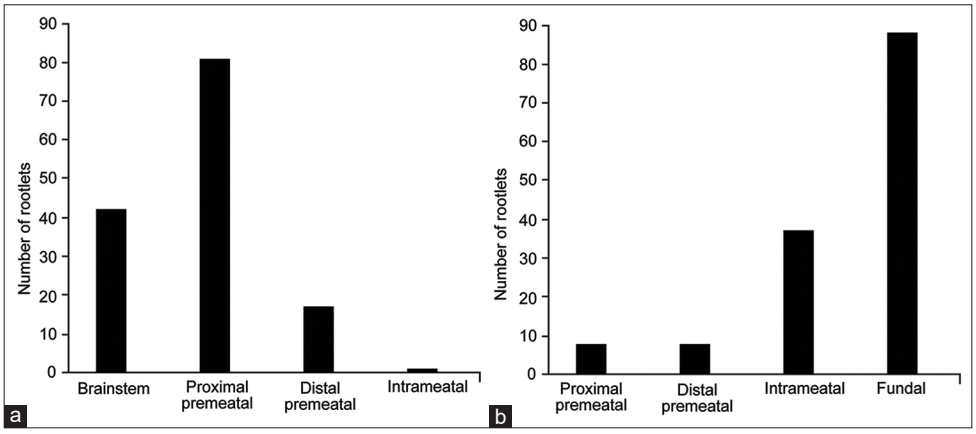

Figure 2: Distribution of the nervus intermedius rootlet origins (a) and insertions (b). *Used with permission from Barrow Neurological Institute, Phoenix, Arizona.*

Analysis of NI relations to AFB and the meatal loop of AICA

AICA-AFB "passing-through" relationship

Origin of NI rootlets

AICA passed through the AFB in 24 of 33 (73%) CPAs. As mentioned above, the most common configuration was AICA passing between NI and CN VIII (14 of 24, 58%). Chi-squared analysis revealed significant differences in the distribution of NI rootlet origins across different crossing patterns (χ^2 (9, n = 141) = 30.5, P < 0.01). When the AICA passed between CN VIII and NI (n = 15) or between CN VII and NI (n = 5), the most common origin point of NI rootlets was the proximal premeatal segment of CN VIII (42 of 56 [75%] and 18 of 25 [72%], respectively) [Figures 4a and b]. When the AICA passed through the NI rootlets, the majority of the rootlets originated from the brainstem (54%, 15 of 28) [Figure 4c]. When the AICA did not pass through the AFB, greater proportions of NI rootlets originated from the brainstem or the distal premeatal portion of CN VIII.

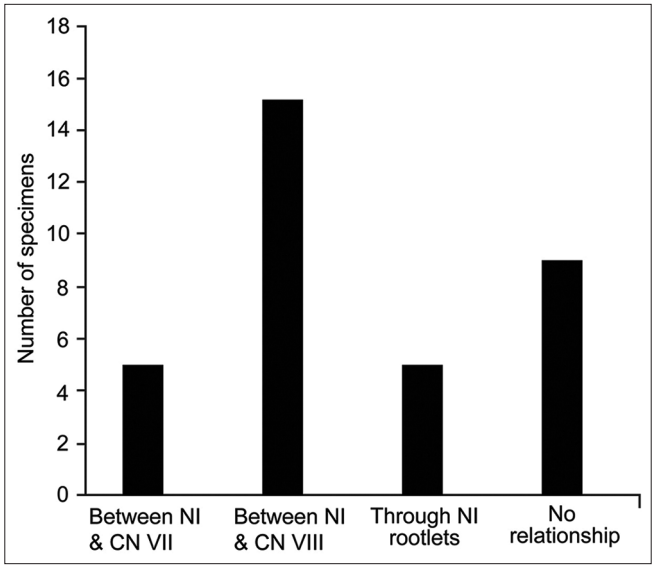

Figure 3: Distribution of relationship between the course of the anterior inferior cerebellar artery and the acoustic-facial bundle. CN: Cranial nerve, NI: Nervus intermedius. *Used with permission from Barrow Neurological Institute, Phoenix, Arizona.*

However, most rootlets still originated from the proximal premeatal segment (41%, 13 of 32) [Figure 4d].

Insertion of NI rootlets

In all "pass-through" patterns, the fundal CN VII was the most common insertion point of NI rootlets. This insertion point was most predominant in specimens in which the AICA passed between the NI and CN VII (accounting for 84% of rootlets [21 of 25]) and least predominant in specimens in which the AICA passed between the NI and CN VIII (accounting for 52% of rootlets [27 of 52]) [Figure 5].

AICA meatal loop and AFB approaching direction

In all different AFB-AICA "passing through" relationships, the AICA approached the AFB more commonly from an inferior direction [Supplemental Figures 1a-d]. However, there was less similarity between these subgroups when the relationship of the meatal loop of the AICA and IAC was considered. The meatal loop of the AICA appeared

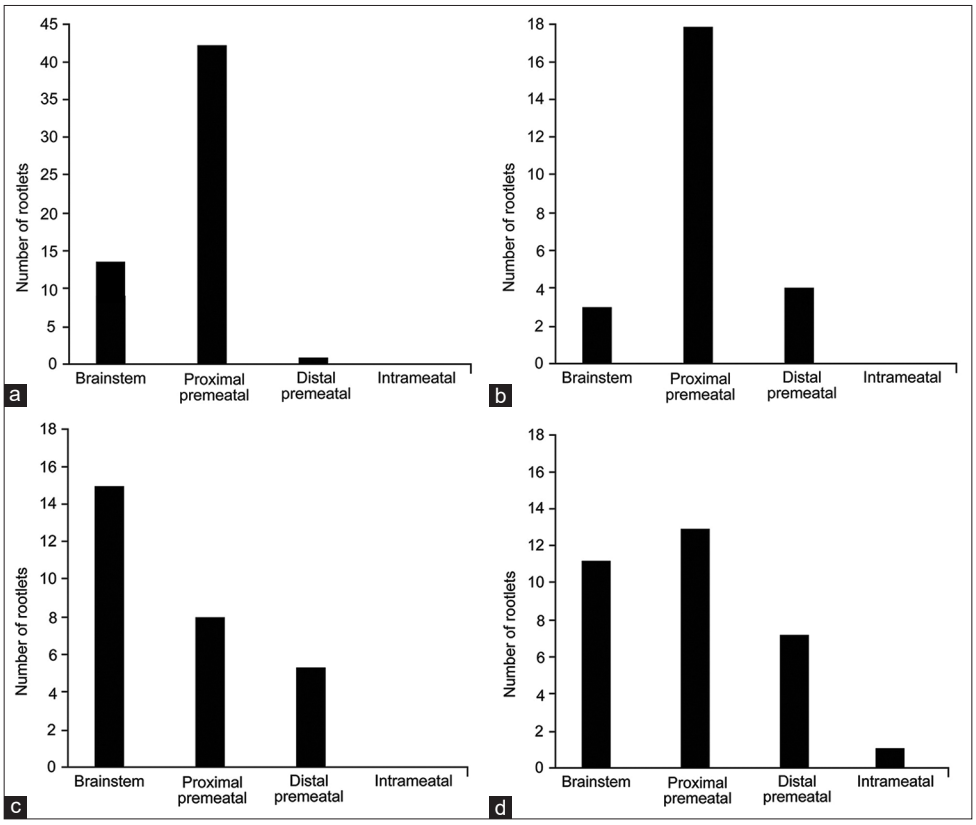

Figure 4: Distributions of the nervus intermedius (NI) rootlet origins for each of the anterior inferior cerebellar artery (AICA)-NI relationships. (a) AICA coursing between the NI and cranial nerve (CN) VIII. (b) AICA coursing between the NI and CN VII. (c) AICA coursing through the rootlets of the NI. (d) AICA not coursing through the acoustic-facial bundle. *Used with permission from Barrow Neurological Institute, Phoenix, Arizona.*

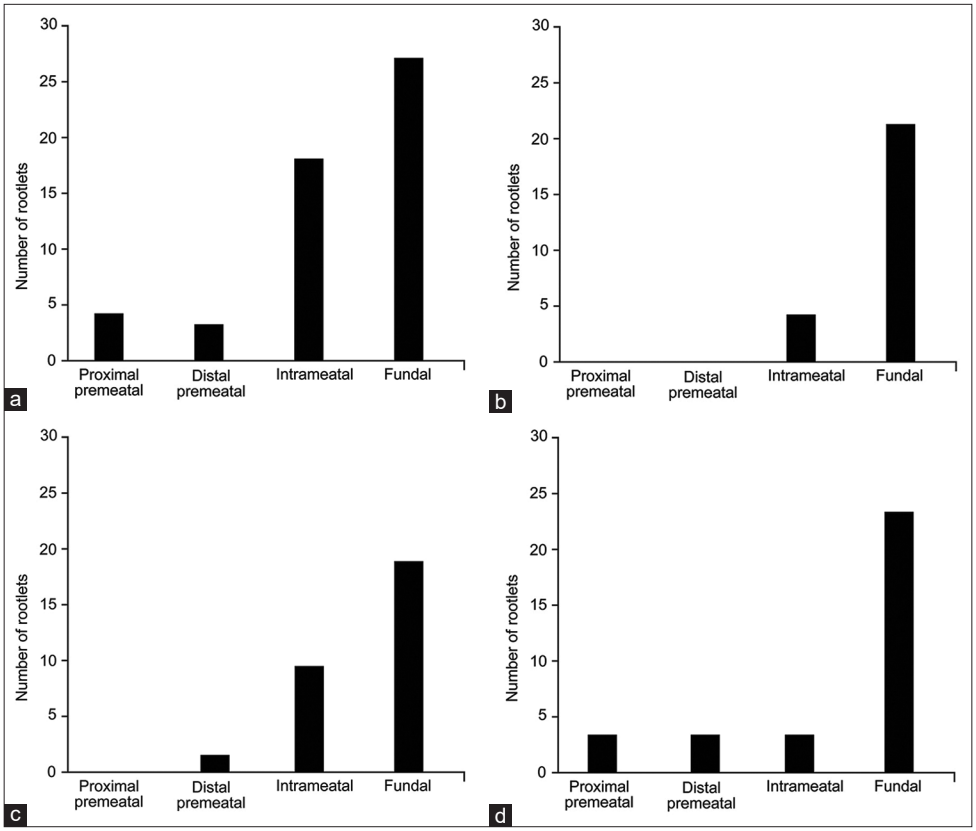

Figure 5: Distributions of the nervus intermedius (NI) rootlet insertions for each of the anterior inferior cerebellar artery (AICA)-NI relationships. (a) AICA coursing between the NI and cranial nerve (CN) VIII. (b) AICA coursing between the NI and CN VII. (c) AICA coursing through the rootlets of the NI. (d) AICA not coursing through the acoustic-facial bundle. *Used with permission from Barrow Neurological Institute, Phoenix, Arizona.*

medially to the internal auditory meatus in at least 50% of the specimens in which the AICA did not pass through the rootlets of the NI (i.e., when it passed between NI and CN VIII, NI and CN VII, or when it did not pass through the AFB at all). However, in 4 of the 5 specimens in which the AICA passed through the rootlets of the NI, it entered the IAC (i.e., lateral to the meatus) [Supplemental Figure 2].

Direction of AICA approaching AFB

NI origin

Thirty of 34 AICAs approached the AFB from an inferior trajectory (88%). In these cases, 61% (75 of 123) of NI rootlets originated from the proximal premeatal segment, and 27% (33 of 123) originated from the brainstem. No NI rootlet originated from the intrameatal segment of CN VIII in these cases. When the AICA approached the AFB from a superior direction, more NI rootlets (9 of 18, 50%) originated from the brainstem than from the proximal premeatal segment of CN VIII (6 of 18, 33%), whereas a small number originated from the intrameatal segment of CN VIII (1 of 18, 6%). Significant variations in NI rootlet origin were observed between superior versus inferior AICA approaches to the AFB (χ^2 (9, n = 141) = 19.4, P = 0.02). Figure 6 shows the different distribution patterns of the origins of NI rootlets when the direction of the AICA approach to the AFB is considered.

NI insertion

When the AICA approached the AFB from an inferior trajectory, the NI usually joined CN VII in its fundal (76 of 123, 62%) or intrameatal (37 of 123, 30%) segments. A significantly larger number of NI rootlets joined CN VII at its proximal premeatal segment when the AICA approached the AFB from a superior direction (4 of 18, 22%) compared with an inferior direction (3 of 123, 2%) (χ^2 (3, n = 141) = 17.2, P = 0.002) [Figure 7].

Meatal loop to meatus relationship

Almost half (53%) of the meatal loops were located medial to the IAC.

NI origin

NI rootlets most commonly originated from the proximal premeatal segment of CN VIII regardless of the relationship of the AICA meatal loop to the IAC (43 of 73 [59%] when medial and 38 of 68 [56%] when lateral). However, when the meatal loop was medial to the IAC, a significantly higher number of rootlets originated in the distal premeatal segment (18% [13 of 73] vs. 6% [4 of 68]) [Figure 8] (χ^2 (3, n = 141) = 8.28, P = 0.04).

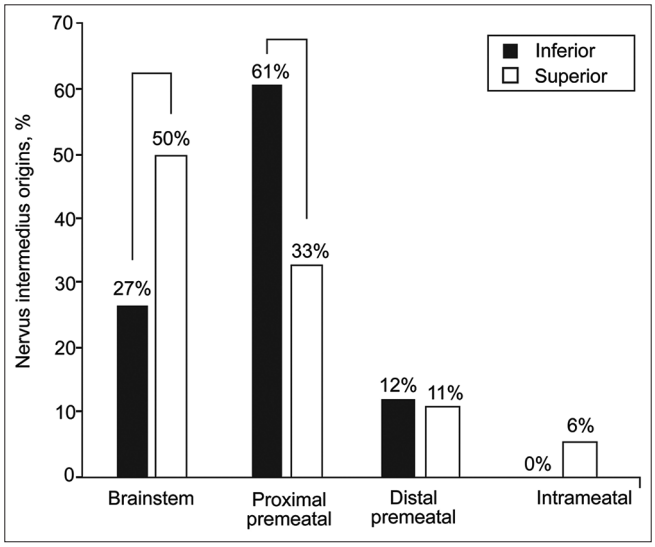

Figure 6: Relative distribution of nervus intermedius origins based on the anterior inferior cerebellar artery approach trajectory toward the acoustic-facial bundle (inferior vs. superior). Brackets show significant differences. *Used with permission from Barrow Neurological Institute, Phoenix, Arizona.*

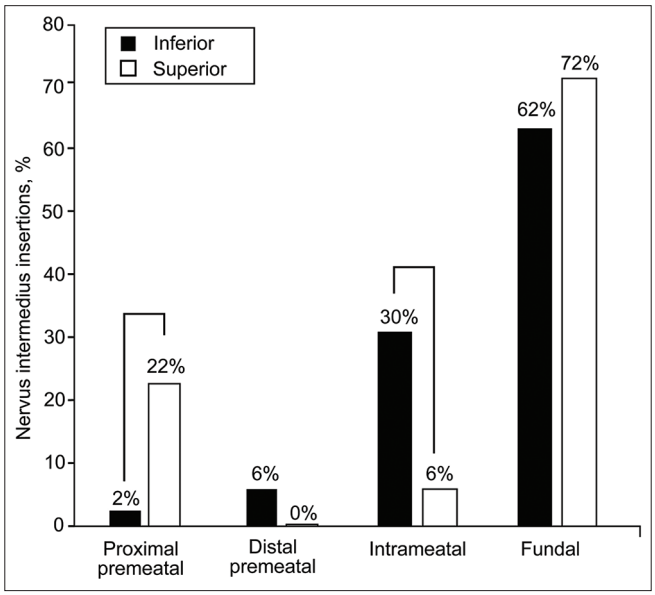

Figure 7: Relative distribution of nervus intermedius insertions based on the anterior inferior cerebellar artery approach trajectory toward the acoustic-facial bundle (inferior vs. superior). Brackets show significant differences. *Used with permission from Barrow Neurological Institute, Phoenix, Arizona.*

NI insertion

Patterns of NI rootlet insertion onto CN VII between the 2 meatal loop configurations did not differ in their relationship to the IAC. In addition, 63% of rootlets (89 of 141) inserted onto CN VII at its fundal portion regardless of whether the meatal loop was medial or lateral to the IAM (43 of 68 [63%] when lateral and 46 of 73 [63%] when medial) [Figure 9] (χ^2 (3, n = 141) = 0.210, P = 0.98).

Composite neurovascular patterns

Besides the individual neurovascular associations, the following composite patterns were studied. Because the most common points of origin and insertion of the NI rootlets were brainstem/proximal premeatal and distal premeatal/fundal, these parameters were not included in composite pattern recognition. Similarly, the meatal loop relationship to the IAC meatus was not significantly associated with any pattern. However, the following parameters were included for this analysis: (1) direction of the AICA approach to the AFB, (2) relationship of the AICA meatal loop and AFB, and (3) relationship between the AICA (or its branches) and the NI. Based on the above parameters, the following composite association patterns were found: (1) pattern 1, in which the AICA approaches the AFB from a superior or inferior

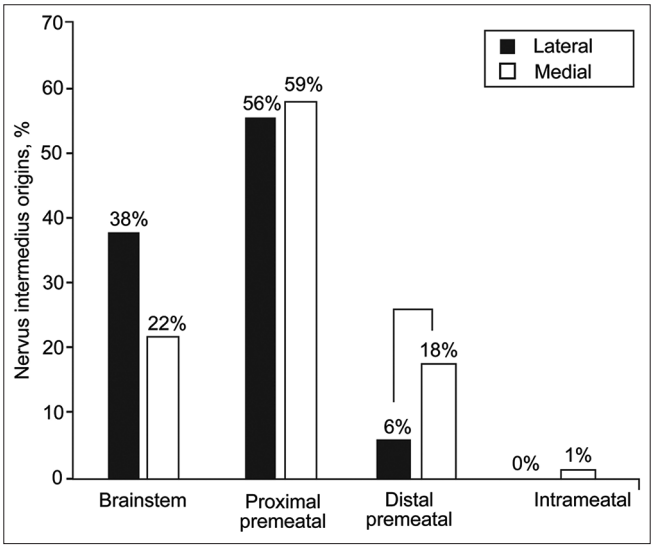

Figure 8: Relative distribution of nervus intermedius origins based on the relationship between the anterior inferior cerebellar artery meatal loop and the internal auditory canal meatus (lateral vs. medial). Brackets show significant differences. *Used with permission from Barrow Neurological Institute, Phoenix, Arizona.*

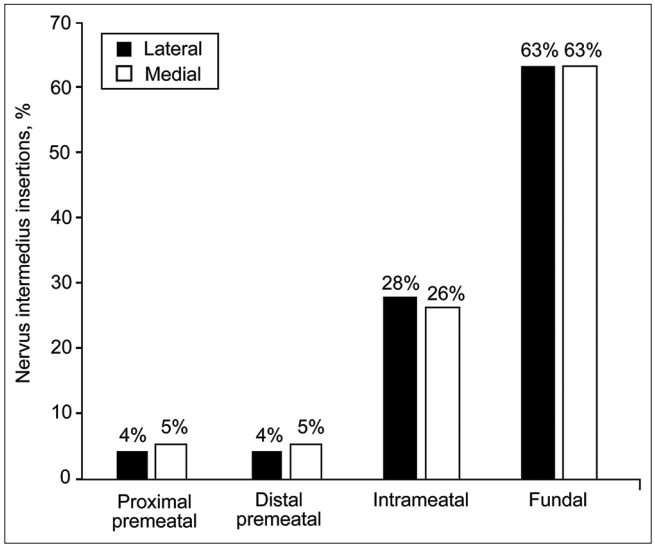

Figure 9: Relative distribution of nervus intermedius insertions based on the relationship between the anterior inferior cerebellar artery meatal loop and the internal auditory canal meatus (lateral vs. medial). No significant differences were found. *Used with permission from Barrow Neurological Institute, Phoenix, Arizona.*

direction, with the AICA meatal loop passing through the AFB between the NI and CN VIII (15 of 34, 44%); (2) pattern 2, in which the AICA approaches the AFB from a superior or inferior direction, with the AICA meatal loop passing through the AFB between the NI and CN VII (5 of 34, 15%); (3) pattern 3, in which the AICA approaches the AFB from an inferior direction, with the meatal loop being inferior to the AFB and not passing through the AFB or having a post bifurcation AICA branch passing through the NI rootlets (5 of 34, 15%); (4) pattern 4, in which the AICA approaches the AFB from an inferior direction, with the AICA meatal loop passing through the AFB between the NI rootlets (4 of 34, 12%); and (5) pattern 5 (miscellaneous), in which the AICA approaches the AFB from a superior or inferior direction with the AICA meatal loop being anterior or superior to the AFB and not passing through the AFB (5 of 34, 15%). Figure 10 illustrates these common patterns.

DISCUSSION

In this study, we present a detailed microanatomy of the NI and its relationship with the AICA-AFB neurovascular complex. We found that the most common configuration of NI consists of the nerve first originating from the proximal premeatal segment of CN VIII and joining CN VII at the IAC fundus, with the AICA passing between the NI and CN VIII. We also categorized the most common composite patterns of interrelations between AICA, NI, and AFB. These microanatomical details may be useful for the CPA surgeon, especially when the identification of the NI is critical, such as during the microsurgical treatment of the GN. GN, described by Hunt in 1937,[10] is a rare condition characterized by severe paroxysmal pain at the external auditory canal. The etiology of GN is unclear but believed to involve compression of the NI rootlets by AICA.[21] Notably, the meatal loop of the AICA entering the IAC is considered a risk factor for NI or CN VII compression.[12] Surgical treatments of GN have consisted of rhizotomy and MVD of the NI, which may result in immediate postoperative pain relief.[11,14] However, postoperative complications are not uncommon. In one instance, Fernandes *et al.*[9] reported in their case series of NI MVD that 4 of 8 patients had permanent hearing loss or hemifacial paresthesia. These permanent long-term complications have been attributed to poor preoperative visualization of the neurovascular bundle at the CPA and a lack of understanding of the NI distribution. In addition, the NI has been linked to tumor pathology. Schwannomas from the NI have been reported to affect CN VII, although it is more common that the CN VII proper is involved.[16,19,20] In a rare instance, Rodgers *et al.*[17] also described resection of an NI meningioma.[17] From these case reports, tumors deriving from the NI were frequently mistaken for a CN VII etiology on MR imaging. Thus, surgeons conducting operations at the CPA, whether it be a rhizotomy, MVD, or tumor resection, would benefit from developing a topographic perspective of the IAC neurovasculature to anticipate anatomical variations imperceptible on imaging.

Microanatomical highlights

NI rootlets

Earlier studies have shown that the NI usually comprises 2–5 rootlets, which is similar to our finding of a median of 4 rootlets (interquartile range, 3–5).[1,13,15] One specimen had an NI with 11 rootlets, which shows the importance of looking for all the NI rootlets when it is surgically indicated (i.e., during rhizotomy). The rootlets most commonly originated at the proximal premeatal segment of CN VIII (57%, 81 of 141), although one-third of all rootlets originated at the brainstem. A consistent pattern was also seen regarding the insertion point of the rootlets onto the CN VII (i.e., the fundal segment was the most common point of insertion [63%, 89 of 141]). Overall, 90% (127 of 141) of rootlets joined CN VII within the IAC, but a significant minority (10%, 14 of 141) merged with CN VII at its premeatal segment.

AICA and NI

As the AICA leaves the basilar artery to course laterally toward the AFB, it may approach the AFB from an inferior (most common) or a superior trajectory. When the AICA takes its usual approach inferiorly toward the AFB, the origin and insertion of the NI rootlets were as one would usually expect — proximal premeatal and fundal, respectively. However,

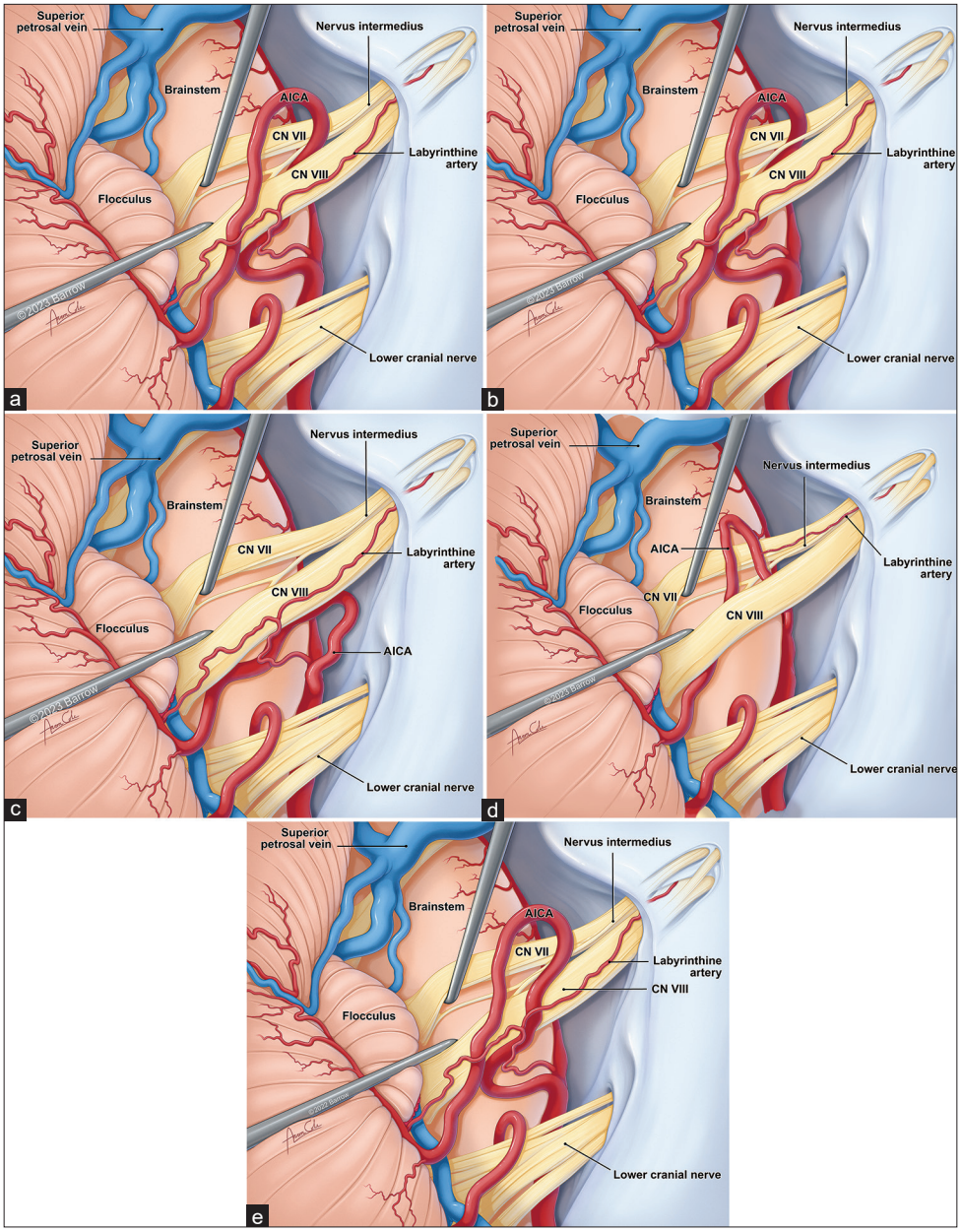

Figure 10: Artist's illustration of the most common composite patterns of neurovascular relationships in the cerebellopontine angle regarding the nervus intermedius (NI). (a) In pattern 1, the AICA approaches the acoustic-facial bundle (AFB) from a superior or inferior direction, with the AICA meatal loop passing through the AFB between the NI and CN VIII (44%). (b) In pattern 2, the AICA approaches the AFB from a superior or inferior direction, with the AICA meatal loop passing through the AFB between the NI and CN VII (15%). (c) In pattern 3, the AICA approaches the AFB from an inferior direction, with the meatal loop being inferior to the AFB and not passing through the AFB or having a post bifurcation AICA branch passing through the NI rootlets (5%). (d) In pattern 4, the AICA approaches the AFB from an inferior direction, with the AICA meatal loop passing through the AFB between the NI rootlets (12%). (e) In pattern 5 (miscellaneous), the AICA approaches the AFB from a superior or inferior direction with the AICA meatal loop being anterior or superior to the AFB and not passing through the AFB (15%). AICA: Anterior inferior cerebellar artery, CN: Cranial nerve. *Used with permission from Barrow Neurological Institute, Phoenix, Arizona.*

when the AICA approached the AFB from a superior trajectory (4 of 34, 12%), the most common point of origin of the NI was the brainstem. Interestingly, with this AICA-AFB relationship, a significant number (4 of 18, 22%) of insertion points onto CN VIII was at the premeatal segment.

Twenty five of 34 AICAs (73%) crossed through the AFB complex. This pattern is important because, in these cases, the AICA most commonly coursed between the NI and CN VIII. However, in a significant number of specimens, it crossed the AFB, passing between CN VII and the NI or through the NI rootlets. Therefore, the surgeon should understand these variable relationships and recognize their patterns [Figure 10].

A notable exception was found regarding the relationship between the meatal loop of the AICA and the IAC. When the AICA meatal loop was medial to the IAC, a higher proportion of the NI rootlets originated from the distal premeatal segment of CN VIII (18% vs. 6%) and fewer rootlets originated from the brainstem (22% vs. 38%), both of which differences were statistically significant ($P < 0.05$) [Figure 8].

Applied microsurgical anatomy

From an operative perspective, our study shows that the microanatomy of the NI is extremely variable. However, certain common patterns could be identified and used as a guide to help identify the NI during surgery [Figure 10]. Our findings emphasize the importance of seeking other sources of information to identify NI reliably intraoperatively. Although the NI is not seen on computed tomography or magnetic resonance imaging (MRI) at 1.5T, Burmeister *et al*.[6] did visualize the NI on high-resolution MRI at 3T in 70% of their patients. Detailed anatomical knowledge of the CPA is still required to assess such advanced imaging. The 3T MRI is limited to visualizing a single NI and cannot delineate individual NI rootlets. In addition to a surgeon's anatomical knowledge and CPA imaging, electrophysiology can be utilized to distinguish the NI. Ashram *et al*.[5] reported that NI stimulation resulted in low-amplitude (11.1 μV) and long-latency (11.1 ms) responses at the orbicularis oris for 33 patients undergoing intraoperative facial monitoring for operations at the CPA. Alfieri *et al*.[2] recently described successful NI stimulation for 81% of patients undergoing vestibular schwannoma resections. They recorded similar amplitude (10.8 μV) and latency (8.5 ms) responses from the NI and also noted a clear distinction from CN VII (amplitude 741 μV, latency 5.6 ms).

Overall, the key relationships between the NI and AICA identified in this study further contribute to the recently growing body of literature elucidating CPA anatomy. The surgeon should be vigilant of the NI origin and insertion variants and look to the AICA to aid with the identification of the NI. Understanding specific AICA and meatal loop orientations associated with specific NI rootlet origins improves preoperative imaging assessment and intraoperative decision-making. Ultimately, the goal is to increase the precision and safety of CPA microsurgery and decrease NI-related complications.

CONCLUSION

Variations in NI rootlet origins appear with specific orientations of the meatal loop of the AICA at the IAC. This study illustrates expected NI-AICA relationships that surgeons can anticipate in preoperative image assessments and intraoperative exploration of the CPA. It is important to note that the origin and insertion points of the NI remain unpredictable. Consideration of the AICA path helps with such clarification, but anatomic data are insufficient for this purpose. Preoperative high-definition imaging and intraoperative physiology are invaluable adjuncts to the microanatomical patterns presented in the current study.

Declaration of patient consent

Patient's consent not required as there are no patients in this study.

Financial support and sponsorship

This study was funded in part by funds from the Newsome Chair in Neurosurgery Research held by Dr. Preul and the Barrow Neurological Foundation.

Conflicts of interest

There are no conflicts of interest.

REFERENCES

1. Alfieri A, Fleischhammer J, Peschke E, Strauss C. The nervus intermedius as a variable landmark and critical structure in cerebellopontine angle surgery: An anatomical study and classification. Acta Neurochir (Wien) 2012;154:1263-8.
2. Alfieri A, Rampp S, Strauss C, Fleischhammer J, Rachinger J, Scheller C, *et al*. The relationship between nervus intermedius anatomy, ultrastructure, electrophysiology, and clinical function. Usefulness in cerebellopontine microsurgery. Acta Neurochir (Wien) 2014;156:403-8.
3. Alfieri A, Strauss C, Prell J, Peschke E. History of the nervus intermedius of Wrisberg. Ann Anat 2010;192:139-44.
4. Alonso F, Kassem MW, Iwanaga J, Oskouian RJ, Loukas M, Demerdash A, *et al*. Anterior inferior cerebellar arteries juxtaposed with the internal acoustic meatus and their relationship to the cranial nerve VII/VIII complex. Cureus

2017;9:e1570.
5. Ashram YA, Jackler RK, Pitts LH, Yingling CD. Intraoperative electrophysiologic identification of the nervus intermedius. Otol Neurotol 2005;26:274-9.
6. Burmeister HP, Baltzer PA, Dietzel M, Krumbein I, Bitter T, Schrott-Fischer A, *et al*. Identification of the nervus intermedius using 3T MR imaging. AJNR Am J Neuroradiol 2011;32:460-4.
7. Esposito G, Messina R, Carai A, Colafati GS, Savioli A, Randi F, *et al*. Cochleovestibular nerve compression syndrome caused by intrameatal anterior inferior cerebellar artery loop: Synthesis of best evidence for clinical decisions. World Neurosurg 2016;96:556-61.
8. Fortuna A, La Torre E, Forni C. The cisternal segment of the nevus intermedius of Wrisberg: An anatomical study under the operating microscope. Acta Neurochir (Wien) 1972;27:53-62.
9. Fernandes EG, van Doormaal T, de Ru S, Miller K, Han KS. Microvascular decompression of the VII/VIII cranial nerve complex for the treatment of intermediate nerve neuralgia: A retrospective case series. Oper Neurosurg (Hagerstown) 2018;15:378-85.
10. Hunt JR. Geniculate neuralgia (neuralgia of the nervus facialis). Arch Neurol Psychiatry 1937;37:253-85.
11. Inoue T, Shima A, Hirai H, Suzuki F, Matsuda M. Nervus intermedius neuralgia treated with microvascular decompression: A case report and review of the literature. NMC Case Rep J 2017;4:75-8.
12. McDermott AL, Dutt SN, Irving RM, Pahor AL, Chavda SV. Anterior inferior cerebellar artery syndrome: Fact or fiction. Clin Otolaryngol Allied Sci 2003;28:75-80.
13. Oh CS, Chung IH, Lee KS, Tanaka S. Morphological study on the rootlets comprising the root of the intermediate nerve. Anat Sci Int 2003;78:111-3.
14. Peris-Celda M, Oushy S, Perry A, Graffeo CS, Carlstrom LP, Zimmerman RS, *et al*. Nervus intermedius and the surgical management of geniculate neuralgia. J Neurosurg 2018;131:343-51.
15. Rhoton AL Jr., Kobayashi S, Hollinshead WH. Nervus intermedius. J Neurosurg 1968;29:609-18.
16. Rizer FM, Guthikonda M, Lippy WH, Schuring AG. Simultaneous presentation of facial nerve neuroma and otosclerosis. Am J Otol 1994;15:427-30.
17. Rodgers B, Chamoun R, Newell K, Lin J. Nervus intermedius meningioma. J Laryngol Otol 2014;128:543-6.
18. Rupa V, Saunders RL, Weider DJ. Geniculate neuralgia: The surgical management of primary otalgia. J Neurosurg 1991;75:505-11.
19. Scheller C, Rachinger J, Prell J, Kornhuber M, Strauss C. Schwannoma of the intermediate nerve. J Neurosurg 2008;109:144-8.
20. Sherman JD, Dagnew E, Pensak ML, van Loveren HR, Tew JM Jr. Facial nerve neuromas: Report of 10 cases and review of the literature. Neurosurgery 2002;50:450-6.
21. Tang IP, Freeman SR, Kontorinis G, Tang MY, Rutherford SA, King AT, *et al*. Geniculate neuralgia: A systematic review. J Laryngol Otol 2014;128:394-9.
22. Tubbs RS, Steck DT, Mortazavi MM, Cohen-Gadol AA. The nervus intermedius: A review of its anatomy, function, pathology, and role in neurosurgery. World Neurosurg 2013;79:763-7.

How to cite this article: Tayebi Meybodi A, Liang AS, Mokhtari P, Moreira LB, Zhao X, Lawton MT, *et al*. Nervus intermedius: Microsurgical and anatomic relationships to the cerebellopontine angle neurovascular complex. Surg Neurol Int 2023;14:37.

SUPPLIMENTAL FIGURES

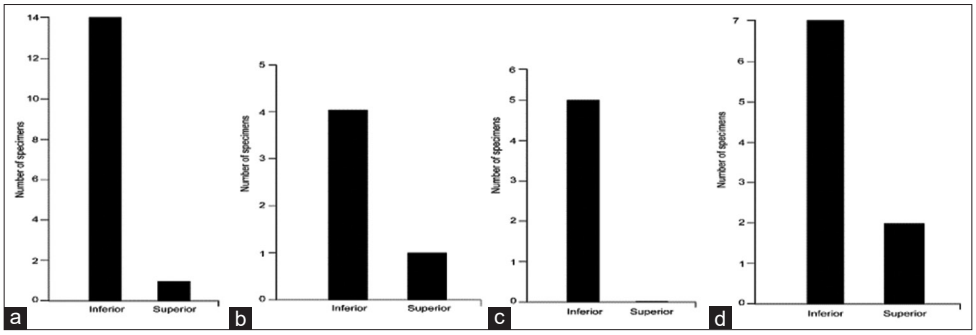

Supplemental Figure 1: Distribution of the directions of approach of the anterior inferior cerebellar artery (AICA) toward the acoustic-facial bundle (AFB) showing the relationships of the AICA with the AFB roots. (a) Between the nervus intermedius (NI) and cranial nerve (CN) VIII (n = 15). (b) Between the NI and CN VII (n = 5). (c) Through the NI rootlets (n = 5). (d) No relationship (n = 9). *Used with permission from Barrow Neurological Institute, Phoenix, Arizona.*

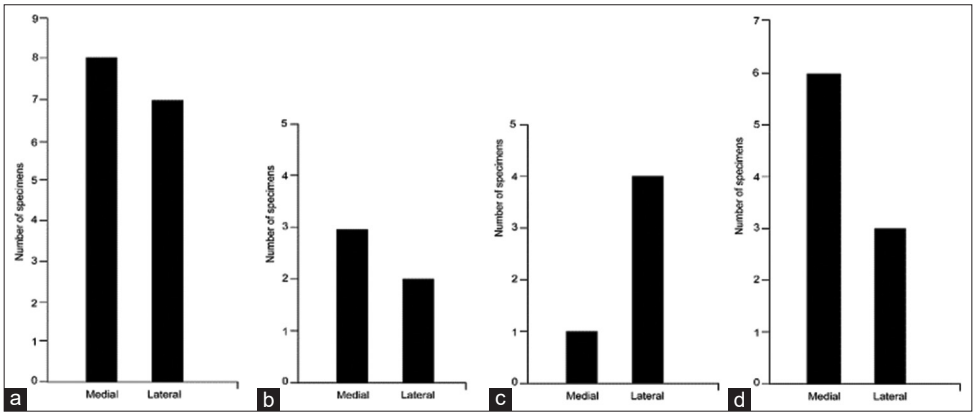

Supplemental Figure 2: Distribution of the relationships between the anterior inferior cerebellar artery (AICA) meatal loop and the meatus of the internal auditory canal (IAC) showing the relationships of the AICA with the acoustic-facial bundle roots. (a) Between the nervus intermedius (NI) and cranial nerve (CN) VIII (n = 15). (b) Between the NI and CN VII (n = 5). (c) Through the NI rootlets (n = 5). (d) No relationship (n = 9). *Used with permission from Barrow Neurological Institute, Phoenix, Arizona.*