ScientificScholar®
Knowledge is power
Publisher of Scientific Journals

www.surgicalneurologyint.com

Surgical Neurology International

Editor-in-Chief: Nancy E. Epstein, MD, Clinical Professor of Neurological Surgery, School of Medicine, State U. of NY at Stony Brook.

SNI: Spine

Editor
Nancy E. Epstein, MD
Clinical Professor of Neurological Surgery, School of Medicine, State U. of NY at Stony Brook

SNI
Open Access

Case Report

Case of incidental thoracic spinal dumbbell hemorrhagic arachnoid cyst and tentorial metastasis from breast carcinoma

Gianluca Scalia[1], Roberta Costanzo[2], Manikon Poullay Silven[2], Domenico Gerardo Iacopino[2], Giovanni Federico Nicoletti[1], Gianluca Galvano[3], Giuseppe Emmanuele Umana[4]

[1]Department of Head and Neck Surgery, Neurosurgery Unit, Garibaldi Hospital, Catania, [2]Neurosurgical Clinic, AOUP "Paolo Giaccone," Post Graduate Residency Program in Neurologic Surgery, Department of Biomedicine Neurosciences and Advanced Diagnostics, School of Medicine, University of Palermo, Palermo, [3]Department of Diagnostic Imaging, Interventional Radiology and Neuroradiology, Garibaldi Hospital, [4]Department of Neurosurgery, Cannizzaro Hospital, Catania, Italy.

E-mail: *Gianluca Scalia - gianluca.scalia@outlook.it; Roberta Costanzo - robertacostanzo3@gmail.com; Manikon Poullay Silven - rajastudio@msn.com; Domenico Gerardo Iacopino - gerardo.iacopino@gmail.com; Giovanni Federico Nicoletti - gfnicoletti@alice.it; Gianluca Galvano - gianlucagalvano@gmail.com; Giuseppe Emmanuele Umana - umana.nch@gmail.com

***Corresponding author:**
Gianluca Scalia,
Deaprtment of Head and Neck Surgery, Neurosurgery Unit, Garibaldi Hospital, Catania, Italy.

gianluca.scalia@outlook.it

Received : 19 January 2023
Accepted : 28 January 2023
Published : 10 February 2023

DOI
10.25259/SNI_66_2023

Quick Response Code:

ABSTRACT

Background: Spinal arachnoid cysts (SACs) in adults are typically acquired dural defects following trauma, inflammation, or infection. Brain metastases from breast cancer account for 5–12% of all CNS metastases and are mostly leptomeningeal. Here, the authors reported a 50-year-old female treated for a tentorial metastasis from breast carcinoma that underwent chemotherapy and radiotherapy. Three months later, she presented with a thoracic spinal extradural dumbbell hemorrhagic arachnoid cyst.

Case Description: A 50-year-old female underwent a left retrosigmoid suboccipital craniectomy for microsurgical removal of a tentorial metastasis attributed to poorly differentiated breast carcinoma (i.e., comedonic pattern). The patient subsequently underwent both chemotherapy and radiotherapy for accompanying bony metastases. Three months later, she experienced the onset of severe posterior thoracic pain. When the thoracic magnetic resonance imaging revealed a hyperintense "dumbbell" extradural T10–T11 lesion, she underwent a T10–T11 laminectomy for marsupialization and excision of the hemorrhagic lesion. The histological examination revealed blood and arachnoid tissue within a benign SAC, without accompanying tumor. Her postoperative course was uneventful, and she was discharged on postoperative day 3.

Conclusion: A 50-year-old female underwent a left retrosigmoid suboccipital craniectomy for removal of a tentorial metastasis from breast carcinoma, followed by radiation/chemotherapy. Three months later, she hemorrhaged into an MR-documented T10–T11 dumbell extradural SAC that was successfully treated with laminectomy, marsupialization, and excision.

Keywords: Arachnoid cyst, Dumbbell, Hemorrhage, Spine, Tentorium

INTRODUCTION

Spinal arachnoid cysts (SACs) in adults typically present with back pain and/or signs of myelopathy. They are physiologically attributed to acquired dural defects following trauma, inflammation, or infection.[2,10] There is scant literature regarding spontaneous hemorrhages into SAC. Independently,

breast metastases account for 5–12% of brain lesions and are mostly attributed to leptomeningeal spread.[1] Here, a 50-year-old female first underwent a suboccipital craniectomy to remove a tentorial metastasis from breast carcinoma followed by radiation and chemotherapy. Three months later, she presented with a spontaneous hemorrhage into a T10/T11 spinal dumbbell hemorrhagic SAC that was successfully managed with laminectomy, marsupialization, and excision.

CASE PRESENTATION

Seven years earlier, she underwent a left inferior quadrantectomy and hormonal/radiotherapy for a Grade II breast-ductal carcinoma *in situ*. She had undergone (Eastern Cooperative Oncology Group [ECOG] performance status 0) chemotherapy (cyclin inhibitor) and radiotherapy for bony metastases (ten therapy sessions with a daily fractionation of 3 Gy and a total of 30 Gy). This 50-year-old female now presented with worsening headache and nausea but neurologically intact, attributed to a computed tomography (CT) documented large left cerebellar slightly hyperdense lesion (i.e., 43 × 40 mm), with a wide tentorial dural base. The contrast brain magnetic resonance imaging (MRI) showed a large left cerebellar lesion (i.e. 45 mm × 40 mm × 24 mm) that inhomogeneously enhanced with an accompaning tentorial"dural tail" highly consistent with a meningioma [Figures 1a-c]. Therefore, she underwent a left retrosigmoid suboccipital craniectomy and microsurgical removal of the lesion. The patient was discharged in the postoperative day 7 and underwent brain MRI that documented a complete resection of the lesion [Figures 2a-c].

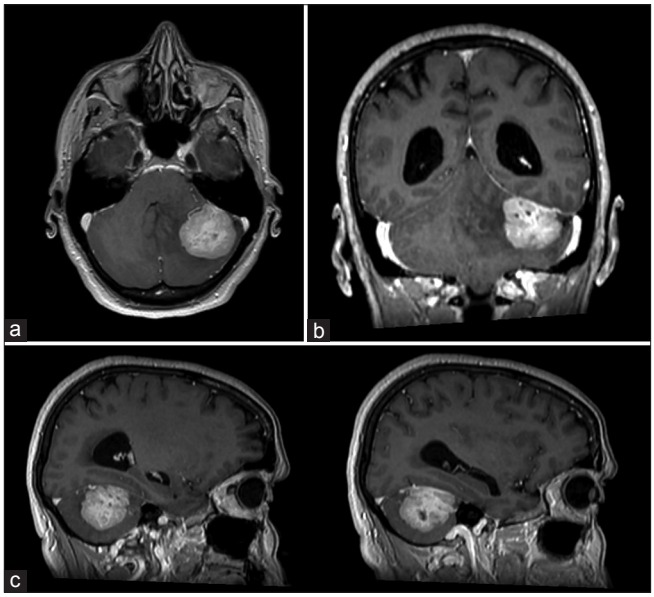

Figure 1: Axial (a), coronal (b), and sagittal (c) T1-weighted magnetic resonance imaging with gadolinium images showing a left cerebellar lesion with a maximum diameter of 43 × 40 mm, with inhomogeneous enhancement, tentorial attachment and "dural tail" sign, highly suggestive for left tentorial meningioma.

Three months later, she presented with intense posterior thoracic pain (VAS score 7/10) and paresthesia, but neurologically intact. The whole body CT examination documented a hypodense "dumbbell" T10–T11 lesion (i.e., 26 mm) involving the right vertebral pedicle/T10 lamina [Figures 3a-c]. The thoracic MRI confirmed the presence of a hyperintense lesion with the T10 vertebral body accompanied by scalloping [Figures 4a and b].

SAC surgery and adjunctive therapies

She underwent a T10–T11 laminectomy that revealed an extradural lesion with a capsule indistinguishable from the dura. The capsule was incised, marsupialized, and removed, along with resection of the hemorrhage [Figures 5a-c]. The 48-h postoperative MR confirmed complete lesion resection [Figures 6a and b]. Her postoperative course was unveventful, she was discharged postoperative day 3. She was later treated with adjuvant chemotherapy and radiotherapy.

Histology and immunohistochemistry of the breast metastasis

The histological examination documented a tentorial metastasis from poorly differentiated carcinoma. Within the nodular, there were areas of central necrosis (comedonic pattern). Immunohistochemistry was positive for GATA-Binding protein 3 (GATA-3), Epithelial membrane antigen (EMA) and estrogen receptors, negativity for progesterone receptors, chromogranin, human epidermal growth factor receptor 2, synaptophysin, Thyroid Transcription Factor 1

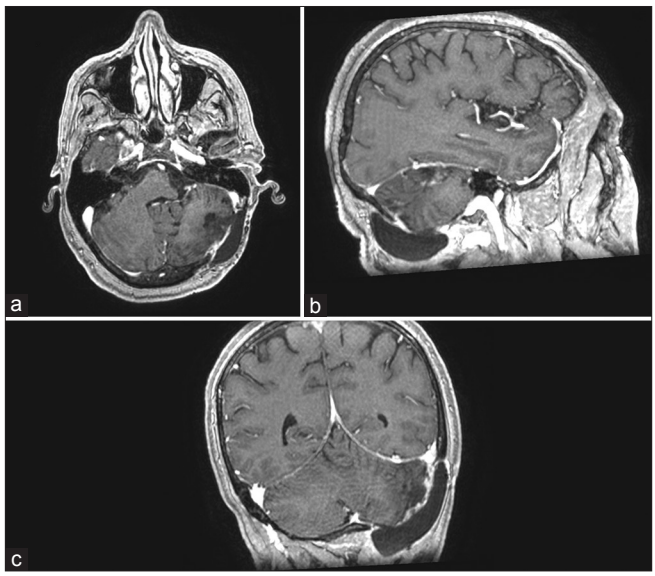

Figure 2: Postoperative axial (a), sagittal (b), and coronal (c) T1-weighted magnetic resonance imaging with gadolinium images documented a gross total resection of the lesion.

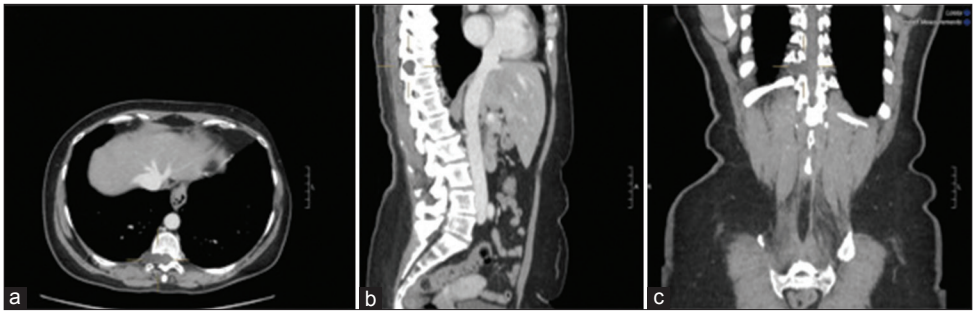

Figure 3: Axial (a), sagittal (b), and coronal (c) computed tomography vertebral and abdomen scans showing a hypodense "dumbbell" T10–T11 lesion of about 26 mm involving the right vertebral pedicle and the right T10 lamina.

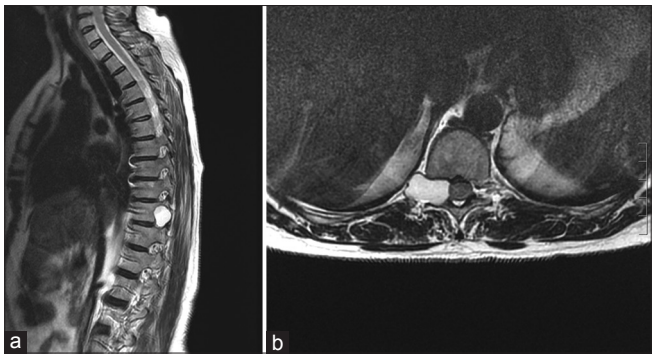

Figure 4: Sagittal (a) and axial (b) thoracic spinal T2-weighted magnetic resonance imaging sequences confirmed the presence of a hyperintense extradural lesion determining also T10 vertebral body scalloping.

(TTF-1), Cytokeratin 7 (CK7), p40, and a Ki67 of 70%. The morphological and immunohistochemical profile indicated the mammary origin of the neoplasm.

Histology of SAC

The histological examination of the spinal extradural lesion showed blood and arachnoid within sclerotic tissue, consistent with a SAC.

DISCUSSION

Etiology of SACs

SACs are benign lesions commonly found in pediatric patients with accompanying congenital disorders. SACs in adults are typically idiophatic , or rarely related to trauma, infection, inflammation, or iatrogenic.[7] Most are found in the thoracic spine in intradural locations followed by extradural sites.[6] They may also be encountered in the ventral, lumbar, or cervical spinal canals. MRI and CT scan can be considered the gold standard to evaluate and differentiate these lesions from tumors or infection, and symptoms depend largelyon their locations.[5] In the present case, the CT scan and MRI studies were highly suggestive of a dumbbell metastasis, especially in the presence of bone scalloping, not typical of SACs.

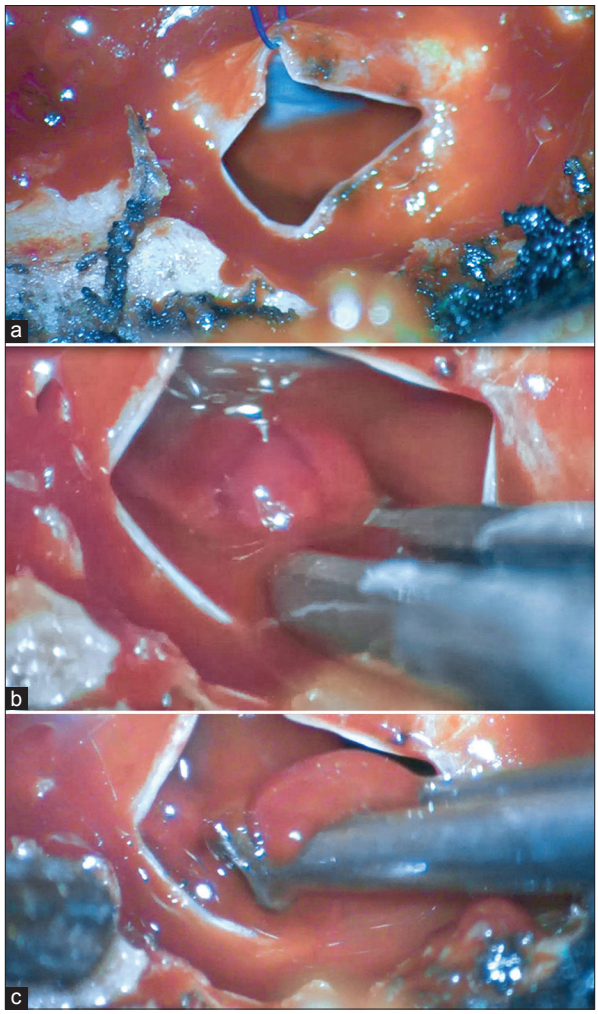

Figure 5: Intraoperative images showing the incised capsule of the cyst (a), marsupialization and removal of hemorrhagic lesion with blood clots using a Yasargil forceps (b and c).

Classification and treatment

According to Nabors classification, SAC can be divided in extradural cysts without nerve root involvement (type I) (i.e., subclassified in IA "extradural arachnoid cyst" and IB

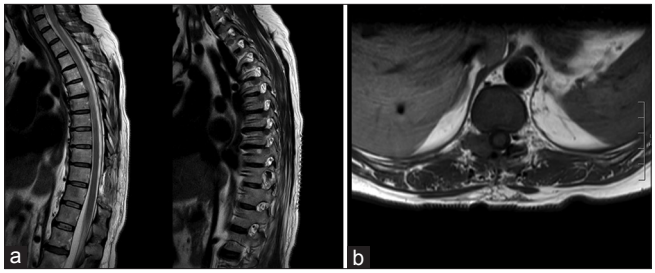

Figure 6: Postoperative sagittal (a) and axial (b) T1-weighted magnetic resonance imaging sequences documented a complete removal of the lesion.

"sacral meningocele"); II extradural extramedullary cysts with spinal nerve fibers involvement (i.e., "Tarlov's perineural cyst" or "spinal nerve root diverticulum"); III spinal intradural cysts (i.e., "intradural arachnoid cyst").[8] Based on this classification system, our case would be classified as type IA with dumbbell characteristic.[3,4] Hemorrhages into arachnoid cysts are rare and may be additionally associated with chronic subdural hematomas.

Here, the unusual onset of hemorrhage into this T10/T11 lesion was attributed to the prior radiation therapy. The main surgical treatment is the surgical decompression followed by resection, fenestration/marsupialization of the cyst, and/or the placement of a cystoperitoneal/subarachnoid shunt.

Tentorial breast metastasis

Metastases from breast cancer, the most common tumors causing intracranial dural metastases, spread through the leptomeningeas. Nevertheless, they can also be found attached to dural sites.[9] Here, it was difficult to differentiate at the T10/11 level, whether this was a hemorrhage into a spine metastasic lesion versus a SAC, and a brain metastasis from a lesion highly suggestive for a meningioma (i.e., single lesion without bony erosion and atypical dural tail sign).

CONCLUSION

This case involved a patient with a cranial metastasis from breast cancer (i.e., diagnosed 7 years earlier as an *in situ* lesion) who also later incidentally presented with a spontaneous hemorrhage into a T10–T11 dumbbell extradural SAC that was successfully excised.

Declaration of patient consent

Patient's consent not required as patient's identity is not disclosed or compromised

Financial support and sponsorship

Nil.

Conflicts of interest

There are no conflicts of interest.

REFERENCES

1. Ehsan H, Imtiaz H, Sana MK, Sheikh MM, Wahab A. Relapsed breast cancer complicated by isolated brain metastasis. Clin Case Rep 2020;9:887-90.
2. Fam MD, Woodroffe RW, Helland L, Noeller J, Dahdaleh NS, Menezes AH, *et al*. Spinal arachnoid cysts in adults: Diagnosis and management. A single-center experience. J Neurosurg Spine 2018;29:711-9.
3. Hong JC, Kim MS, Chang CH, Kim SH. Arachnoid cyst with spontaneous intracystic hemorrhage and chronic subdural hematoma. J Korean Neurosurg Soc 2008;43:54-6.
4. Iaconetta G, Esposito M, Maiuri F, Cappabianca P. Arachnoid cyst with intracystic haemorrhage and subdural haematoma: Case report and literature review. Neurol Sci 2006;26:451-5.
5. Kadono Y, Yuguchi T, Ohnishi Y, Iwatsuki K, Yoshimine T. A symptomatic spinal extradural arachnoid cyst with lumbar disc herniation. Case Rep Orthop 2015;2015:250710.
6. Marrone S, Kharbat AF, Palmisciano P, Umana GE, Haider AS, Iacopino DG, *et al*. Thoracic spinal extradural arachnoid cyst: A case report and literature review. Surg Neurol Int 2022;13:55.
7. Mastantuoni C, Pizzuti V, Ricciardi F, D'Elia A, Leonetti S, Colonnese C, *et al*. Cervical spine arachnoid cyst complicated by spontaneous intracystic hemorrhage: Case report and review of the literature. Surg Neurol Int 2022;13:427.
8. Nabors MW, Pait TG, Byrd EB, Karim NO, Davis DO, Kobrine AI, *et al*. Updated assessment and current classification of spinal meningeal cysts. J Neurosurg 1988;68:366-77.
9. Nayak L, Abrey LE, Iwamoto FM. Intracranial dural metastases. Cancer 2009;115:1947-53.
10. Schmutzer M, Tonn JC, Zausinger S. Spinal intradural extramedullary arachnoid cysts in adults-operative therapy and clinical outcome. Acta Neurochir (Wien) 2020;162:691-702.

How to cite this article: Scalia G, Costanzo R, Poullay Silven M, Iacopino DG, Nicoletti GF, Galvano G, *et al*. Case of incidental thoracic spinal dumbbell hemorrhagic arachnoid cyst and tentorial metastasis from breast carcinoma. Surg Neurol Int 2023;14:50.