



Original Article

## Glossopharyngeal and vagoglossopharyngeal neuralgia: Long-term surgical outcomes in a single institution

Rogelio Revuelta-Gutiérrez<sup>1</sup>, Fernando Piñon-Jiménez<sup>1</sup>, Oscar Rubén Contreras-Vázquez<sup>1</sup> , Lourdes Olivia Vales-Hidalgo<sup>2</sup>, Jaime Jesús Martínez-Anda<sup>1</sup> 

Departments of <sup>1</sup>Neurosurgery and <sup>2</sup>Neuro-otology, National Institute of Neurology and Neurosurgery, Manuel Velasco Suárez, Ciudad de México, Mexico.

E-mail: Rogelio Revuelta-Gutiérrez - rogelio7revuelta@gmail.com; Fernando Piñon-Jiménez - fernandopj195@gmail.com;

\*Oscar Rubén Contreras-Vázquez - osrcv1@gmail.com; Lourdes Olivia Vales-Hidalgo - valpoo@gmail.com; Jaime Jesús Martínez-Anda - dr.martinezanda@gmail.com



### \*Corresponding author:

Oscar Rubén Contreras-Vázquez,  
Department of Neurosurgery,  
National Institute of Neurology  
and Neurosurgery, Ciudad de  
México, Mexico.

osrcv1@gmail.com

Received : 18 June 2023

Accepted : 06 July 2023

Published : 28 July 2023

DOI

10.25259/SNI\_518\_2023

Quick Response Code:



### ABSTRACT

**Background:** Glossopharyngeal neuralgia (GPN) and vagoglossopharyngeal neuralgia (VGPN) are infrequent syndromes that can have great negative impact on a patient's quality of life. The objective of this study is to describe the characteristics and long-term results of patients with GPN-VGPN who are treated surgically with microvascular decompression (MVD) in one institution.

**Methods:** This is a retrospective series of 20 patients with the diagnosis of GPN-VGPN who underwent MVD. Demographic characteristics, surgical results, complications, and long-term follow-up were analyzed.

**Results:** The mean age of symptom onset was 51.25 years and the majority of patients were women (60%). The posterior inferior cerebellar artery was the main offending vessel (75%). The immediate MVD success rate was 100%, but during follow-up, two patients (10%) were diagnosed with VGPN and both cases presented pain recurrence. The mean follow-up was 120.4 (25–333) months. VGPN ( $P = 0.005$ ) and a  $\geq 5$  day hospital stay ( $P = 0.032$ ) were associated with unsuccessful outcomes. Two complications were documented, which resolved without sequelae. There was no surgical mortality.

**Conclusion:** MVD is an effective and safe treatment for long-term pain relief of GPN-VGPN. VGPN and a prolonged hospital stay were associated with poor outcomes. More studies are required to confirm these findings.

**Keywords:** Glossopharyngeal neuralgia, Microvascular decompression, Vagoglossopharyngeal neuralgia

### INTRODUCTION

Glossopharyngeal neuralgia (GPN), formerly known as vagoglossopharyngeal neuralgia (VGPN),<sup>[9]</sup> accounts for approximately 0.2–1.3% of all facial pain syndromes.<sup>[1,7]</sup> Population studies have reported an annual incidence of 0.2–0.8/100,000 inhabitants. It usually presents itself in adulthood, with a peak symptom onset at around 50 years of age, and it is most frequently found in women. The left side is predominantly affected, with only 2% of patients presenting bilateral involvement.<sup>[22,26]</sup> GPN is characterized by paroxysmal, unilateral shooting electric shock-like pain in glossopharyngeal nerve territory, although it may also occur in areas innervated by branches of the vagus nerve. Pain is experienced in the ear, base of the tongue, tonsillar fossa, and/or below the angle of the jaw. It is usually triggered by swallowing, speaking, yawning, or coughing.<sup>[9]</sup> Approximately 10% of patients can have accompanying vagal symptoms

This is an open-access article distributed under the terms of the Creative Commons Attribution-Non Commercial-Share Alike 4.0 License, which allows others to remix, transform, and build upon the work non-commercially, as long as the author is credited and the new creations are licensed under the identical terms.

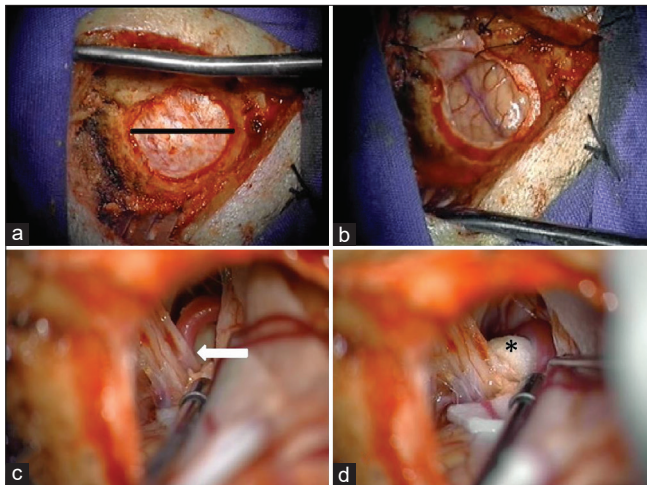
©2023 Published by Scientific Scholar on behalf of Surgical Neurology International

such as cough, hoarseness, seizures, bradycardia, sweating, and syncope and rarely may even present a heart attack.<sup>[19,24,25,27]</sup> Some authors recommend using the term VGPN when presenting the latter, as they are associated with vagus nerve involvement.<sup>[9,13,28]</sup>

The pathophysiology of classic GPN has been known for several decades, the etiology of which is usually vascular compression in the root entry zone (REZ) in 95% [Figure 1] and the remaining 5% in the rest of the nerve trajectory. At present, medical management based on anticonvulsants such as carbamazepine (CBZ), oxcarbazepine, phenytoin, baclofen, and gabapentin is the first-line of treatment, as used in trigeminal neuralgia (TN).<sup>[3,4,9,20]</sup> Response to the different drugs is variable, generally being favorable at the beginning and tending toward therapeutic failure over time. Surgical treatment is typically reserved for patients who have resistance to medical treatment; defined as incapacitating pain that cannot be controlled with high doses of medication, and/or intolerance to pharmacological treatment due to their adverse side effects.

Microvascular decompression (MVD) is the main surgical technique performed. It has shown good results, with success rates of around 90%. However, given the low incidence of GPN-VGPN, there are currently few studies which identify, describe, and analyze prognostic factors in a long-term cohort.<sup>[5,8,12,28,29]</sup>

Our case series aims to describe the characteristics and long-term outcomes of patients diagnosed with GPN-VGPN who were surgically treated with MVD in a single institution.



**Figure 1:** Microvascular decompression through a keyhole craniectomy in a microasterional approach. (a) Microasterional craniotomy performed with a diameter of 2.5 cm exposes the dura with autostatic retractors (black line). (b) Cerebellar hemisphere is exposed after dural opening. (c) The root entry zone and nerve pathway are identified through blunt dissection with a suction and bipolar device, where neurovascular conflict with posterior inferior cerebellar artery is observed (white arrow). (d) Teflon is placed between the nerve pathway and the offending vessel to maintain vessel retraction and avoid vascular contact (\*).

## MATERIALS AND METHODS

This retrospective study was approved by the Institution’s Ethics and Research Committees. Only patients with an established diagnosis of classical GPN who met the current International Headache Society 2018 criteria<sup>[9]</sup> were included in the study. In total, 20 patients were included during the period from January 1994 to October 2022, all of whom were being treated in the National Institute of Neurology and Neurosurgery “Manuel Velasco Suárez” (INNN) and who had a minimum follow-up of 24 months. They were all previously managed with medical treatment, presenting refractory GPN-VGPN for at least 6 months before MVD. Written informed consent was obtained before the procedure. Patients with other secondary etiologies and those with previous MVD were excluded from the study.

### Data recollection and follow-up

The medical record information was obtained by an investigator other than the surgeon Rogelio Revuelta-Gutiérrez to avoid bias. Patient data including gender, age of symptom onset, accompanying symptoms, prior medical treatments, time from symptom onset to surgery, operative findings, complications, immediate clinical outcome, and long-term follow-up were analyzed. The follow-up was carried out by obtaining information from the last clinical note in their medical records and/or by telephone calls.

The Barrow Neurological Institute Pain Intensity Score (BNIPIS) was used to classify pain intensity [Table 1]. An excellent surgical outcome was defined as those classified in class 1; those classified beyond class 2 were considered to have an unsuccessful outcome.<sup>[17]</sup>

### Statistical analyses

A descriptive analysis of the variables obtained from the sample of patients with GPN and VGPN was performed using the SPSS, IBM software, version 26. The results of the nominal, ordinal, and quantitative categorical variables were described using measures of central tendency. After the

**Table 1:** Barrow neurological institute pain intensity score (BNIPIS).

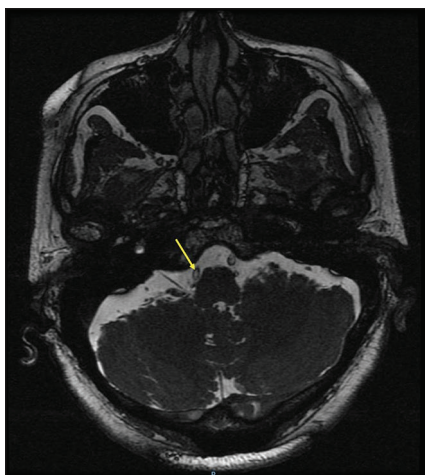
Score	Pain description
I	No pain, no medication
II	Occasional pain, no medications required
III	Some pain, adequately controlled with medications
IV	Some pain, not adequately controlled with medications
V	Severe pain or no pain relief

Adapted from Chen *et al.*<sup>[2]</sup>

descriptive statistical analysis was completed, an inferential statistical test was carried out to identify risk factors associated with a poor surgical outcome.

**Surgical technique**

Under general anesthesia, the patients were placed in the *Park Bench* position. The upper part of the shoulder was retracted and the head was rotated 60° to the opposite side of the incision site, with a slight lateral cervical inclination of 10° toward the floor to form an optimal surgical corridor. A 5 cm retrosigmoid incision centered over the asterion was performed, and a keyhole microasterional craniectomy (2.5–3 cm) was made, exposing the junction of the transverse and sigmoid sinuses [Figure 2]. A horseshoe durotomy was performed under microscope with the base located on the sigmoid sinus, then dissection was started toward the dural angle between the tentorium and the petrous surface. The cerebrospinal fluid (CSF) was released by dissecting the arachnoid cisterns with a fine aspirator, performing dynamic retraction of the cerebellar tissue assisted by a bipolar forceps. No cerebellar retractors (CR) were used. The dissection was directed caudally, identifying the inferior neurovascular complex, and getting to expose the glossopharyngeal nerve exploring the REZ to its exit through the jugular foramen looking for vascular compressing structures. Once the vascular element that compresses the glossopharyngeal nerve was identified, a blunt dissection was performed and Teflon was placed between the glossopharyngeal nerve and the compressing vessels (arterial or venous) [Figure 1].



**Figure 2:** Presurgical magnetic resonance imaging showing vascular conflict: Three-dimensional fast imaging employing steady-state acquisition (3D-FIESTA) sequence, axial image demonstrating glossopharyngeal nerve compression from the right posterior inferior cerebellar artery (yellow arrow).

**RESULTS**

During the period from January 1, 1994, to February 1, 2023, a total of 20 patients were diagnosed with GPN at the INNN neurosurgery department and were all treated using microasterional MVD approach without the use of retractors [Table 2]. This syndrome mainly affected women (12 patients–60%) in comparison to men (8–40%).

The average age of symptom onset was 51.25 ± 11.7 (26–73) years. Surgery was performed after a median of 5 years after diagnosis. The mean age at surgery was 58.9 ± 11.27 (43–83) years.

**Table 2:** Presurgical clinical data.

Characteristics	Total (n=20)
Age at symptom onset (years)	51.25±11.78 (26–73)
Age at surgery (years)	58.90±11.27 (43–83)
Sex (%)	
Female	12 (60%)
Male	8 (40%)
Affected side	
Left	15 (75%)
Right	5 (25%)
Main pain location	
Pharyngeal	18 (90%)
Preauricular	1 (5%)
Pharyngeal+preauricular+facial	1 (5%)
Pain irradiation	
Yes	9 (45%)
No	11 (55%)
Pain triggers	
Swallowing	10 (50%)
Speaking	6 (30%)
Speaking+swallowing	1 (5%)
Idiopathic	3 (15%)
Vagoglossopharyngeal neuralgia	
Yes	2 (10%)
No	18 (90%)
Vagal symptoms	
Cough+sweating	1 (5%)
Syncope	1 (5%)
Previous wrong diagnoses	
Yes	6 (30%)
No	14 (70%)
Previous wrong procedure	5 (25%)
Eagle syndrome (styloidectomy)	4 (20%)
Nonspecific oral pathology (dental extraction)	1 (5%)
Presurgical MRI findings	
Normal	10 (50%)
PICA	5 (25%)
VB	4 (20%)
Nonspecific inflammatory process	1 (5%)

PICA: Posterior inferior cerebellar artery, VB: Vertebrobasilar, MRI: Magnetic resonance imaging, n: Total patients

In 15 patients (75%), the affected side was the left, while the right side was affected in 5 patients (25%). The primary location of pain was pharyngeal in 18 patients (90%), followed by preauricular in 1 patient (5%), and pain in the pharyngeal, preauricular, and facial regions in 1 patient (5%).

Swallowing was the main trigger (ten patients – 50%), followed by speaking (six patients - 30%), with only one patient presenting both. No trigger was identified in 3 patients (15%).

Presurgical erroneous diagnoses were made in 6 patients (30%) and an erroneous procedure was performed in 5 patients (25%) without pain improvement in extrainstitutional health care centers. Four of these patients were diagnosed with Eagle Syndrome and underwent styloidectomy. One patient was diagnosed with unspecified oral pathology, treated with multiple dental extractions which caused him chewing alterations. One patient was diagnosed with TN and had no surgical procedure performed; however, he was treated pharmacologically for more than 5 years under the diagnosis of atypical TN that affected V1, predominantly in the preauricular region, and radiated to V2 and pharynx, his pain was triggered by speaking and swallowing. During the presurgical protocol, the clinical diagnosis of GPN was made based on the type of symptoms and radiological findings (vertebrobasilar [VB] dolichoectasia).

Two patients (10%) were diagnosed with VGPN based on the associated symptoms during their pain episodes. One of them presented sweating and coughing and the other presented syncope.

All the patients were treated pharmacologically for at least 6 months, without obtaining a favorable response. The most often used pharmacological regimen was CBZ in monotherapy (65%), followed by dual therapy with pregabalin and CBZ (15%), and the remaining 20% with a combination of more than three drugs. The resistance and/or intolerance to pharmacological treatment was considered a criteria for surgical treatment.

Magnetic resonance imaging (MRI) was performed in all patients, with the purpose of ruling out other etiologies. Half of the patients presented a normal MRI, with the presence of vascular conflict in the REZ of the glossopharyngeal nerve present in less than half of the patients [Figure 1]. The posterior inferior cerebellar artery (PICA) was found to be the offending vessel in five patients, the VB complex in four patients, and one patient presented an unspecified inflammatory process. It is worth mentioning that this last finding occurred in a patient with an unfavorable surgical outcome [Figure 2].

### Surgical outcomes

All patients underwent MVD for the 1<sup>st</sup> time, using a microvascular approach without the use of CR [Table 3].

Teflon was used to separate the vascular contact due to its malleability, cost, and availability.

The main offending vessel identified during surgery was the PICA in 15 patients (75%). It was found to be independent in 12 patients (60%) and associated with the superior cerebellar artery in 2 patients (10%) and with the vertebral artery (VA) in 1 patient (5%). The choroid plexus was responsible for the compression in 2 patients (10%) and the VB complex in another 2 patients (10%). No offender vessel was identified in one patient (5%).

Only one patient had intraoperative bradycardia, with no further complications. No other intraoperative complications were presented.

In the immediate postoperative (PO) period, all patients presented complete pain relief. Two patients (10%) presented postoperative complications. One presented a CSF fistula which was treated with lumbar punctures and acetazolamide, which was remitted completely without requiring surgical reintervention. Another patient presented meningitis which was treated with intravenous antibiotics, with full remission and negative cultures 2 weeks after, and was discharged without any further complications.

### Long-term follow-up

On average, patient follow-up was of  $120.40 \pm 67.33$  (range, 25–333) months. A total of 18 patients (90%) reported complete pain relief during the follow-up visits (BNIPIS 1). Only 2 patients (10%) referred pain recurrence in the outpatient clinic at the 1 month and 20 months follow-up. In both cases, monotherapy was started with minimal dosage of CBZ, achieving pain control (BNIPIS 3) without reintervention criteria. Two factors were associated with unfavorable outcomes (BNIPIS 3), vagal affection ( $P = 0.005$ ), and a hospital stay of 5 or more days ( $P = 0.032$ ).

## DISCUSSION

This study demonstrated that MVD is an effective treatment for long-term pain relief with an effectiveness rate of 90%, minor complications, and no mortality. In our series, the most common offending vessel was the PICA (60%), either alone or in combination with other vessels. Inoue *et al.*<sup>[10]</sup> describe that this frequency may be due to anatomical relationships since the PICA originates from the upper part of the VA and subsequently loops upward, causing compression at the REZ of the glossopharyngeal nerve.<sup>[10]</sup>

During follow-up, we found that the two patients that referred pain recurrence were diagnosed with VGPN, which showed statistical significance by Fisher's exact test ( $P = 0.005$ ). Although both patients were female, no statistical association was found between sex and surgical

outcome. Our experience in the INNN, as exposed in other authors' reports, shows that the term VGPN could be used when GPN is associated with autonomic symptoms due to vagal dysfunction.<sup>[9,13,28]</sup> This phenomenon is fairly rare and occurs in approximately 10% of the patients with GPN. The most common vagal symptoms are cough, hoarseness, bradycardia, sweating, hypotension, syncope, and seizures, which are usually self-limited and indolent, but nevertheless the symptoms may progress to cardiac arrest.<sup>[27]</sup>

The pathophysiology of VGPN, as explained by Elias *et al.*<sup>[6]</sup> and Taşçı *et al.*,<sup>[24]</sup> is due to the close anatomic relationship between the glossopharyngeal and vagus nerves. When there is constant irritation of the glossopharyngeal nerve, afferent nerve impulses are triggered, reaching the nucleus of the solitary tract of the midbrain, and through collateral tracts, also reach the dorsal nucleus of the vagus nerve, which supplies parasympathetic fibers to the heart, bronchi, and abdominal nerve. In addition, the carotid body and sinus nerve (Hering's nerve) run through the main trunk of the glossopharyngeal nerve and ends in the dorsal nucleus of the vagus nerve. Afferent glossopharyngeal stimuli can inhibit the vasomotor centers, leading to peripheral vasodilation and a pronounced decrease in blood pressure. Activation of this neuronal loop during severe neuralgic pain is responsible for bradycardia/asystole leading to cerebral hypoperfusion, slowing of electroencephalogram activity, syncope, and seizures.

Palanisamy *et al.*<sup>[15]</sup> and Zheng *et al.*<sup>[29]</sup> propose that recurrences or failed treatments in patients with VGPN may be due to multiple vascular contacts not observed during surgery and/or incomplete dissection of the arachnoids, leaving residual adhesions. Based on our experience, the latter factors may be associated with disease severity, but no associations with surgical outcomes were found. We believe patients with VGPN should undergo a more meticulous and exhaustive surgical exploration.

At present, there are few reports with long-term follow-up in patients with GPN and VGPN who underwent MVD, which are shown in Table 4. This may be due to lack of awareness of this condition, low incidence, and/or overlapping symptoms that can bias the physician into making an erroneous diagnosis. We would like to emphasize that these factors can result in iatrogenesis, as seen in this study, so a complete presurgical evaluation, including MRI, and differential diagnoses such as GPN and VGPN should be considered in atypical facial pain syndromes.

We present all the series of cases where MVD was performed, and a long-term follow-up was reported [Table 4]. In these studies, immediate pain relief was presented on average in 91.2% of cases, with a mean long-term pain relief of 88.6%.<sup>[5,8,12,28]</sup> In contrast, our series presented immediate PO pain relief in 100% of cases and long-term relief in 90%. The rate of complications reported in the literature varies from 3% to

**Table 3:** Postsurgical outcomes, complications and long-term follow-up.

Characteristics	Total n=20
MVD without the use of retractors	20 (100%)
CN IX	18 (90%)
CN V+IX	2 (10%)
Intraoperative complications	
Bradycardia	1 (5%)
Hemorrhage	0
Death	0
Offending vessel	
PICA	12 (60%)
Choroid plexus	2 (10%)
VB	2 (10%)
PICA+SCA	2 (10%)
PICA+Vertebral	1 (5%)
Not identified	1 (5%)
Postsurgical complications	
CSF fistula	1 (5%)
Meningitis	1 (5%)
Immediate PO pain relief BNI-PIS score	
Class 1	20 (100%)
BNI-PIS at ≥2 years	
Class 1	18 (90%)
Class 2	0
Class 3	2 (10%)
Class 4 and 5	0
BNI-PIS average follow-up	
Class 1	120.4±67.33 (25–333)
Class 3	106.75±68.68 (1–327)

BNI-PIS: Barrow neurological institute pain intensity score, CN IX: 9<sup>th</sup> cranial nerve, CN X+IX: 9<sup>th</sup> and 10<sup>th</sup> cranial nerves, n: Total patients, PICA: Posterior inferior cerebellar artery, SCA: Superior cerebellar artery, VB: Vertebrobasilar, MVD: Microvascular decompression, PO: Postoperative, CSF: Cerebrospinal fluid

15%,<sup>[5,8,12,28]</sup> with our series presenting concordant results with 10%, which were treated successfully without reintervention and any further deficit.

There is still much debate about which treatment is superior. Some authors advocate rhizotomy as the first-line surgical treatment due to its slightly higher rates of long-term pain relief; however, as it is a more invasive procedure, high rates of serious and permanent PO complications such as dysphagia and vocal cord paralysis have been described.<sup>[5,12,18,21]</sup> Du *et al.*<sup>[5]</sup> compared PO quality of life with MVD or rhizotomy, reaching the conclusion that MVD was the first-line surgical option due to the better quality of life that patients presented in long-term follow-up and the lower rate of serious and long-lasting complications. As previously discussed by Ma *et al.*,<sup>[14]</sup> rhizotomy is a simple surgical procedure and an effective treatment option for GPN and may be especially valuable in patients who are not suitable candidates for MVD, as well as for surgeons with little experience in performing this surgical technique.

**Table 4:** Comparing MVD series outcomes and follow-up.

Series	CR	n	PO immediate pain relief	Long-term pain relief	Complications	Follow-up (months)
Du <i>et al.</i> <sup>[5]</sup> (2020)	NR	67	85.1%	83.6%	3%	46.9±20.9
Zheng <i>et al.</i> <sup>[29]</sup> (2020)	Yes	46	100%	97.8%	4.3%	38±17.9
Zhao <i>et al.</i> <sup>[28]</sup> (2017)	No	35	94.3%	93.3%	5.7%	132
Franzini <i>et al.</i> <sup>[8]</sup> (2017)	NR	20	90%	85%	15%	11–240
Kim <i>et al.</i> <sup>[12]</sup> (2017)	Yes	30	86.7%	83.3%	23%	68.5
Present series	No	20	100%	90%	10%	120.4±67.33 (25–333)

CR: Cerebellar retractors, MVD: Microvascular decompression, n: Total patients, NR: Non reported, PO: Postoperative

On the other hand, Shimizu *et al.*,<sup>[23]</sup> who have ample experience in MVD, describe how the use of spatulas or CR with deep or excessive retraction increases the risk of hearing loss and nerve palsies. When using the microasterional approach, structure visualization is facilitated and the risk of presenting this type of complications lowers significantly, as demonstrated in our study.

Pommier *et al.*<sup>[16]</sup> recommends considering the Gamma Knife as a first-line treatment option, especially in elderly patients or patients who are not candidates for a surgical procedure. Gamma Knife effectiveness in GPN has reported pain relief rates of 46–64.9% and 30–45.3% over a 5 and 10 year period, respectively.<sup>[11]</sup> Based on the experience in our center, age is a relative contraindication, as MVD was performed on an 83-year-old patient who to date continues with complete pain relief. For this reason, individualization is necessary on a case by case basis, with age being only one factor related to the general condition of the patient.

Finally, although MVD appears to be a promising treatment option, further studies are required to identify the particular aspects of these syndromes in greater detail and thus be able to establish different surgical profiles that would allow us to offer better clinical outcomes to our patients.

## CONCLUSION

MVD has proven to be a safe and effective treatment option for GPN and VGPN, as it entails fewer and minor complications and overall lasting pain remission, despite the fact that surgeon experience is an influential factor on surgical outcomes. The present study is particularly transcendent due to its longer-term follow-up, as well as its unique surgical technique, in which CR and intraoperative neurophysiological monitoring are not used. However, the dispersion of follow-up length, together with the sample size, limits the value of the statistical results. It should be noted that the preoperative approach is essential for an ideal surgical outcome, so particular attention must be paid to atypical facial pain syndromes as to avoid iatrogenic causes. In addition, performing a good surgical technique, with a

detailed inspection of the clinically associated nerve path, offers the best scenario for the remission of the patient's pain.

## Declaration of patient consent

Patients' consent not required as patients' identities were not disclosed or compromised.

## Financial support and sponsorship

Nil.

## Conflicts of interest

There are no conflicts of interest.

## REFERENCES

- Chawla JC, Falconer MA. Glossopharyngeal and vagal neuralgia. *Br Med J* 1967;3:529-31.
- Chen HI, Lee JY. The measurement of pain in patients with trigeminal neuralgia. *Clin Neurosurg* 2010;57:129-33.
- Chen J, Sindou M. Vago-glossopharyngeal neuralgia: A literature review of neurosurgical experience. *Acta Neurochir (Wien)* 2015;157:311-21; discussion 321.
- Dalessio DJ. Diagnosis and treatment of cranial neuralgias. *Med Clin North Am* 1991;75:605-15.
- Du T, Ni B, Shu W, Hu Y, Zhu H, Li Y. Neurosurgical choice for glossopharyngeal neuralgia: A benefit-harm assessment of long-term quality of life. *Neurosurgery* 2020;88:131-9.
- Elias J, Kuniyoshi R, Carloni WV, Borges MR, Peixoto CA, Pimentel D. Glossopharyngeal neuralgia associated with cardiac syncope. *Arq Bras Cardiol* 2002;78:510-9.
- Fraioli B, Esposito V, Ferrante L, Trubiani L, Lunardi P. Microsurgical treatment of glossopharyngeal neuralgia: Case reports. *Neurosurgery* 1989;25:630-2.
- Franzini A, Messina G, Franzini A, Marchetti M, Ferroli P, Fariselli L, *et al.* Treatments of glossopharyngeal neuralgia: Towards standard procedures. *Neurol Sci* 2017;38 Suppl 1:51-5.
- Headache Classification Committee of the International Headache Society (IHS) The international classification of headache disorders. 3<sup>rd</sup> edition. *Cephalalgia* 2018;38:1-211.
- Inoue K, Matsushima T, Ohara S, Masuoka J, Abe T. Study of the anatomical features of the offending arteries involved in

- glossopharyngeal neuralgia. *Oper Neurosurg* (Hagerstown) 2020;19:E259-68.
11. Iwai Y, Ishibashi K, Yamanaka K. Gamma knife radiosurgery for concurrent trigeminal neuralgia and glossopharyngeal neuralgia. *Cureus* 2021;13:e20717.
  12. Kim MK, Park JS, Ahn YH. Microvascular decompression for glossopharyngeal neuralgia: Clinical analyses of 30 cases. *J Korean Neurosurg Soc* 2017;60:738-48.
  13. Krasoudakis A, Anyfantakis D, Hadjipetrou A, Kastanakis M, Symvoulakis EK, Marathianos S. Glossopharyngeal neuralgia associated with cardiac syncope: Two case reports and literature review. *Int J Surg Case Rep* 2015;12:4-6.
  14. Ma Y, Li YF, Wang QC, Wang B, Huang HT. Neurosurgical treatment of glossopharyngeal neuralgia: Analysis of 103 cases. *J Neurosurg* 2016;124:1088-92.
  15. Palanisamy D, Kyosuke M, Yasuhiro Y, Tsukasa K, Kato Y. Management of recurrent glossopharyngeal neuralgia following microvascular decompression surgery. *World Neurosurg* 2018;117:339-43.
  16. Pommier B, Touzet G, Lucas C, Vermandel M, Blond S, Reyns N. Glossopharyngeal neuralgia treated by Gamma Knife radiosurgery: Safety and efficacy through long-term follow-up. *J Neurosurg* 2017;128:1372-9.
  17. Revuelta-Gutiérrez R, Morales-Martínez AH, Mejías-Soto C, Martínez-Anda JJ, Ortega-Porcayo LA. Microvascular decompression for glossopharyngeal neuralgia through a microarterial approach: A case series. *Surg Neurol Int* 2016;7:51.
  18. Rey-Dios R, Cohen-Gadol AA. Current neurosurgical management of glossopharyngeal neuralgia and technical nuances for microvascular decompression surgery. *Neurosurg Focus* 2013;34:E8.
  19. Riley HA, Greenan WJ, Wortis H. Glossopharyngeal neuralgia initiating or associated with cardiac arrest. *Trans Am Neurol Assoc* 1942;68:28-9.
  20. Rozen TD. Trigeminal neuralgia and glossopharyngeal neuralgia. *Neurol Clin* 2004;22:185-206.
  21. Rui Y, Ji W, Chuncheng Q, Shengcheng W. Efficacy comparison of microvascular decompression and rhizotomy in the treatment of glossopharyngeal neuralgia: A retrospective analysis of 37 cases. *Turk Neurosurg* 2019;29:493-6.
  22. Rushton JG, Stevens JC, Miller RH. Glossopharyngeal (vagoglossopharyngeal) neuralgia: A study of 217 cases. *Arch Neurol* 1981;38:201-5.
  23. Shimizu K, Matsumoto M, Wada A, Sugiyama T, Tanioka D, Okumura H, *et al.* Supine no-retractor method in microvascular decompression for hemifacial spasm: Results of 100 consecutive operations. *J Neurol Surg B Skull Base* 2015;76:202-7.
  24. Taşci İ, Beydilli İ, Demir CF, Balgetir F, Gönen M, Bakir M. A case of syncopal convulsions triggered by glossopharyngeal neuralgia. *Agri* 2021;33:197-9.
  25. Thomson JL. Glossopharyngeal neuralgia accompanied by unconsciousness. *J Neurosurg* 1954;11:511-4.
  26. Van Hecke O, Austin SK, Khan RA, Smith BH, Torrance N. Neuropathic pain in the general population: A systematic review of epidemiological studies. *Pain* 2014;155:654-62.
  27. Wilhour D, Nahas SJ. The neuralgias. *Curr Neurol Neurosci Rep* 2018;18:69.
  28. Zhao H, Zhang X, Zhu J, Tang YD, Li ST. Microvascular decompression for glossopharyngeal neuralgia: Long-term follow-up. *World Neurosurg* 2017;102:151-6.
  29. Zheng X, Wei XY, Zhu J, Yuan Y, Ying TT, Li ST. Microvascular decompression alone without rhizotomy is an effective way of treating glossopharyngeal neuralgia: Clinical analysis of 46 cases. *Stereotact Funct Neurosurg* 2020;98:129-35.

**How to cite this article:** Revuelta-Gutiérrez R, Piñon-Jiménez F, Contreras-Vázquez O, Vales-Hidalgo LO, Martínez-Anda J. Glossopharyngeal and vagoglossopharyngeal neuralgia: Long-term surgical outcomes in a single institution. *Surg Neurol Int* 2023;14:267.

## Disclaimer

The views and opinions expressed in this article are those of the authors and do not necessarily reflect the official policy or position of the Journal or its management. The information contained in this article should not be considered to be medical advice; patients should consult their own physicians for advice as to their specific medical needs.