



Video Abstract

Surgical technique: Posterior retropleural thoracotomy for resection of a T10 dumbbell schwannoma

Disep I. Ojukwu¹, Brandon M. Wilkinson², Timothy Dawson, II¹, Michael A. Galgano^{2,3}

¹St. George's University, School of Medicine, Great River, ²Department of Neurosurgery, SUNY Upstate Medical University, Syracuse, ³Department of Neurosurgery, University of North Carolina, Chapel Hill, New York, United States.

E-mail: *Disep I. Ojukwu - disep.ojukwu@gmail.com; Brandon M. Wilkinson - wilkinsb@upstate.edu; Timothy Dawson, II - tcdawsonii@gmail.com; Michael A. Galgano - michael_galgano@med.unc.edu



*Corresponding author:

Disep I. Ojukwu,
St. George's University, School
of Medicine, Great River,
New York, United States.

disep.ojukwu@gmail.com

Received: 16 November 2023

Accepted: 13 December 2023

Published: 19 January 2024

DOI

10.25259/SNI_921_2023

Videos available on:

https://doi.org/10.25259/SNI_921_2023

Quick Response Code:



ABSTRACT

Background: Myelopathy and nerve root dysfunction resulting from the imperceptible growth of intraspinal schwannomas have been well documented.^[1] Thoracic spine schwannomas, in particular, have exceptional growth potential due to the presence of the posterior mediastinum and retropleural spaces accommodating insidious and often subclinical tumor expansion.^[5] Extraplural extension of these lesions, however, poses a distinct challenge for surgeons.^[3,4]

Case Description: Here, we provide a two-dimensional intraoperative video demonstrating the technical nuances concerning maximally safe resection of a partially cystic thoracic dumbbell schwannoma having extraspinal extension with associated bony remodeling of the T10 vertebral body and neural foramen in a middle-aged male. A posterolateral approach with T8–T12 fusion, retropleural thoracotomy, facetectomies, and pediclectomies allowed for gross total resection. No intraoperative or postoperative complications were observed, and the parietal pleura was kept intact throughout the surgery. In addition, the patient continued to have improved symptoms and was ambulatory at 6-month follow-up.

Conclusion: Gross total resection of a partially cystic thoracic dumbbell schwannoma was achieved without complications. Our use of a preoperative three-dimensional reconstruction for surgical planning,^[2] intraoperative ultrasound,^[6] and a durable instrumentation construct were essential for a successful outcome. Moreover, great care was taken to avoid violating the tumor-parietal pleura plane, which would have resulted in postoperative respiratory complications.

Keywords: Intradural tumors, Intraoperative surgical video, Spine neurosurgery, Thoracic dumbbell schwannomas, Vertebral column schwannomas

[Video 1]-Available on:

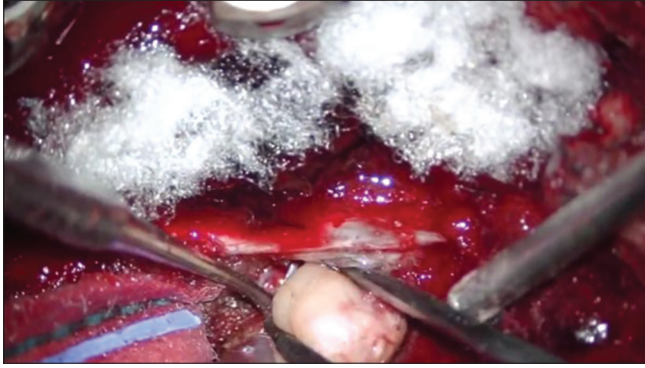
www.surgicalneurologyint.com

Annotations^[1-6]

- 1) 00:00 – Clinical presentation.
- 2) 00:19 – Pre-operative imaging.
- 3) 00:43 – Key surgical steps.
- 4) 00:48 – Surgical details.
- 5) 04:28 – Post-operative imaging.
- 6) 04:35 – Post-operative course.

This is an open-access article distributed under the terms of the Creative Commons Attribution-Non Commercial-Share Alike 4.0 License, which allows others to remix, transform, and build upon the work non-commercially, as long as the author is credited and the new creations are licensed under the identical terms.

©2024 Published by Scientific Scholar on behalf of Surgical Neurology International



Video 1: Two-dimensional video of the posterior retropleural thoracotomy surgical technique used for the resection of a T10 dumbbell schwannoma.

Ethical approval

Institutional Review Board approval is not required.

Declaration of patient consent

Patient's consent not required as patient's identity is not disclosed or compromised.

Financial support and sponsorship

Nil.

Conflicts of interest

There are no conflicts of interest.

Use of artificial intelligence (AI)-assisted technology for manuscript preparation

The authors confirm that there was no use of artificial intelligence (AI)-assisted technology for assisting in the writing or editing of the manuscript and no images were manipulated using AI.

REFERENCES

1. Deng Q, Tian Z, Sheng W, Guo H, Dan ME. Surgical methods and efficacies for cervicothoracolumbar spinal schwannoma. *Exp Ther Med* 2015;10:2023-8.
2. Leary OP, Crozier J, Liu DD, Niu T, Pertsch NJ, Camara-Quintana JQ, *et al.* Three-dimensional printed anatomic modeling for surgical planning and real-time operative guidance in complex primary spinal column tumors: Single-center experience and case series. *World Neurosurg* 2021;145:e116-26.
3. Nanda A, Kukreja S, Ambekar S, Bollam P, Sin AH. Surgical strategies in the management of spinal nerve sheath tumors. *World Neurosurg* 2015;83:886-99.
4. Ottenhausen M, Ntoulas G, Bodhinayake I, Ruppert FH, Schreiber S, Förschler A, *et al.* Intradural spinal tumors in adults - update on management and outcome. *Neurosurg Rev* 2019;42:371-88.
5. Song YJ, Seol SH, Kim S, Kim DK, Kim KH, Kim DI, *et al.* Benign posterior mediastinal schwannoma-Multiple diagnostic imaging modalities. *Clin Case Rep* 2019;7:2585-7.
6. Strong MJ, Yee TJ, Khalsa SS, Saadeh YS, Muhlestein WE, North RY, *et al.* Resection of a lumbar intradural extramedullary schwannoma: 2-dimensional operative video. *Oper Neurosurg (Hagerstown)* 2021;21:E38.

How to cite this article: Ojukwu DI, Wilkinson BM, Dawson T, II, Galgano MA. Surgical technique: Posterior retropleural thoracotomy for resection of a T10 dumbbell schwannoma. *Surg Neurol Int.* 2024;15:15. doi: 10.25259/SNI_921_2023

Disclaimer

The views and opinions expressed in this article are those of the authors and do not necessarily reflect the official policy or position of the Journal or its management. The information contained in this article should not be considered to be medical advice; patients should consult their own physicians for advice as to their specific medical needs.