



Case Report

Timing of surgical intervention in peripheral nerve injuries from gunshot wounds: Management and review of the literature

Joseph Yunga Tigre, Aiko Puerto¹, Adham M. Khalafallah¹, S. Shelby Burks

Department of Neurological Surgery, University of Miami Miller School of Medicine, Miami, United States.

E-mail: *Joseph Yunga Tigre - jay693@med.miami.edu; Aiko Puerto - aikopuerto@gmail.com; Adham M. Khalafallah - adham.khalafallah@jhsmiami.org; S. Shelby Burks - sburks@med.miami.edu



*Corresponding author:

Joseph Yunga Tigre,
Department of Neurological
Surgery, University of Miami
Miller School of Medicine,
Miami, United States.

jay693@med.miami.edu

Received: 18 March 2024

Accepted: 01 May 2024

Published: 31 May 2024

DOI

10.25259/SNI_197_2024

Quick Response Code:



ABSTRACT

Background: Gunshot wounds (GSWs) can result in various peripheral nerve injuries (PNIs), ranging from direct nerve transection to neuropraxia caused by the ballistic shockwave mechanism. PNIs from GSWs can be treated with either early or delayed intervention, with the literature supporting both approaches and sparking a debate between early and delayed intervention for PNIs from GSWs. Here, we present a case that underwent delayed exploration of the right common peroneal nerve after GSW and a literature review comparing early versus delayed intervention for PNIs from GSWs.

Case Description: A 29-year-old male underwent right common peroneal nerve exploration 2 months after he sustained a GSW to the right lower extremity at the level of the fibular head tracking to the lateral malleolus. Initially, after the injury, he was offered supportive care. On evaluation, 1 month later, he reported a right-sided foot drop and paresthesias in the right lower extremity. A partial-thickness injury of the right peroneal nerve was seen on ultrasound, and a bullet fragment in the distal right lower extremity was revealed on computed tomography. The surgical intervention consisted of the right common peroneal nerve decompression proximally to distally and removal of the bullet fragment. Postoperatively, the patient did well with improvements in his right ankle dorsiflexion and plantar flexion seen at his 1.5-month follow-up visit.

Conclusion: Many factors must be considered when treating PNIs from GSWs. For each case, clinical judgment, injury mechanism, and risk-benefit analysis must be evaluated to determine each patient's optimal treatment strategy.

Keywords: Delayed intervention, Early intervention, Gunshot wound, Peripheral nerve injury

INTRODUCTION

Each year, many Americans are injured in accidents involving firearms.^[3] These accidents range from self-inflicted injuries, interpersonal violence, legal interventions, and unintentional injuries to injuries where intent cannot be determined.^[3] Non-fatal gunshot wounds (GSWs) are 5 times more likely to occur than fatal GSWs.^[7] Not only can GSWs cause direct trauma, but they also, due to the injury mechanism, cause indirect trauma from the ballistic shockwave and cavitation.^[2] Often, soft-tissue compression, stretching, and shearing occur,^[2] as well as a range

This is an open-access article distributed under the terms of the Creative Commons Attribution-Non Commercial-Share Alike 4.0 License, which allows others to remix, transform, and build upon the work non-commercially, as long as the author is credited and the new creations are licensed under the identical terms.

©2024 Published by Scientific Scholar on behalf of Surgical Neurology International

of nerve injuries from direct nerve laceration to temporary neuropraxia with spontaneous full recovery.^[5] Severe motor dysfunction and neuropathic pain can result from injuries to the peripheral nerves.^[8]

There is still debate about the optimal treatment timing following peripheral nerve injuries (PNIs) from GSWs. Early intervention may prevent dense scar tissue formation and intraneural edema, leading to improved outcomes.^[4] Furthermore, if grafts are needed, shorter grafts can be used in the early intervention as nerve retraction by local structures is reduced in early intervention.^[4] In contrast, delayed intervention allows the zone of injury to be fully demarcated, optimizing treatment planning.^[4] Ultimately, several factors, including injury mechanism and patient characteristics, must be evaluated in determining the patient's treatment plan.^[4] We present the case of a 29-year-old male undergoing delayed intervention for PNI following a GSW and a review of the literature focusing on the timing of intervention following a GSW.

CASE PRESENTATION

A 29-year-old male presented for evaluation of a GSW to his right lower extremity that he had sustained 1 month prior. The patient was at work, and while taking off his vest, his service weapon discharged spontaneously into his right lower extremity at the level of the fibular head, tracking to the lateral malleolus. He was immediately evaluated at an outside emergency department, and X-rays showed no bony injuries. Surgical intervention was not recommended at the time, and he was given supportive care. He reported sensitivity and an intermittent burning sensation located at his right lateral calf, rated a 2/10. He also endorsed paresthesias in his right ankle and first three toes, as well as a right-sided drop.

On physical examination, no gait abnormalities were seen. However, his right ankle plantar flexors were a 3/5 and long toe extensors were a 2/5. Sensation was diminished in the right leg in the common peroneal nerve distribution. Reflex examination was normal and dorsalis pedis pulses were 2+/4 bilaterally. 1+ edema of the right ankle was seen, and he had a good capillary refill of his right toes. Computed tomography performed at our institution demonstrated a bullet fragment in the distal right lower extremity [Figure 1], and ultrasound revealed partial thickness injuries in the right common peroneal nerve, just distal to the level of the fibular head [Figure 2], and deep peroneal nerve. Exploration of the right common, deep, and superficial peroneal nerve was recommended, as well as bullet fragment removal.

Intervention (2 months after GSW)

After proper patient positioning and preoperative protocols, an incision was made at the right fibular head following

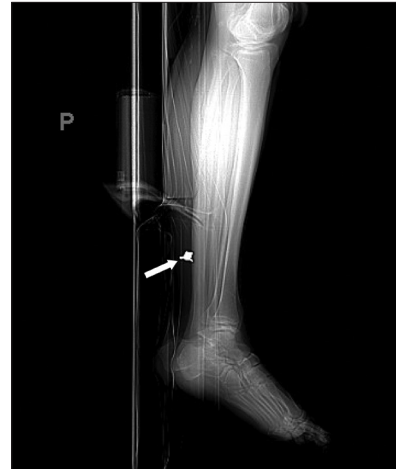

Figure 1: Computed tomography of the right lower extremity. The white arrow demonstrates the bullet fragment in the right distal lower extremity.

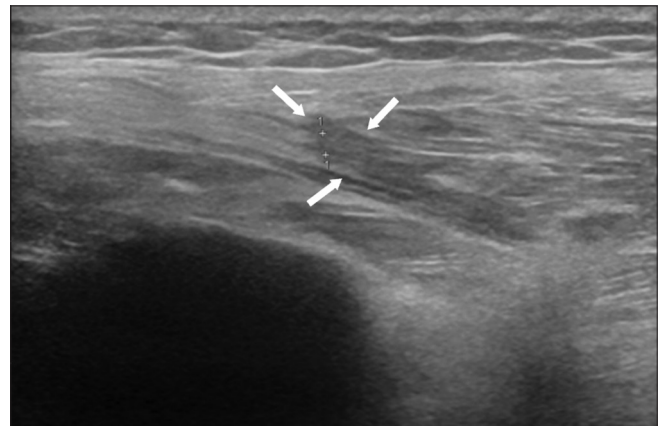


Figure 2: Ultrasound of the right peroneal nerve. The white arrows demonstrate the partial thickness injury of the peroneal nerve at the fibular head.

the trajectory of the common peroneal nerve. The fascia was further dissected and the common peroneal nerve was identified proximally to the popliteal fossa. No abnormalities were seen at this segment of the nerve, and dissection continued distally until dense scar tissue was encountered at the fibular tunnel. The common peroneal nerve was then decompressed distally, and the deep and superficial branches of the peroneal nerve were identified. Circumferential dissection of the nerves occurred, and dense scar tissue was seen at the point of bifurcation. The operating microscope was then used for further dissection, taking great care not to disrupt intact nerve fascicles. Neurolysis [Figure 3] continued with the assistance of the microscope, and the wound was irrigated and closed in a layered fashion. Throughout the case, a monopolar stimulator was frequently used to confirm stimulation of both the right lower extremity lateral and anterior muscular compartments.

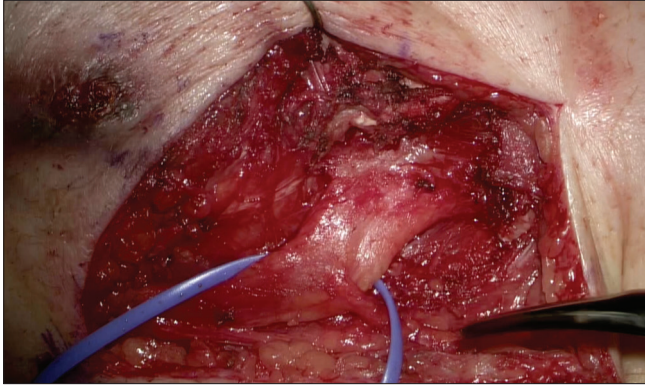


Figure 3: Right common peroneal nerve after decompression with the operating microscope.

A separate incision was made in the distal right leg near the lateral malleolus. After dissection of the fascia and musculature of the lateral compartment of the leg, the bullet fragment was identified. The bullet fragment was removed in one piece [Figure 4], and an intraoperative X-ray confirmed that no other large bullet fragments were remaining. The wound was then irrigated and closed in a layered fashion. The patient awoke at his neurologic baseline and was taken to the post-anesthesia care unit. He ambulated shortly after with assistance and was discharged home the same day. At his follow-up visit 3 weeks later, the patient was doing well, with no difficulty walking. There was minimal pain and tenderness at this incision site, and he was referred to physical therapy for right leg strengthening. At his 1.5-month follow-up visit, he continued to do well, demonstrating right ankle dorsiflexion and plantar flexion with minimal discomfort. The motor examination of his right tibialis anterior and extensor hallucis longus was 4/5.

DISCUSSION

GSWs range in degree of severity. On immediate evaluation, if a nerve gap defect is identified, then early surgical repair is indicated.^[10] However, often, GSWs cause a partial nerve injury or an injury that is not directly caused by the bullet striking the nerve.^[9] The nerve damage occurs through the ballistic shockwave mechanism, contusive forces, and ischemia in the area.^[9]

There is still a large debate in determining the optimal treatment plan for PNIs from GSWs in these cases.

The timing of nerve repair must be considered to optimize patient outcomes.^[4] Immediate intervention can improve patient recovery by preventing the collapse of endoneurial tubes needed for nerve regeneration, as well as decreasing the level of muscular denervation.^[9]

Furthermore, appropriate timing of intervention is needed, as untreated injured nerves can regenerate in a disorganized

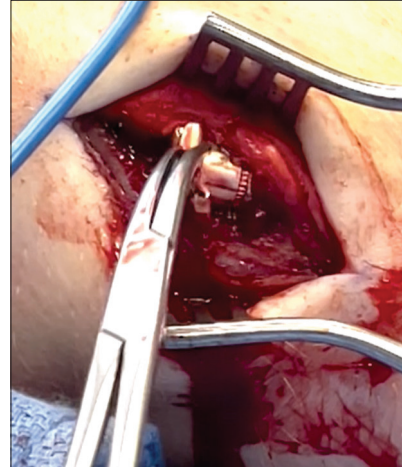


Figure 4: Removal of the bullet fragment in the distal right leg near the lateral malleolus.

process, resulting in neuroma formation.^[4] In a 68-case retrospective study by Alimehmeti *et al.* on the surgical repair of GSW PNIs ranging from interfascicular neurolysis to direct end-to-end microsuture, they determined that early surgical repair of GSW PNIs resulted in improved pain relief and sensory motor improvements.^[1] Another study by Pannell *et al.* focused on patients with clinical palsy after GSW to the upper extremity and found that due to the high incidence of traumatic nerve laceration, which requires surgical repair after a GSW, it is best to perform early nerve exploration in these patients.^[6] In addition, the risk of patients progressing to narcotic dependence for pain management may be reduced through timely intervention.^[4]

Following traumatic nerve injuries, significant soft-tissue trauma and local inflammation can prevent accurate assessment of the nerve injury^[9], and as such, delayed intervention may be the preferred option. In addition, if the nerve cannot be determined to be intact at immediate evaluation or if surgical intervention may not improve patient outcomes, the then delayed assessment may be favored.^[9] The natural regenerative process can also successfully repair an injured portion of a nerve in less severe injuries with full functional recovery, favoring delayed intervention.^[4] In Wang *et al.*'s single-center study on the optimal timing for repair of PNIs, they determined that nerve repair outcomes were similar when performed acutely after the injury or in a delayed fashion. Patients who underwent early repair of their PNIs had 54.7% clinically significant improvements in motor outcomes, which was similar to the 53% of patients who had clinically significant improvements in motor outcomes with delayed repair.^[11]

In our case, the patient did not undergo surgical intervention after an immediate evaluation. Given that his symptoms may

have spontaneously improved, he was offered supportive care. However, over the next 2 months, his neurological symptoms continued to worsen, and he underwent surgical intervention. From his follow-up visits, he was doing well and showing improvement in the right ankle dorsiflexion and plantar flexion. Ultimately, he improved with surgical intervention, which questions when the optimal timing of intervention for PNIs from GSWs should occur.

CONCLUSION

This case highlights the ongoing debate between early versus delayed intervention for PNIs. Many factors must be considered when treating PNIs from GSWs. For each case, clinical judgment, injury mechanism, and risk-benefit analysis must be evaluated to determining each patient's optimal treatment strategy.

Ethical approval

The Institutional Review Board approval is not required.

Declaration of patient consent

The authors certify that they have obtained all appropriate patient consent.

Financial support and sponsorship

Nil.

Conflicts of interest

There are no conflicts of interest.

Use of artificial intelligence (AI)-assisted technology for manuscript preparation

The authors confirm that there was no use of artificial intelligence (AI)-assisted technology for assisting in the writing or editing of the manuscript and no images were manipulated using AI.

REFERENCES

1. Alimehmeti R, Brace G, Pajaj E, Cecia A, Kalefi T, Kerxhaliu J, *et al.* Retrospective study of surgical repair of gunshot injuries of peripheral nerves. *Albanian J Trauma Emerg Surg* 2019;3:387-94.
2. Baker HP, Straszewski AJ, Dahm JS, Dickherber JL, Krishnan P, Dillman DB, *et al.* Gunshot-related lower extremity nerve injuries. *Eur J Orthop Surg Traumatol* 2023;33:851-6.
3. Fowler KA, Dahlberg LL, Haileyesus T, Annest JL. Firearm injuries in the United States. *Prev Med* 2015;79:5-14.
4. MacKay BJ, Cox CT, Valerio IL, Greenberg JA, Buncke GM, Evans PJ, *et al.* Evidence-based approach to timing of nerve surgery: A review. *Ann Plast Surg* 2021;87:e1-21.
5. Moore AM, Wagner IJ, Fox IK. Principles of nerve repair in complex wounds of the upper extremity. *Semin Plast Surg* 2015;29:40-7.
6. Pannell WC, Heckmann N, Alluri RK, Sivasundaram L, Stevanovic M, Ghiassi A. Predictors of nerve injury after gunshot wounds to the upper extremity. *Hand (N Y)* 2017;12:501-6.
7. Parker ST. Estimating nonfatal gunshot injury locations with natural language processing and machine learning models. *JAMA Netw Open* 2020;3:e2020664.
8. Rochkind S, Strauss I, Shlitner Z, Alon M, Reider E, Graif M. Clinical aspects of ballistic peripheral nerve injury: Shrapnel versus gunshot. *Acta Neurochir (Wien)* 2014;156:1567-75.
9. Rodríguez Aceves CA, Addas BM, Ali Z, Antoniadis G, Neiva Barbosa DA, Binaghi D, *et al.* 10 timing in traumatic peripheral nerve lesions. In: *Manual of peripheral nerve surgery*. Stuttgart: Georg Thieme Verlag KG; 2018.
10. Rodríguez Aceves CA, Addas BM, Ali Z, Antoniadis G, Neiva Barbosa DA, Binaghi D, *et al.* 12 Gunshot and other missile wounds to the peripheral nerves. In: *Manual of peripheral nerve surgery*. Stuttgart: Georg Thieme Verlag KG; 2018.
11. Wang E, Inaba K, Byerly S, Escamilla D, Cho J, Carey J, *et al.* Optimal timing for repair of peripheral nerve injuries. *J Trauma Acute Care Surg* 2017;83:875-81.

How to cite this article: Yunga Tigre J, Puerto A, Khalafallah AM, Burks SS. Timing of surgical intervention in peripheral nerve injuries from gunshot wounds: Management and review of the literature. *Surg Neurol Int.* 2024;15:178. doi: 10.25259/SNI_197_2024

Disclaimer

The views and opinions expressed in this article are those of the authors and do not necessarily reflect the official policy or position of the Journal or its management. The information contained in this article should not be considered to be medical advice; patients should consult their own physicians for advice as to their specific medical needs.