



Original Article

Femoral to sciatic nerve transfer: A cadaver study

Melissa Trudrung¹, Ethan Mickelson¹, Pradeep Attaluri², Robert Edward George², Brian Gander², Amgad Hanna^{1,3}

¹Department of Neurological Surgery, University of Wisconsin-Madison School of Medicine and Public Health, ²Division of Plastic Surgery, Department of General Surgery, University of Wisconsin-Madison School of Medicine and Public Health, Madison, ³Department of Biomedical Engineering, University of Wisconsin-Madison, Wisconsin, United States.

E-mail: Melissa Trudrung - trudrung@wisc.edu; Ethan Mickelson - emickelson@mcw.edu; Pradeep Attaluri - pattaluri@wisc.edu; Robert Edward George - rgeorge@uwhealth.org; Brian Gander - gander@surgery.wisc.edu; *Amgad Hanna - ah2904@yahoo.com



***Corresponding author:**

Amgad Hanna,
Department of Neurological
Surgery, University of
Wisconsin-Madison School of
Medicine and Public Health,
Madison, United States.

ah2904@yahoo.com

Received: 19 January 2025

Accepted: 01 February 2025

Published: 28 February 2025

DOI

10.25259/SNI_60_2025

Video available on:

https://doi.org/10.25259/SNI_60_2025

Quick Response Code:



ABSTRACT

Background: Proximal sciatic nerve injuries are a challenge to treat due to the limited options for donor nerves and the long distance needed for regeneration.

Methods: In our cadaveric study using five human cadavers, we aimed to evaluate the feasibility of transferring the tibial and common peroneal components of the sciatic nerve to the femoral nerve motor branches of the vastus medialis (VM) and vastus lateralis without the need for interposition nerve graft. The femoral nerve branches of the VM and lateralis were exposed anteriorly. The sciatic nerve was exposed posteriorly and passed through a narrow window within the adductor magnus and medial to the femur. The sciatic nerve was then separated into its tibial and peroneal components, which were then coapted to the VM and lateralis motor branches of the femoral nerve.

Results: Using the entire tibial and peroneal components of the sciatic nerve, we were able to gain more length and directly coapt the femoral nerve branches without utilizing interposition grafts. The disadvantage of this technique is suturing to a mixed nerve with motor and sensory components, which could compromise functional outcomes. Further studies are needed to determine how the procedure will impact a patient's gait cycle.

Conclusion: Clinical application is needed to determine preliminary outcomes before widespread utilization of this technique.

Keywords: Femoral nerve, Nerve injury, Nerve repair, Nerve transfer, Nerve trauma, Sciatic nerve

INTRODUCTION

Sciatic nerve injuries impose significant disabilities, especially in cases with more proximal injury sites. Impairments may include lower leg atrophy, foot drop, loss of plantar sensation, and absent plantar and dorsiflexion.^[3,9] At present, direct tensionless end-to-end nerve repair is widely considered to be the best treatment.^[7,10] In nerve injuries where direct repair is impractical, autologous nerve grafts are the preferred alternative.^[7] However, the sciatic nerve presents several anatomical challenges, such as large cross-sectional area and overall length. These difficulties make proximal injury sites difficult for nerve repair and limit surgical options to restore sensory and motor function.^[3,9]

To help overcome these anatomical barriers, nerve transfers have been explored as a treatment option. Previous literature has described several nerve transfers to treat sciatic nerve injuries. These include transfers from the tibial motor branches to the deep peroneal nerve,^[6] the

This is an open-access article distributed under the terms of the Creative Commons Attribution-Non Commercial-Share Alike 4.0 License, which allows others to remix, transform, and build upon the work non-commercially, as long as the author is credited and the new creations are licensed under the identical terms.

©2025 Published by Scientific Scholar on behalf of Surgical Neurology International

femoral motor branches to the tibial motor branches and gastrocnemius muscle, the saphenous nerve to the sural nerve or the peroneal to tibial for sensory reconstruction,^[16] and transferring the obturator nerve to the gastrocnemius nerve with autologous grafting.^[26] To treat high-level sciatic nerve lesions, femoral motor branches were transferred to tibial and deep peroneal branches in a cadaver study.^[15] Another study demonstrated a sciatic to femoral nerve transfer to treat a high femoral nerve injury.^[4] They transferred the proximal motor branches of the sciatic nerve to the rectus femoris and vastus lateralis (VL) branches of the femoral nerve, which required a sural nerve graft. The patient regained his ability to extend his knee after the nerve transfer.^[4]

Specifically, femoral to tibial and common peroneal nerve transfers have gained popularity due to the femoral terminal motor branch candidates – the rectus femoris, vastus medialis (VM), vastus intermedius, VL, and sartorius. When one branch is chosen as the donor, the other branches can provide residue extension of the knee joint without significantly affecting quadriceps function.^[16] However, this technique incorporates both direct nerve transfers and interposition nerve grafts. As a result, the regenerating nerve must traverse an extensive distance due to more coaptations, which may limit functional recovery.^[21,22]

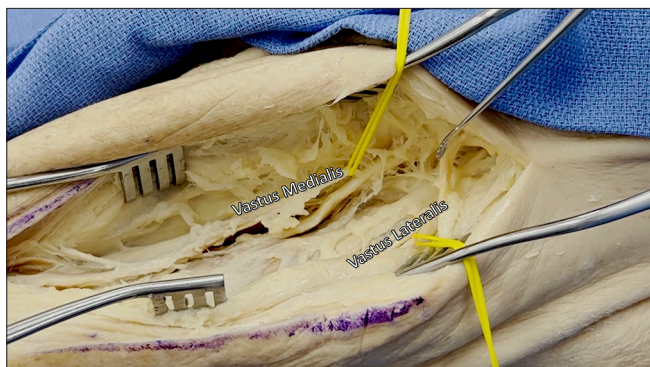


Figure 1: An anterior midline incision is made in the thigh to expose the quadriceps femoris. The vastus medialis and lateralis branches of the femoral nerve were identified and tagged in yellow vessel loops as they entered their corresponding muscles.

Inspired by these studies, we propose a novel reconstructive method for proximal sciatic nerve injury by directly transferring the femoral nerve motor branches to the tibial and common peroneal nerves. In this study, we will explore the anatomical feasibility of this method using both lower extremities of five human cadavers. Ideally, this method will eliminate the need for interposition nerve grafts, reduce the number of coaptations, shorten the distance needed for the regenerating nerves, and improve functional outcomes.

MATERIALS AND METHODS

Five human cadavers, four males and one female, and their lower extremities were used to test the following procedure. The subjects had no impairments that would affect surgical results.

An anterior thigh incision was initially made to expose the quadriceps femoris. The VM branch of the femoral nerve was found superficial and medial to the VM muscle. The VL branch was identified anterolateral to the corresponding muscle. The VL and VM were tagged in yellow vessel loops [Figure 1]. A posterior midline incision was then made in the thigh to expose the sciatic nerve tagged in blue loops [Figure 2a]. The sciatic nerve was transected at the most proximal point while preserving as many hamstring branches as possible. A window was created in the adductor magnus muscle so the sciatic nerve could be transferred from posterior to anterior [Figures 2b-d]. Once the distal nerve stump was transferred, we separated the sciatic nerve into the tibial (TN) and peroneal (PN) components. These were coapted to the VM and VL donor nerves [Figure 3, Video 1]. These were secured using 9-0 nonabsorbable sutures. If the transfer succeeded with tensionless coaptation, the method was deemed anatomically feasible and successful.

RESULTS

In total, 7 of the 10 lower extremities displayed successful coaptation following the nerve transfer [Table 1]. A transfer was deemed successful if the overlap value was >0 cm to ensure tensionless coaptation. Cadavers 2–5 received

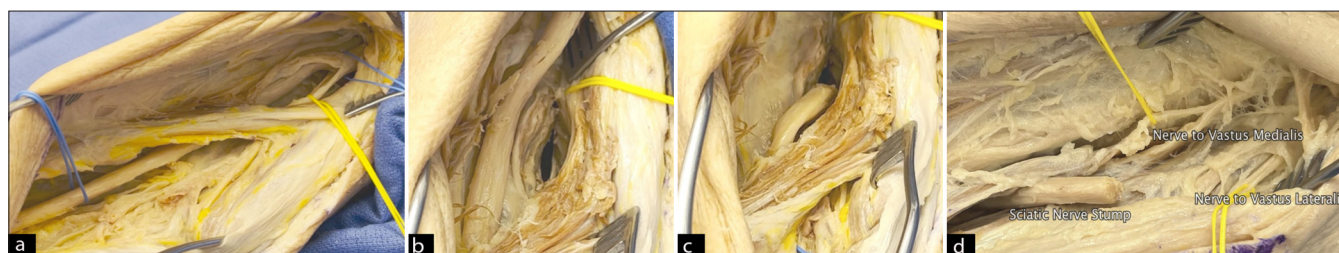

Figure 2: (a) Posterior midline incision is performed in the thigh to expose the sciatic nerve, tagged in blue loops, and the hamstring branches, tagged in yellow. (b) The muscular window was created through the adductor magnus. (c) The sciatic nerve was then disconnected and transferred through the adductor magnus window toward the anterior compartment of the thigh. (d) Anterior view of the lower extremity. The sciatic nerve is near the labeled vastus medialis and vastus lateralis nerves tagged in yellow.

transections immediately below or at the gluteal fold. Transecting at the gluteal fold produced an average PN to VL overlap value of 8.6 cm ± 1.2 cm and an average TN to VM overlap value of 3.9 cm ± 1.4 cm (mean ± standard error) to ensure tensionless coaptation.

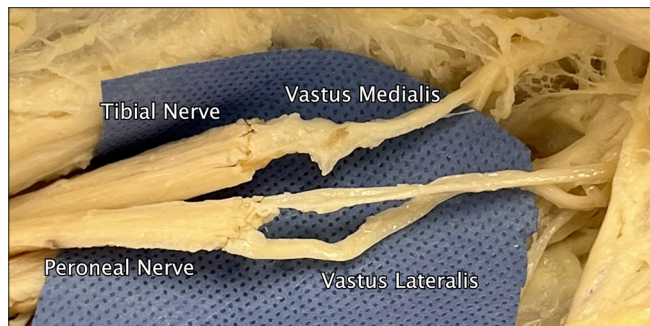
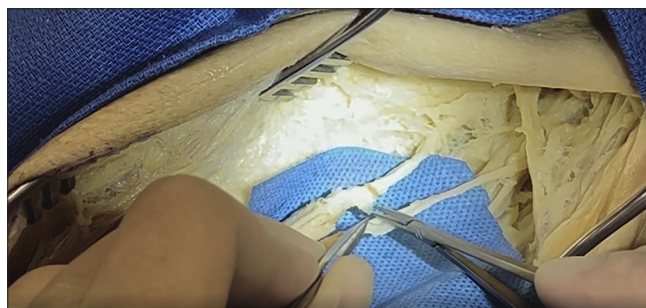

Figure 3: After passing through the adductor magnus, medial to the femur, from posterior to anterior, the sciatic nerve was separated into its peroneal and tibial components. The peroneal component (PN) aligned better with the vastus lateralis branch, and the tibial component (TN) aligned better with the vastus medialis branch. These were put together using 9-0 nonabsorbable sutures.

The three sciatic nerves that did not achieve successful coaptations were transected too distally. Specifically, the sciatic nerves in the first cadaver were transected at the mid-thigh level and failed to reach the VM and VL branches without an interposition graft. Transecting at the gluteal fold, a more proximal site, provided the necessary length. The transfer in cadaver 4's right extremity resulted in an above-average PN to VL overlap with 9 cm but did not provide any overlap in the TN to VM coaptation.



Video 1: Cadaveric nerve transfer demonstrating microsuturing of the tibial nerve to the vastus medialis nerve.

Table 1: Summary of the nerve transfer results. For each cadaver, the donor nerve, recipient nerve, and overlap values are listed for both extremities. The procedure was considered viable if the overlap value was >0 cm to ensure tensionless coaptation.

Subject number and Side	Sex	Donor's nerve	Recipient's nerve	Overlap (cm)
Cadaver 1	M			
Left		1. Vastus medialis 2. Vastus lateralis	Sciatic	None
Right		1. Vastus medialis 2. Vastus lateralis	Sciatic	None
Cadaver 2	M			
Left		1. Vastus medialis 2. Vastus lateralis	Sciatic	1. 11 cm 2. 12 cm
Right		1. Vastus medialis 2. Vastus lateralis	Sciatic	1. 6 cm 2. 6 cm
Cadaver 3	M			
Left		1. Vastus medialis 2. Vastus lateralis	Sciatic	1. 13 cm 2. 5 cm
Right		1. Vastus medialis 2. Vastus lateralis	Sciatic	1. 10 cm 2. 8 cm
Cadaver 4	M			
Left		1. Vastus medialis 2. Vastus lateralis	Sciatic	1. 8 cm 2. 2 cm
Right		1. Vastus medialis 2. Vastus lateralis	Sciatic	1. 9 cm 2. 0 cm
Cadaver 5	F			
Left		1. Vastus medialis 2. Vastus lateralis	Sciatic	1. 4 cm 2. 1 cm
Right		1. Vastus medialis 2. Vastus lateralis	Sciatic	1. 3.5 cm 2. 1.5 cm

DISCUSSION

It is estimated that 13.3 million Americans annually suffer from lower extremity nerve injuries. These injuries can impose substantial economic hardships on patients, with an estimated average annual care cost of \$64,000 per patient.^[5] Due to the significant financial impacts and symptoms that can reduce the patient's quality of life, treatment methods must produce the best functional outcomes. In sciatic nerve injuries, the nerve's increased size, diameter, and length compared to other nerves remain problematic for grafts. In particular, grafts >6 cm in length have been shown to have poorer rates of success.^[25] However, creative surgical methods involving tendon, muscle, or nerve transfers alongside nerve grafting have the potential to overcome this barrier and provide optimal functional outcomes.^[13,20] In particular, nerve transfers are advantageous for more proximal injuries by avoiding the injury site and shortening the distance to reinnervate the muscle.^[8] Motor nerve regeneration is time-dependent and must occur before the critical period elapses for synapse reformation. Therefore, nerve transfers can hasten the time required for the regeneration of the muscle and improve functional outcomes.^[19]

Compared to previously reported methods, our procedure has some advantages. First, our method effectively eliminates the need for interposition grafts. Meng *et al.* introduced a method for treating high-level sciatic nerve injury using femoral motor branches for tibial and deep peroneal branches but necessitated interposition grafting.^[15] Our technique bypasses the interposition grafts, eliminating multiple coaptation sites and effectively shortens the distance between the donor and recipient nerves. This may reduce the total operation time and offer an easier alternative for less advanced surgeons. Second, apart from the TN to VM coaptation in cadaver 4, the overlap values following the nerve transfers consistently displayed tensionless coaptation. Ensuring tensionless coaptation reduces local fibrosis and avoids the risk of decreased blood flow in the vasa nervorum.^[1] Ultimately, the technique should provide a more efficient pathway for the axons to grow and reinnervate target muscles.

Instead of treating a sciatic nerve injury, Chen *et al.* sought to treat a high femoral nerve injury.^[4] They completed a sciatic to femoral nerve transfer with the construction of a tunnel to pass the nerve through, similar to our method of creating a window between the anterior and posterior compartment. Their muscle tunnel was constructed lateral to the femur at the location where the rectus femoris innervates the muscle to pass the nerve branches to the posterior compartment. This required a sural nerve graft whereas our approach did not. A patient with a femoral nerve injury unable to extend his knee initially after crush injury underwent their method of nerve transfer. After 18 months, the patient

regained strength of knee extension grade 4+ and was able to walk again, demonstrating the clinical utility of this nerve transfer.^[4]

In children with acute flaccid myelitis, a sciatic-to-femoral nerve transfer was performed.^[14] The approach utilized a tunnel through the adductor muscles medial to the femur to transfer sciatic nerve fascicles to the nerve branches of the vastus intermedius and VM. No patient outcomes of the technique were available in the study, making it difficult to discern if the technique led to quadriceps motor functional recovery. To restore femoral nerve function after tumor resection, obturator, and sciatic nerve transfers were completed.^[17] Interestingly, in two cases, knee extension was regained. This method incorporated interpositional sural nerve autografts.

While the proposed technique has advantages and is anatomically viable in cadavers, some factors must be considered before clinical implementation. Even though creating a window in the adductor magnus is a minimally invasive technique, the long-term recovery implications are unknown. As the patient regains function, the sciatic nerve may be at risk for compression or have a higher chance of re-injury. However, this risk should be negligible if the surgeon constructs a large enough window for the sciatic nerve to pass through.

Coapting the TN to the VM and the PN to VL was performed at a proximal level with no way to confirm whether the transfers were made to the appropriate motor branches. However, previous literature has shown that motor neurons have a preference to regenerate toward their target muscle in a mouse model. In particular, Schwann cells from muscle branches secrete specific trophic factors that may influence this preference.^[2] This effect may be beneficial within our procedure and guide motor fascicles to the appropriate motor branch during recovery. Furthermore, autologous Schwann cell treatments have shown promising results in sciatic nerve injuries in both animal models and humans and could be further incorporated alongside our procedure.^[12,18]

In addition, a histological and morphological analysis following treatment and recovery may provide further insight for differentiating between the motor and sensory branches. Immunohistochemistry utilizing both choline acetyltransferase and calcitonin gene-related peptide markers can distinguish individual motor and sensory fascicles, respectively, to ensure appropriate fascicle realignment.^[27] To further confirm the procedure's anatomical viability, axon and fascicle counts, as well as cross-sectional areas, should be measured in the TN, PN, VM, and VL. For a successful nerve transfer, the ideal donor-to-recipient nerve axon count ratio should be $\geq 0.7:1$.^[11]

Previous nerve transfers have utilized limb flexion and osteotomy to achieve direct coaptation. In the context

of brachial plexus nerve transfers, Wang *et al.* describe a technique for repairing the median nerve in a total brachial plexus avulsion injury using the contralateral C7 nerve.^[23,24] The transfer temporarily coopts the donor nerve to a prefabricated plastic tube to guide the nerve contralaterally. Compared to previous methods, the transfer utilizes a shorter pre-spinal nerve route with direct coaptation to the lower trunk to restore finger flexion. In the event the C7 nerve does not reach the lower trunk, the authors recommend repositioning the shoulder in 0° of adduction and 0°–10° of anterior flexion, the elbow flexed 90°, and having the forearm placed on the abdomen. Once the limb is properly repositioned, a humeral shortening osteotomy <5 cm, or 12–14% of the humerus, is needed for successful coaptation while preserving strength and limb function. Some authors have used knee flexion or femoral shortening for tensionless repair of sciatic nerve. Our technique obviates the need for this since the sciatic nerve is cut so high, and plenty of length are available for a tensionless nerve transfer.

Finally, the number of cadavers used in the study is small. A greater sample size in live patients can help determine the treatment's effectiveness in improving lower limb function.

CONCLUSION

Our study demonstrates the anatomical feasibility of adjacent nerve transfer between femoral nerve branches to sciatic nerve branches to restore motor function and sensation without the need for nerve graft after sciatic nerve injury. Results and overall patient outcomes need to be validated in future case reports and clinical trials.

Acknowledgments: The authors are extremely grateful to the individuals who donated their bodies to the advancement of medicine. This article was made possible by the selfless gifts from these donors and/or their families.

Ethical approval: Institutional Review Board approval was not required because the study did not include any live human subjects.

Declaration of patient consent: Patient's consent is not required as there are no patients in this study.

Financial support and sponsorship: Nil.

Conflicts of interest: There are no conflicts of interest.

Use of artificial intelligence (AI)-assisted technology for manuscript preparation: The authors confirm that there was no use of artificial intelligence (AI)-assisted technology for assisting in the writing or editing of the manuscript and no images were manipulated using AI.

REFERENCES

1. Bahm J, Esser T, Sellhaus B, El-Kazzi W, Schuind F. Tension in peripheral nerve suture. In: Treatment of brachial plexus injuries. London, UK: IntechOpen; 2019:18-24.
2. Bolívar S, Udina E. Preferential regeneration and collateral

- dynamics of motor and sensory neurons after nerve injury in mice. *Exp Neurol* 2022;358:114227.
3. Burks SS, Levi DJ, Hayes S, Levi AD. Challenges in sciatic nerve repair: Anatomical considerations. *J Neurosurg* 2014;121:210-8.
4. Chen H, Meng D, Xie Z, Yin G, Hou C, Lin H. Transfer of sciatic nerve motor branches in high femoral nerve injury: A cadaver feasibility study and clinical case report. *Oper Neurosurg (Hagerstown)* 2020;19:E244-50.
5. Foster CH, Karsy M, Jensen MR, Guan J, Eli I, Mahan MA. Trends and cost-analysis of lower extremity nerve injury using the national inpatient sample. *Neurosurgery* 2019;85:250-6.
6. Giuffre JL, Bishop AT, Spinner RJ, Levy BA, Shin AY. Partial tibial nerve transfer to the tibialis anterior motor branch to treat peroneal nerve injury after knee trauma. *Clin Orthop Relat Res* 2012;470:779-90.
7. Griffin MF, Malahias M, Hindocha S, Khan WS. Peripheral nerve injury: Principles for repair and regeneration. *Open Orthop J* 2014;8:199-203.
8. Hsiao EC, Fox IK, Tung TH, Mackinnon SE. Motor nerve transfers to restore extrinsic median nerve function: Case report. *Hand (N Y)* 2009;4:92-7.
9. Iyer VG. Iatrogenic injury to the sciatic nerve during surgical repair of proximal hamstring avulsion. *Muscle Nerve* 2015;52:465-6.
10. Kornfeld T, Vogt PM, Radtke C. Nerve grafting for peripheral nerve injuries with extended defect sizes. *Wien Med Wochenschr* 2019;169:240-51.
11. Krasnoff C, Ferrin P, Peters BR. Donor and recipient nerve axon counts in gender-affirming radial forearm phalloplasty: Informing choice of nerve coaptations. *Plast Reconstr Surg Glob Open* 2023;11:e4971.
12. Levi AD, Burks SS, Anderson KD, Dididze M, Khan A, Dietrich WD. The use of autologous Schwann cells to supplement sciatic nerve repair with a large gap: First in human experience. *Cell Transplant* 2016;25:1395-403.
13. Liu G, Jiang R, Jin Y. Sciatic nerve injury repair: A visualized analysis of research fronts and development trends. *Neural Regen Res* 2014;9:1716-22.
14. Lubelski D, Pennington Z, Tuffaha S, Moore A, Belzberg AJ. Sciatic-to-femoral nerve end-to-end coaptation for proximal lower extremity function in patients with acute flaccid myelitis: Technical note and review of the literature. *Oper Neurosurg (Hagerstown)* 2021;21:20-6.
15. Meng D, Chen H, Lin Y, Lin H, Hou C. Transferring of femoral nerve motor branches for high-level sciatic nerve injury: A cadaver feasibility study. *Acta Neurochir (Wien)* 2019;161:279-86.
16. Moore AM, Krauss EM, Parikh RP, Franco MJ, Tung TH. Femoral nerve transfers for restoring tibial nerve function: An anatomical study and clinical correlation: A report of 2 cases. *J Neurosurg* 2018;129:1024-33.
17. O'Brien AL, West JM, Zewdu A, Grignol VP, Scharschmidt TJ, Moore AM. Nerve transfers to restore femoral nerve function following oncologic nerve resection. *J Surg Oncol* 2021;124:33-40.
18. Rodriguez FJ, Verdú E, Ceballos D, Navarro X. Nerve guides seeded with autologous schwann cells improve nerve

- regeneration. *Exp Neurol* 2000;161:571-84.
19. Sakuma M, Gorski G, Sheu S-H, Lee S, Barrett LB, Singh B, *et al.* Lack of motor recovery after prolonged denervation of the neuromuscular junction is not due to regenerative failure. *Eur J Neurosci* 2016;43:451-62.
 20. Steinau H-U, Tofaute A, Huellmann K, Goertz O, Lehnhardt M, Kammler J, *et al.* Tendon transfers for drop foot correction: Long-term results including quality of life assessment, and dynamometric and pedobarographic measurements. *Arch Orthop Trauma Surg* 2011;131:903-10.
 21. Tung TH, Mackinnon SE. Brachial plexus injuries. *Clin Plast Surg* 2003;30:269-87.
 22. Urso-Baiarda F, Grobbelaar A. Use of the interposed nerve graft to reduce differences in functional muscle transfer outcome arising from variability in motor input. *J Plast Reconstr Aesthet Surg* 2011;64:432-8.
 23. Wang S, Li PC, Xue YH, Yiu HW, Li YC, Wang HH. Contralateral C7 nerve transfer with direct coaptation to restore lower trunk function after traumatic brachial plexus avulsion. *J Bone Joint Surg* 2013;95:821-7.
 24. Wang S, Xue Y. Contralateral C7 nerve transfer with direct coaptation to restore lower trunk function after traumatic brachial plexus avulsion injuries. *JBJS Essent Surg Tech* 2014;4:e5.
 25. Wood MB. Peroneal nerve repair. Surgical results. *Clin Orthop Relat Res* 1991;267:206-10.
 26. Yin G, Chen H, Hou C, Xiao J, Lin H. Obturator nerve transfer to the branch of the tibial nerve innervating the gastrocnemius muscle for the treatment of sacral plexus nerve injury. *Neurosurgery* 2016;78:546-51.
 27. Zhou X, Du J, Qing L, Mee T, Xu X, Wang Z, *et al.* Identification of sensory and motor nerve fascicles by immunofluorescence staining after peripheral nerve injury. *J Transl Med* 2021;19:207.

How to cite this article: Trudrung M, Mickelson E, Attaluri P, George RE, Gander B, Hanna A. Femoral to sciatic nerve transfer: A cadaver study. *Surg Neurol Int.* 2025;16:73. doi: 10.25259/SNI_60_2025

Disclaimer

The views and opinions expressed in this article are those of the authors and do not necessarily reflect the official policy or position of the Journal or its management. The information contained in this article should not be considered to be medical advice; patients should consult their own physicians for advice as to their specific medical needs.